

Marine-Lenhart Syndrome: A Case Report

H Guerrouj, N Benrais

Citation

H Guerrouj, N Benrais. *Marine-Lenhart Syndrome: A Case Report*. The Internet Journal of Endocrinology. 2006 Volume 3 Number 1.

Abstract

The association of Graves's disease with toxic nodules constitutes Marine Lenhart syndrome. It is a rare pathology with prevalence between 2.7 and 4.1%. Its physiopathology remains complicated incriminating antithyroidian autoantibodies such as TSH antireceptors autoantibodies.

The treatment by the iodine 131 could be an activating factor. The thyroid scintigraphy by the iodine 123 or by the pertechnetate shows a diffuse increased uptake without suppression of the remainder of the gland and with focused raising nodular activity.

This paper presents a case report of Marine-Lenhart syndrome and a discussion of the association of Graves's disease with thyroid nodules as well as the therapeutic approach, through a review of the literature.

INTRODUCTION

Graves's disease is an autoimmune pathology. It can be suspected through the analysis of the histology, which shows the infiltration of the thyroid, by lymphocytes and plasmocytes. It can also be suspected through biological disorder, revealing thyroid-stimulating immunoglobulin (TSI). The TSH antireceptors autoantibodies -only measured in routine- play an important role in the activation of the glandular function, which leads to hyperthyroidism.

The association of thyroid nodules with Graves's disease is found in 25 % to 30 % (4, 5) of patients affected by Graves's disease. More than 95 % of these nodules are hypoactive and a small percentage is hyperactive. Therefore, these patients are candidates for thyrotoxicoses due to the Graves's disease and to the toxic nodule. These patients present Marine-Lenhart syndrome (1, 2, 3).

We present a case report of Marine-Lenhart syndrome and we discuss the physiopathology approach and the therapeutics of this syndrome through a literature review.

CLINICAL CASE

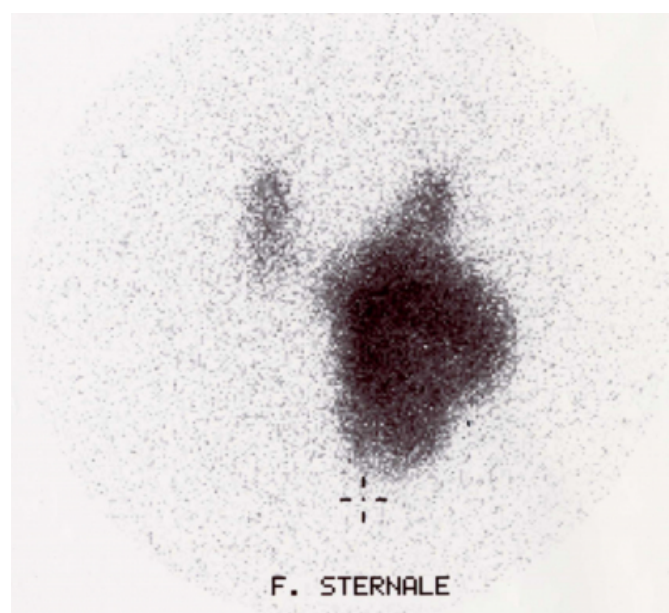
85-year-old patient was admitted in the nuclear medicine department in April 2005 for the iodine 131 therapy of a fruste hyperthyroid known for 2 years. Clinically, the patient reported asthenia, thermophobia and insomnia. The palpation of the neck found a nodule in the left thyroid lobe. Biologically, TSHus was 0.11 uUI/l, T3L, T4L were normal,

and the anti receptors of the TSH were positive. The scintigraphy by the iodine 123 (figure 1) showed a voluminous toxic nodule in the base of the left lobe without suppression of the remainder parenchyma and with an uptake at 2 hour of 7 %. The thyroid ultrasonography showed two nodules in the base of the left lobe measuring 35 and 18 mm. A radioiodine treatment (20 mCi) was delivered on April 29, 2005. The treatment by NeoMercazole was quickly stopped because of an allergy.

A clinical (thermophobia, tachycardia, diarrhea, discrete exophthalmia) and biological (TSH: 0.01; LT4: 37.9; LT3: 10.6 and TSI: 39.8) hyperthyroidism had appeared. The ultrasonography objectified a 6 centimeters subtotal left nodule. The thyroid scintigraphy showed a voluminous toxic nodule without contralateral suppression, the uptake was 17 % at 2 hours. The basdene test was stopped for allergic reason. Towards the end of August 2005, the patient was hospitalized and propylthiouracil was prescribed at the rate of eight tablets a day.

Figure 1

Figure 1: Thyroid scintigraphy by the iodine 123



DISCUSSION

The association of the thyroid nodules with the Graves's disease is present among 25 to 30 % of patients with Graves's disease. This is illustrated by studies carried out among patients operated on for Graves's disease (table 1) and among patients who were not operated (table 2).

Figure 2

Table 1 : Studies carried out among patients operated on for Graves's disease (, ,)

	Number of patients	Nodules in %
Lamata Hernandez and al.	153	28.1
Mishra and al.	130	26.9
Kraimps and al.	557	25.1

Figure 3

Table 2 : Studies carried out among patients who were not operated (, ,)

	Number of patients	Nodules in %
Carnell and al.	468	12.8
Cantalamesa and al.	315	33.7

The cold nodules represent the biggest percentage. In the study of Carnell and al. (6), among 60 patients having nodules:

- 27 patients : unique cold nodule 5.8 %
- 21 patients : several cold nodules 4.5 %
- 4 patients : hot nodules 1 %

- 8 patients: other nodules 1.7 %.

The association of Graves's disease with one or several toxic nodules is the Marine-Lenhart syndrome. It is a rare syndrome with prevalence between 2.7 and 4.1% (9, 10). It can involve toxic nodule and Graves's disease simultaneously or successively. Its physiopathology remains misunderstood. We incriminate genetic alterations of the TSH receptors and the presence of TSH antireceptors autoantibodies in the development of the Marine-Lenhart syndrome in patients affected by the Graves's disease.

The treatment by iodine 131 could be an activating factor. Waldherr (11) published a case where two toxic nodules appear 13 years after the treatment by iodine of a Graves's disease. The study of Nygaard (12) among 149 patients treated by iodine for toxic nodules, showed 17 relapses after 3-6 months, among which 12 presented positive TSH antireceptors.

The scintigraphic aspect enables the distinction between Marine-Lenhart syndrome and multi hetero nodular toxic goiter. This later one presents a nodular hyperactivity with suppression of the remainder of parenchyma. While, Marine-Lenhart syndrome presents a diffuse hyperactivity with focused raising of the nodular activity.

These nodules must be well investigated to optimize the therapeutic management. The antithyroid drugs are the treatment of the choice. The treatment by the iodine 131 is to be recommended in the second place. In the case of multiple nodules, the surgical treatment is more suitable.

CONCLUSION

The clinician and the nuclear physician must be careful in the interpretation of a thyroid scintigraphy of a Graves's disease. The resistance to high doses of antithyroidian or the recurrence after their stop has to draw the attention towards the Marine-Lenhart syndrome. The evaluation of these toxic nodules is very important for optimizing the therapeutic management.

References

1. Braga-Basaria M, Basaria S. Marine-Lenhart syndrome. *Thyroid*. 2004 Dec;14(12):1107.
2. Cakir M. Marine-Lenhart syndrome. *J Natl Med Assoc*. 2005 Jul;97(7):1036-8.
3. Cakir M. Diagnosis of Marine-Lenhart syndrome. *Thyroid*. 2004 Jul;14(7):555.
4. Kim WB, Han SM, Kim TY, Nam-Goong IS, Gong G, Lee HK, Hong SJ, Shong YK. Ultrasonographic screening for detection of thyroid cancer in patients with Graves'

- disease. Clin Endocrinol (Oxf). 2004 Jun;60(6):719-25.
5. Mishra A, Mishra SK. Thyroid nodules in Graves' disease: implications in an endemically iodine deficient area. J Postgrad Med. 2001 Oct-Dec;47(4):244-7.
6. Kraimps JL, Bouin-Pineau MH, Mathonnet M, De Calan L, Ronceray J, Visset J, Marechaud R, Barbier J. Multicentre study of thyroid nodules in patients with Graves' disease. Br J Surg. 2000 Aug;87(8):1111-3.
7. Lamata Hernandez F, Sanchez Beorlegui J, Artigas Marco MC, Gonzalez Gonzalez M, Martinez Diez M. Graves' disease with associated thyroid nodules (nodular Graves' disease), Clinical, diagnostic and therapeutic considerations. An Med Interna. 2003 Aug;20(8):403-9.
8. Cantalamessa L, Baldini M, Orsatti A, Meroni L, Amodei V, Castagnone D. Thyroid nodules in Graves' disease and the risk of thyroid carcinoma. Arch Intern Med. 1999 Aug 9-23;159(15):1705-8.
9. Carnell NE, Valente WA. Thyroid nodules in Graves' disease: classification, characterization and response to treatment. Thyroid. 1998 Aug;8(8):647-52.
10. Charkes ND. Graves' disease with functioning nodules (Marine-Lenhart syndrome). J Nucl Med. 1972 Dec;13(12):885-92.
11. Waldherr C, Otte A, Haldemann A, Muller-Brand J. Marine-Lenhart syndrome: a case observation upon 18 years. Nuklearmedizin. 1999;38(8):345-8.
12. Nygaard B, Faber J, Veje A, Hegedus L, Hansen JM. Transition of nodular toxic goiter to autoimmune hyperthyroidism triggered by 131I therapy. Thyroid. 1999 May;9(5):477-81.

Author Information

Hasnae Guerrouj

Physician Diploma, Nuclear Medicine, Nuclear Medicine, Ibn Sina Hospital

Nouzha Benrais

Nuclear Medicine Specialist Diploma, Nuclear medicine, Nuclear Medicine, Ibn Sina Hospital