

Unreamed Solid Locked Nailing In The Treatment Of Compound Diaphyseal Fractures Of The Tibia.

R Singh, T Motten, N Kalsotra, R Gupta, V Gupta, R Gupta

Citation

R Singh, T Motten, N Kalsotra, R Gupta, V Gupta, R Gupta. *Unreamed Solid Locked Nailing In The Treatment Of Compound Diaphyseal Fractures Of The Tibia.* The Internet Journal of Orthopedic Surgery. 2009 Volume 17 Number 2.

Abstract

This is a prospective study based on 30 cases of compound tibial diaphyseal fractures fulfilling our inclusion criteria and stabilised with primary unreamed solid AO tibial locked nailing with a follow up ranging from 6-18 months. 26 cases (87%) were males and 4 (13%) were females. 63% of the patients were in the age group of 21-40 years. Open fractures were classified as per Gustillo's. Road traffic accidents were responsible for most of the fractures (80%) followed by fall from height (10%). 16 cases (53.3%) were statically locked and 14 cases (46.6%) were locked dynamically. All the fractures united in an average period of 22 weeks. Evaluation of results was done after one year follow up as per criteria laid down by Johnner & Wruhs (1983). Postoperatively, there were 4 cases of superficial infection (13.3%) & 2 cases (6.6%) of deep infection. 2 cases (6.6%) had skin necrosis leading to sloughing of skin. Delayed union occurred in 8 cases (26.6%). Shortening of >1cm was noticed in one case. As per criteria laid down by Johnner & Wruhs 40% cases had excellent result, 50% good results, 10% cases fair & none had poor result. Results were evaluated and compared with various studies. On the basis of above study it was concluded that unreamed solid AO locked nailing is a good mode of primary internal fixation of compound fractures of tibia (grade I-IIIB) and has proved to be a one time procedure, which allows early weight bearing, minimises the chances of infection and delayed union.

INTRODUCTION

The tibia is the most commonly fractured long bone. The optimal method of treatment for these injuries remains debatable. In spite of all the advances, fractures of tibia still pose a challenge to the orthopaedic surgeons and thus the management of the fractured tibia requires the widest experience, the greatest wisdom, and the nicest of the clinical judgement in order to choose the most appropriate treatment for particular pattern of injury. That is why Sir John Charnley long back spoke rightly that "we have still a long way to go before the best method of treatment of fracture shaft of tibia can be stated with finality". Since the advent of intramedullary fixation it has undergone several modifications specially the advent of locking which has widened the rather limited indications of unlocked nailing. When operative fixation is indicated locked I.M. nail at present appears to be an attractive surgical option, as it is the only operative modality closest to the safe yet rewarding and time honoured conservative treatment. The intramedullary interlocking nail can be solid or hollow type and can be used either in static or dynamic mode, may be reamed or unreamed, but however the ideal technique remains a matter of controversy. Presented here is a prospective study

to identify the role of unreamed solid AO locked nailing in compound fractures (grade I-IIIB) of tibia locked in dynamic and static mode in our setup and group of patients.

MATERIALS AND METHODS

This is a prospective study based on 30 consecutive cases of compound tibial diaphyseal fractures which were studied from June 2005 to June 2007 and were stabilised primarily with solid unreamed interlocking nail and followed up for a period ranging from 12 months to 18 months with an average follow up of 15 months.

The inclusion criteria of the study were:

1. Fresh fractures.
2. Adult patients ≥ 16 years of age.
3. Compound type I, II, IIIA and IIIB as per Gustillo's classification.
4. Fractures at least 7cm from the knee and ankle joints.

The exclusion criteria were –

1. Compound type III.
2. Pathological fractures.
3. Fractures in children.
4. Patients with associated head injury, chest and abdominal trauma necessitating delay in primary and immediate fixation.

Out of the 30 patients, 18(63.3%) patients were in the age group of 21-40 years of age. 26(87%) were males and 4(13%) were females. Most of the fractures were caused by high energy trauma, 24(80%) were caused by RTA, 3(10%) by fall from height, 2(6.6%) by blow/assault and 1(3.3%) by crush injury. 16(53.3%) patients had right sided and 14(46.6%) left sided fracture. Most of the fractures were transverse (36.6%) followed by oblique (23.3%). Spiral and comminuted constituted 16.6% of the cases in our series. Segmental fractures sampled 6.6% of the cases. 20 (66.6%) fractures occurred in the middle third, 7(23.3%) in lower and 3(10%) occurred in the upper third of tibial shaft. All patients had fracture of both bone leg. Only in one case we fixed fibula with semitubular plate. As per Gustillo's classification, 15 patients were with type I injury, 11 patients type II and 2 patients in each type IIIA and type IIIB. Only 3 patients had associated injury with one case each of contralateral fracture leg, contralateral fracture femur and clavicular fracture. Most of the patients reported within 12 hrs of injury. Only one case reported 14 hrs after injury. 15 cases (50%) were operated between 12-24hrs of injury. Only 7 patients (23.3%) patients could be operated in <12 hrs after injury. 7 patients (23.3%) were operated in 24-48hrs and 1 patient (3.3%) was operated after 48hrs of injury.

The patients were operated in supine position with the bent to 90°, both legs hanging over the edge and under C-arm guidance. Nail insertion was done with AO/ASIF instrumentation set through a medial parapatellar approach and retraction of the patellar tendon. 8mm and 9mm solid AO locking nails were used with length ranging from 28-36cm. No attempt was made to insert nails greater than 9mm in diameter.

Choice of locking mode was dictated by site and fracture geometry. Out of 30 cases, 16 cases (53.3%) were statically locked and 14 cases (46.6%) locked dynamically. Static locking was done for fractures outside the middle third irrespective of the fracture geometry. Dynamic locking was preferred in stable fractures. The proximal locking screws

were placed using the insertion jig, the distal screws initially with the aiming device and subsequently with increasing experience free hand technique was used. The mean operating time was 50 minutes (range 30 to 90 minutes). Intraoperatively, there was difficulty in reducing fracture in 2 patients (6.6%), distal locking not possible in 2 patients (6.6%) and in one patient there was bending of nail during insertion. Splintering of the bone at the insertion site was observed in 1 patient (3.3%).

All cases were routinely immobilised in an above knee pop slab till active dorsiflexion of the foot was possible, usually by the second/third day. Weight bearing was dictated by the fracture pattern, size of the nail and associated injuries. 23 patients (76.6%) started partial weight bearing by the end of 3rd week, 5 patients by the end of 6th week and 2 patients by the end of 8 weeks.

Cases were followed up clinically and radiologically at 6 12 weeks post surgery, and then every 4 weeks till consolidation of the fracture and thereafter, every three months provided the patient was asymptomatic.

RESULTS

The results were made at the end of the study as per criteria laid down by Johner and Wruhs (1982). Postoperative complication are summarised in the table no 1. 15 cases (50%) were discharged within 5 days, 12 cases (40%) within 6-10 days and 3 cases (10%) after 11 days. Wounds of most of the patients healed primarily after sutures. 6 cases (20%) healed by secondary healing. 2 cases had secondary sloughing of skin which required partial thickness skin grafting. Dynamisation was done in 6 cases (20%) at an average of 14 weeks. All fractures united at an average of 22 weeks. It was observed that a total of 73.2% of the fractures united in <24 weeks out of which 23.3% united in 13-16 weeks, 26.6% united in 17-20 weeks and 23.3% of fractures united in 21-24 weeks. As per criteria laid down by Johner and Wruhs, 12 cases (40%) in our study had excellent results, 15 cases (50%) had good results, 3 cases (10%) had fair results and none of the cases had poor result.

Figure 1

TABLE 1: POST OPERATIVE COMPLICATIONS

Post operative complication	No. of Patients	Percentage
Early Superficial infection	4	13.3
Deep infection	2	6.6
Skin necrosis without infection	2	6.6
Compartment syndrome	0	0
Neurovascular injury	0	0
Delayed union	8	26.6
Shortening > 1 cm	1	3.3
Knee Range of movements:		
<10% restriction of full flexion	4	13.3
10-25% restriction of full flexion	0	0
> 25% restriction	0	0
Ankle range of movements:		
< 25% restriction of full movement	2	6.6
25-50% restriction	0	0
> 50% restriction	0	0

Secondary procedures required in our series were skin grafting and dynamisation as shown in table no 2.

Figure 2

TABLE 2: SECONDARY PROCEDURES

Secondary Procedure	No. of patients	Percentage
Skin grafting	2	6.6
Dynamisation	6	20

Fig.1. Serial X-rays of a patient with unreamed locked nail

Figure 3

(a) Pre-operative x-ray of a patient.

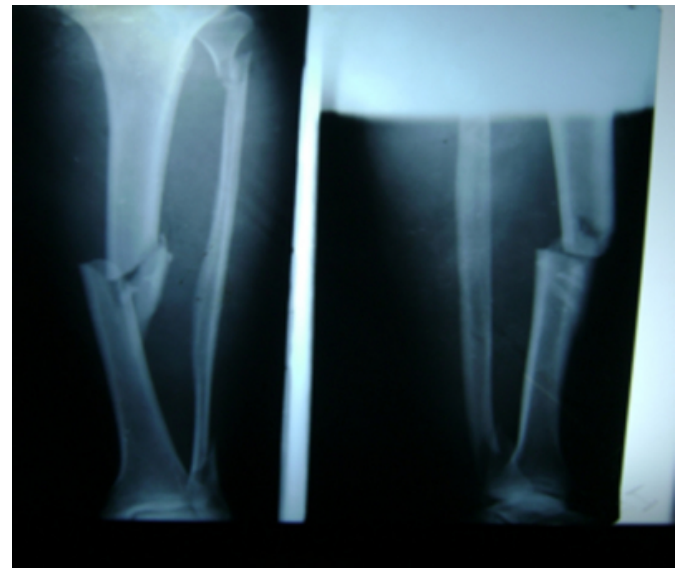


Figure 9

b) Knee Flexion and ankle dorsiflexion

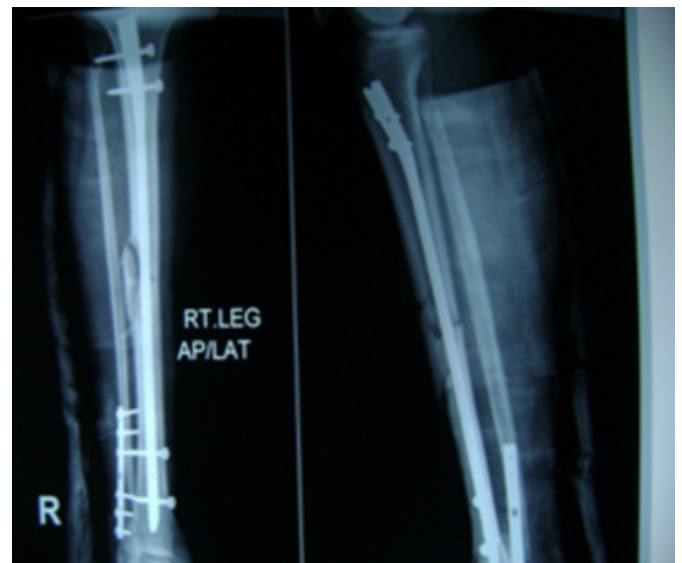


Figure 5

(c). X-ray showing callus formation

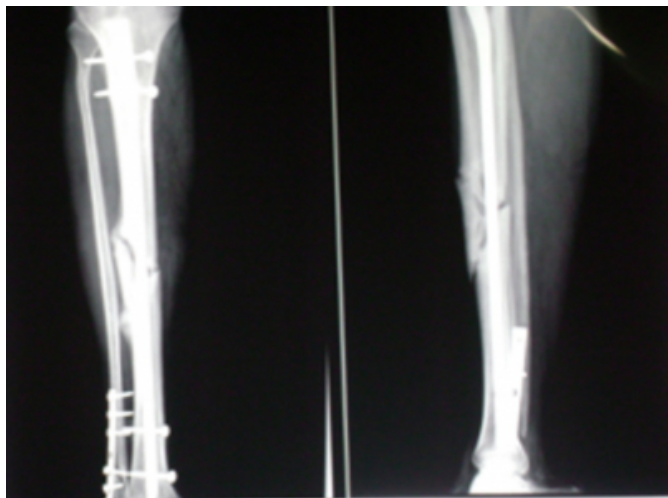


Figure 6

(d). X-ray showing union. AP View.

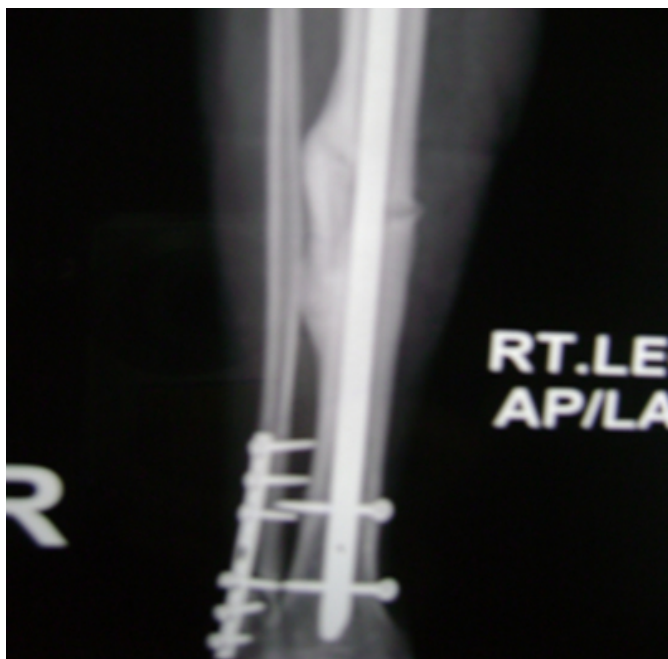

Figure 7

(e).Lateral view showing union.

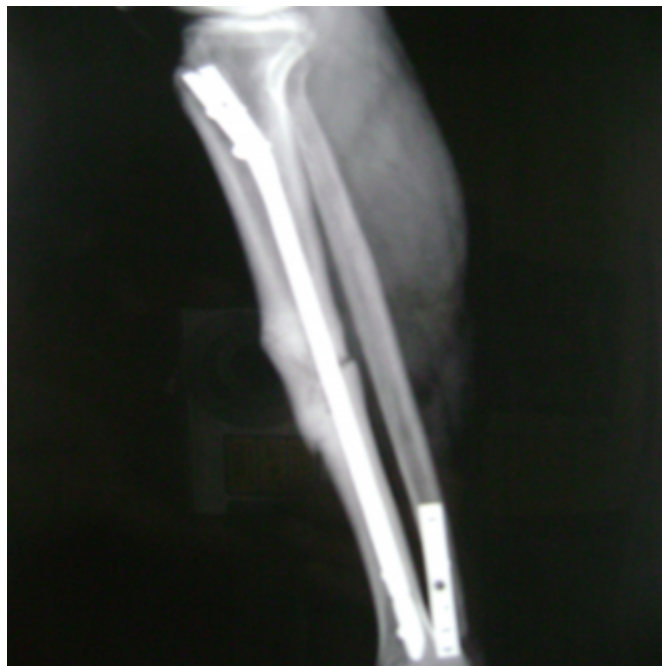
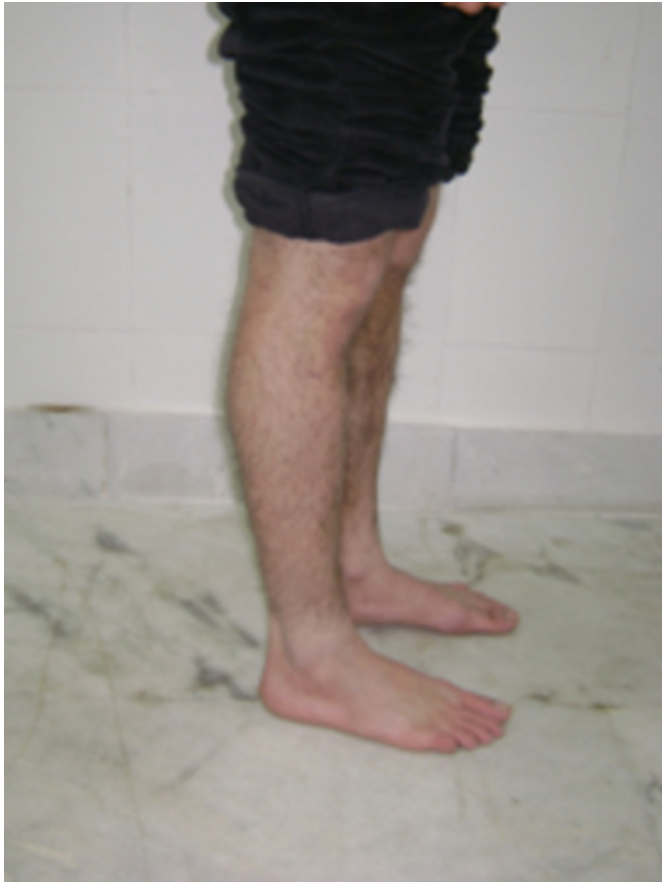
FIG 2:

Figure 8

a) Post operative photograph of same patient treated by unreamed AO locked nailing showing full knee extension



{image:9}

DISCUSSION

Locked nailing has been accepted by trauma surgeons as the best surgical option for the operative fixation of tibial shaft fractures at present however controversy still exists, whether to ream or not. Our study establishes that there is a definite role of unreamed solid locked nailing in the modern management of compound fractures of tibia as reflected by the excellent union rates within an acceptable period. Intramedullary nailing without reaming is less damaging to endosteal blood supply than nailing with reaming and historically has resulted in lower rates of infection. This is especially important in the treatment of open fractures in which outer cortical blood supply may be damaged by periosteal stripping. Reaming during nailing produces large amount of reamed bone which acts as a devitalised bone or microsequestra and carries an increased risk of infection. Reaming also leads to necrosis and increases chances of fat embolism. These adverse effects are avoided in unreamed nailing.

Most of the patients in our series were in an age group of 21-40 yrs which is the most active period of life. The incidence is consistent with other series previously reported.[1,2,3,4]. In our study 87% of patients were males and 13% were females and was consistent with most of the reported series [5,2,6,7]. This preponderance may be due to more outdoor activities of males. Road traffic accident was the commonest cause of fracture shaft of tibia as also reported by sarmiento(1974) [8], Donald and Seligson(1983) [1] and right side was more commonly involved than left side as reported by Wiss(1986)[7]. In our study, the tibial fracture was most common in middle third (66.6%) followed by distal third (23.3%) and proximal third (10%) which is consistent with those of Sedlin and Zitner (1985)[9] and Wiss(1986)[7] and inconsistent with study by Donald & seligson (1982) [1]. 6.6% of our cases required skin grafting due to sloughing of skin (Whittle 1982) [4]. Among 16 statically locked cases dynamisation was done in 6 patients (20%) at an average of 14 weeks (range 12-16 weeks) [10, 4]. 23% of our patients started partial weight bearing by the end of 3rd week. Rest of the patients were not allowed weight bearing due to the comminution of fracture and associated injuries [4].

In our study, all the fractures united in time ranging from 12 to 32 weeks with an average of 22 weeks as compared to other similar studies by Reimer et al [11] (union rate 7.6 months), Singer and Kellam [12] (union rate 6.1 months), Schandelmaier et al [13] (25.8±14 weeks), Hasse et al (6 months) and Osterman PA et al (23.5 weeks) [14].

In our series 12 cases (40%) had excellent results, 15 cases (50%) had good results and 3 cases (10%) had fair results as per criteria laid down by Johner and Wruhs (1982) [15]. and none of them had poor result. Unreamed interlocking nailing with solid nail is a good mode of primary internal fixation of compound fractures of tibia (grade I to IIIB) as it has proven to be a one time procedure and has led to union in all the cases.

CONCLUSION

On the basis of our study the authors concluded that unreamed interlocking with solid nail is a good mode of immediate internal fixation of compound fractures of tibia (grade I - IIIB) as it allows early weight bearing, minimises the chances of infection and delayed union and has led to union in almost all the cases but further studies need to be done as our sample size was smaller and most of our fractures were type II.

References

1. Donald and Davidson Seligson: Treatment of tibial shaft fractures by percutaneous Kuntscher nailing, *Clinical Orthopaedics and Related Research*. September 1983; No. 178: 7 – 24.
2. Henley M B: Non-reamed versus external fixators. Presented at Annual Meetings of orthopaedic Trauma Society Los Angeles CA, 1994.
3. Lottus J O: Medullary nailing of the tibia with the triflange nail, *Clin Orthop* 1974; 332: 37 – 51.
4. Whittle A P, Russel T A, Taylor J C et al: Treatment of the tibial shaft with the use of interlocking nailing without reaming, *J. Bone and Joint Surg* 1992; 74A: 1162-71.
5. Bone LB, Sucato D, Stegamann PM et al: Displaced isolated fractures of the tibial shaft treated with either a cast or intramedullary nailing, *J Bone Joint Surg* 1997; 79A: 1336-41.
6. Puno R M, Taynor J T, Negano et al: Critical analysis of results of treatment of 201 tibial shaft fractures, *Clin Orthop*. 1986; 212: 113-21.
7. Wiss D A: Flexible medullary nailing of acute tibial shaft fracture, *Clin Orthop* 1986; 212: 122-132.
8. Sarmiento A: A functional below the knee cast for the tibial fractures, *J Bone and Joint Surgery* 1967; 49A: 855-75
9. Sedlin E D, Zitner D T: The lottes Nail in closed treated of tibia fractures, *Clin Orthop* 1985;192:185-92.
10. Ekland A, Thorson B O, Alho A, Stronsoe K, Follers G and Hankebo: Interlocking intramedullary nailing, the treatment of the tibial fractures (a report of 45 cases), *Clin Orthop* 1988; 231:205-15
11. Reimer B L, Dichristina D G, Cooper A et al: Non-reamed nailing of tibial diaphyseal fractures in blunt polytrauma patients, *J Orthop Trauma* 1995; 9: 66-75.
12. Singer R W, Kellam J F: Open tibial diaphyseal fractures. Results of unreamed locked intramedullary nailing, *Clin Orthop* 1995; 315: 114-118.
13. Reimer B L, Dichristina D G, Cooper A et al: Non-reamed nailing of tibial diaphyseal fractures in blunt polytrauma patients, *J Orthop Trauma* 1995; 9: 66-75.
14. Schandelmaier P, Krettek C, Rulolf J et al: Outcome of tibial shaft fracture with severe soft tissue injury treated by unreamed nailing versus external fixation, *J Trauma* 1995; 39: 707-711.
15. Ostermann P A, Knopp W, Josten C, Muhr G: A comparative analysis of unreamed intramedullary nailing and external fixator in complicated tibial fractures, *Chirurg* Nov.1993;64(ii):913-7.
16. Johner R, Wruhs O: Classification of tibial shaft fractures and correlation with results after rigid fixation, *Clin Orthop* 1983;178:7-25

Author Information

Ravinder Singh, MS

Tarsem Lal Motten, MS

Senior Resident, Postgraduate Department of Orthopaedics, Government Medical College Jammu

Nipun Kalsotra, MBBS

Junior Resident, Postgraduate Department of Orthopaedics, Government Medical College Jammu

Rakesh Kumar Gupta, MS

Senior Resident, Postgraduate Department of Orthopaedics, Government Medical College Jammu

Vinit Gupta, MS

Senior Resident, Postgraduate Department of Orthopaedics, Government Medical College Jammu

Rishabh Gupta, MS

Senior Resident, Postgraduate Department of Orthopaedics, Government Medical College Jammu