

First Transfemoral Aortic Valve Implantation In Bulgaria - Crossing The Valve With The Device Is Not Always

T D, J P.

Citation

T D, J P.. *First Transfemoral Aortic Valve Implantation In Bulgaria - Crossing The Valve With The Device Is Not Always*. The Internet Journal of Cardiology. 2009 Volume 9 Number 2.

Abstract

Degenerative aortic stenosis is one of the most common valve diseases in the elder generation.(5) Age and comorbidities often lead to unacceptably high perioperative risk and a number of these patients are refused surgery and left on medical therapy with a very poor quality of life as well as life expectancy.(4,8,9) Development of an alternative method of treatment is very important for these patients(1,2,).The case we are reporting is the first case of THV in Bulgaria

INTRODUCTION

Degenerative aortic stenosis is one of the most common valve diseases in the elder generation.(5) Age and comorbidities often lead to unacceptably high perioperative risk and a number of these patients are refused surgery and left on medical therapy with a very poor quality of life as well as life expectancy.(4,8,9) Development of an alternative method of treatment is very important for these patients(1,2,).

The case we are reporting is the first case of THV in Bulgaria

CASE REPORT

A 70-year-old man presented with symptomatic severe AS, and worsening functional status NYHA class III - IV, over a six month period. Comorbidities: chronic renal failure (HRF) gr. II, anemia, severe pulmonary hypertension .

ECG showed atrial fibrillation, LBB.

Echocardiographic assessment showed severe AS with an aortic valve area 0,7 cm² and a mean pressure gradient of 70 mmHg across a heavily calcified aortic valve. The aortic annulus measured 20 mm in diameter. There was moderate mitral regurgitation (MR). Left ventricular ejection fraction (LVEF) was 24%.Cardiac catheterization showed heavily calcified aortic valve ,clear coronary and carotid arteries.(fig.1. fig 2.)

Figure 1

fig. 1. Very calcified aortic stenosis

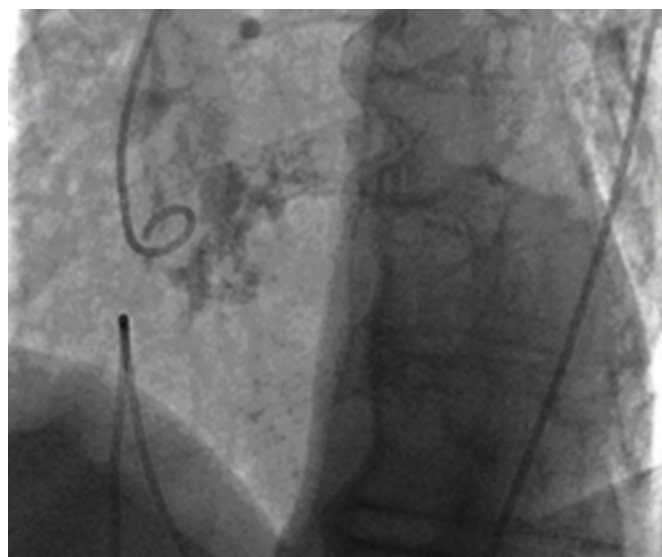
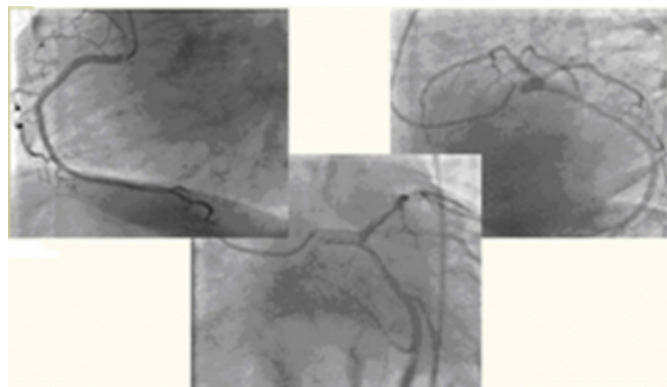


Figure 2

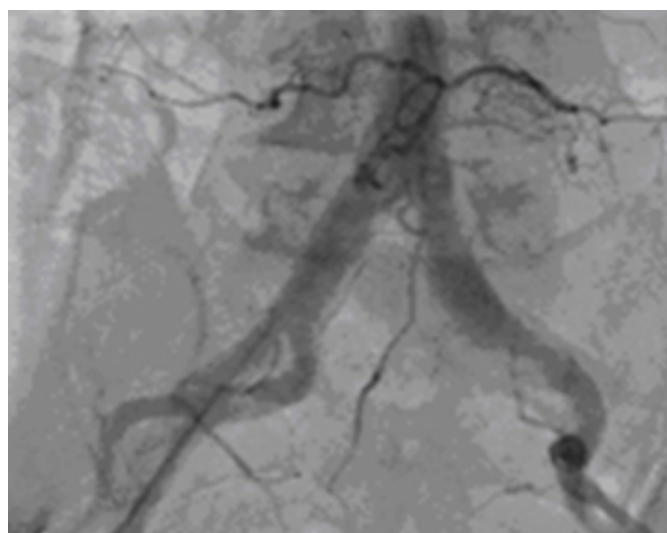
fig.2 Clear coronary arteries



Mean pressure gradient was 65 mmHg. Ileo-femoral angiogram showed patent non-tortuous iliac and femoral arteries.(fig.3.)

Figure 3

fig.3 Aorto-iliac angiogram



The logistic EuroSCORE was 27% and STS – 6,1

The novel technique of percutaneous aortic valve implantation was offered as a alternative to surgical AVR.

Informed consent was obtained from the patient and family.

The procedure was performed in the cardiac catheterization laboratory under general anaesthesia.

A cannula was placed in the right radial artery for continuous blood pressure (BP) monitoring.

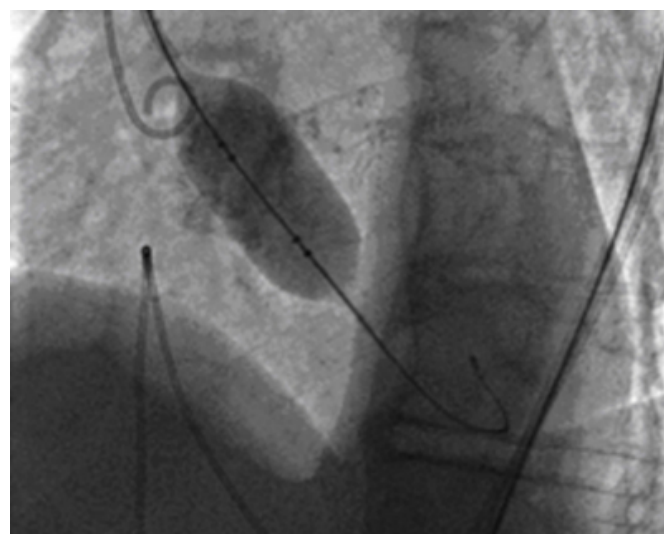
Transoesophageal echocardiography (TEE) was performed to confirm aortic annulus dimension and to provide imaging during the procedure. Left arterial and venous accesses were

obtained for the placement of a pacing wire in the right ventricular apex and pigtail catheter in the aortic root.

Surgical cut-down of the right external iliac artery was performed, and a size 14-French sheath was inserted. The valve was crossed using standard retrograde technique. A long stiff 0,035-inch wire was placed in the left ventricular apex. Balloon valvuloplasty was successfully performed with a 23mm x 30 mm balloon under rapid ventricular pacing and decrease BP under 50 mm Hg.(fig 4.).

Figure 4

fig.4. Balloon valvuloplasty aortic valve

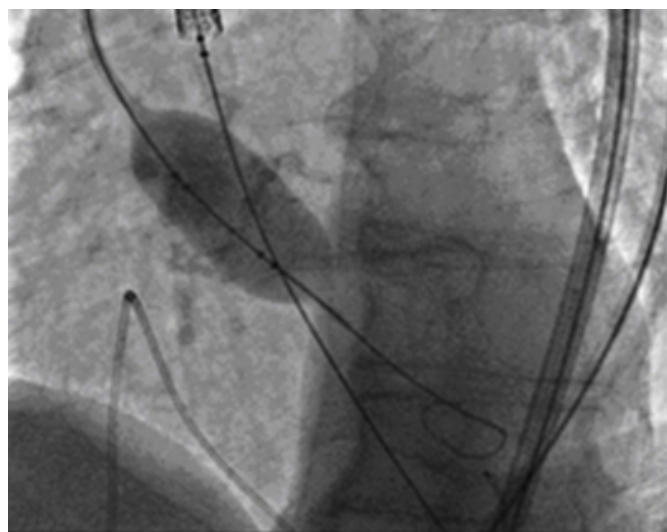


24-French sheath was inserted and 26 mm Sapien THV(Edwards Lifesciences) was then manually crimped onto 26 mm x 3 cm balloon and advanced to the aortic annulus.

Even after predilatation, crossing the aortic valve with the prosthesis turned to be impossible After several unsuccessful attempts we decided to predilate once more. Keeping the THV device in the ascending aorta we placed a 14-french sheath in the left femoral artery, passed the predilatation balloon through it and dilated the valve again(fig 5).

Figure 5

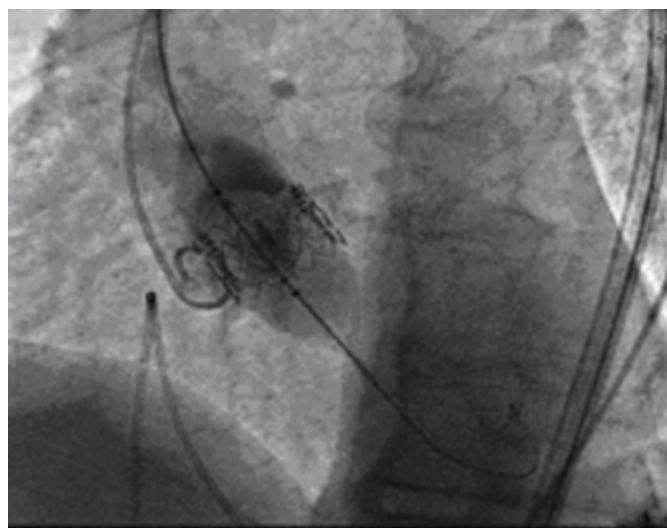
fig.5. Repeat balloon valvuloplasty aortic valve and attempt to cross the valve with the device



After another unsuccessful attempt to cross the valve with the device we decided to dilate again and simultaneously, using the moment of deflation and pulling out of the balloon trying to pass the device through the valve. This time we were successful. Optimal THV position was assessed with fluoroscopy and TEE. This THV was then deployed under rapid pacing by inflating the balloon. (fig 6).

Figure 6

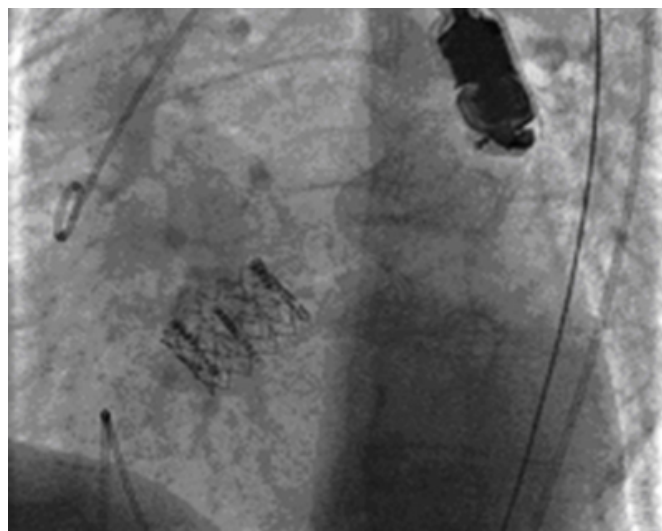
fig.6. Deployed THV



Immediately post-deployment TEE showed a stable THV position, a mean pressure gradient of 8 mmHg and trivial paravalvular leak. (fig 7) Root aortogram revealed minimal aortic regurgitation and patent coronary arteries

Figure 7

fig.7. Stable THV position – final result



The patient was extubated on-table. There is no peripheral complications. The patient was discharged and follow-up was every month by clinical examination and echocardiography. Ten months after procedure the patient was well with marked improvement in functional status to NYHA class II. Echocardiographical assessment showed a LVEF 45%, a mean pressure gradient 16 mmHg across the aortic valve, aortic regurgitation I degree and MR below II degree.

CONCLUSION

Percutaneous aortic valve implantation is emerging as an alternative to surgical AVR for selected patients with symptomatic severe AS, who are at high surgical risk or are non-operable. The technology has evolved very rapidly with satisfactory results, mainly in major institutions in Europe and USA (6,7,10.) In this first for Bulgaria case of percutaneous transfemoral aortic valve implantation a patient with severe heavily calcified AS and high surgical risk was successfully treated, with good clinical result at 10-months follow-up.

ACKNOWLEDGEMENT

The authors would like to thank Dr K Spargias, MD PhD, FESC from the Hospital Onassis Heart Centre, Athens for his technical assistance during the procedure.

References

1. Cribier A, Eltchaninov H, Bash A, et al. Early experience with percutaneous transcatheter implantation of heart valve prosthesis for the treatment of end-stage inoperable patients with calcific aortic stenosis. J Am Coll Cardiol

2004;43:698-703.

2. Cribier A, Eltchaninov H, Tron C, et al. Treatment of calcific aortic stenosis with the percutaneous heart valve: mid-term follow-up from the initial feasibility studies: the French experience. *J Am Coll Cardiol* 2006;47: 1214-1223.

3. Iung B, Baron G, Butchart EG, Delahaye F, Gohlke-Barwolf C, Levang OW, Tornos P, Vanoverschelde JL, Vermeer F, Boersma E, Ravand P, Vahanian A. A perspective survey of patients with valvular heart disease. *Eur Heart J* 2003;24:1231-1243.

4. Otto CM, Burwash IG, Legget ME, Munt BI, Fujioka M, Healy NL, Kraft CD, Miyake-Hull CJ, Schwaegler RG. Prospective study of asymptomatic valvular aortic stenosis. Clinical, echocardiographic and exercise predictors of outcome. *Circulation* 1997;95: 2262-2270.

5. Otto CM, Lind BK, Kitzman DW, Gersh BJ, Siscovik D. Association of aortic valve sclerosis with cardiovascular mortality and morbidity in the elderly. *N Engl J Med*

1999;342:142-147.

6. Paniagua D, Condado JA, Besso J et al. First human case of retrograde transcatheter implantation of an aortic valve prosthesis. *Tex Heart Inst J* 2005;32: 393-398.

7. Melby SJ, Zierer A, Kaiser YP, et al. Aortic valve replacement in octogenarians. Risk factors for early and late mortality. *Ann Thorac Surg* 2007;83:1651-1657.

8. Iung B, Baron G, Butchart EG, et al. A prospective survey of patients with valvular heart disease in Europe: the Euro Heart Survey on Valvular Heart Disease. *Eur Heart J* 2003;24: 1231-1243.

9. Karadajan P, Kapoor N, Bansat RC, Pai RG. Clinical profile and natural history of 453 nonsurgically managed patients with severe aortic stenosis. *Ann Thorac Surg* 2006;82:2111-2115.

10. Eltchaninoff H, Zajarías A, Tron C, et al. Transcatheter aortic valve implantation: technical aspects, results and indications. *Arch Cardiovasc Dis* 2008;101:126-32.

Author Information

Trendafilova D

University Hospital “ St.Ekaterina”

Jorgova J.Simeonov P.

University Hospital “ St.Ekaterina”