

Castleman's Disease In Childhood

G Yildirim, G Berkiten, K Turkoz

Citation

G Yildirim, G Berkiten, K Turkoz. *Castleman's Disease In Childhood*. The Internet Journal of Otorhinolaryngology. 2008 Volume 10 Number 2.

Abstract

A cervical lymphadenopathy in children is considered generally as a non specific infection. But sometimes, it may be a specific infection, a malignancy or a disease of lymphoid system. Delayed diagnosis may lead to some serious results. For this reason, when there is a child with a cervical lymphadenopathy without any infection, a lot of experimental studies must be realised for the diagnosis. Castleman's disease is a giant lymph node hyperplasia. The disease is rare in children, and neck is a very uncommon site for paediatric cases. In our case there was a painless cervical mass. After all investigations there was not any diagnosis. And after the surgery the postoperative histopathology was a Castleman's disease.

INTRODUCTION

Castleman's disease (giant lymph node hyperplasia, lymphnodal hamartoma) represents a unique type of lymph node hyperplasia first described by Castleman and colleagues in 1956 (1). The disease has an unsettled complexity and morbidity and has two distinct clinical expressions. Multicentric/systemic form presents mainly with generalized lymphadenopathy and/or splenomegaly. This clinical form usually affects young adults (2). The solitary form presents as a mass located most commonly in the mediastinum but also described in the lung, axilla, mesentery, soft tissues, nasopharynx and neck (3,4).

The disease is very rare in children, and neck is a very uncommon site for involvement for pediatric cases (5,6).

CASE REPORT

A ten year old girl was referred with an isolated, mobile, sharp bordered, firm and painless mass. The lesion was located in the left lateral part of the neck and estimated to measure 5 cm in the largest dimension.

Patient's inquiry revealed that the mass had appeared 5 months before the presentation time. Laboratory data revealed that the patient's hemoglobin was 13,5 g/dl., ESR was 4 mm/h, peripheral leucocyte count was 7100 per cubic millimeter, of which % 60 were neutrophils, %30 lymphocytes, %8 were monocytes and %3 were eosinophils. Total platelet account was 200000/ml. CRP was not higher than 0,5 mg/dl. Gammaglobulins were within the normal limits. Tests for tuberculosis, atypical mycobacteriae,

brucellosis, toxoplasmosis, epstein barr virus, cytomegalovirus and HIV were all negative. Whole body scanning by CT showed a dense and highly vascularised mass in the left lateral side of the neck and the other body sides were normal.

The mass was excised totally and send to the department of pathology. In routine haematoxyline and eosin slides, large follicles which showed marked vascular proliferation and hyalinization of their abnormal germinal centers were seen scattered in lymphoid tissue (Fig. I). There was a concentric layering of the lymphocytes at the periphery of the follicles (Fig. II). In hyalin centers, large cells with a vesicular nuclei were seen. These cells were evidenced as follicular dendritic cells by their immunoreactivity for CD 21 and CD35. Follicular areas were stained positive by B cell markers and interfollicular areas were positive for T cell markers. Lymph node showed positivity for both kappa and lambda chains. The diagnosis was "Castleman's disease, hyaline vascular type".

Figure 1

Figure 1: Haematoxyline eosine x 200. Large follicles showing marked vascular proliferation and hyalinization in their germinal center.

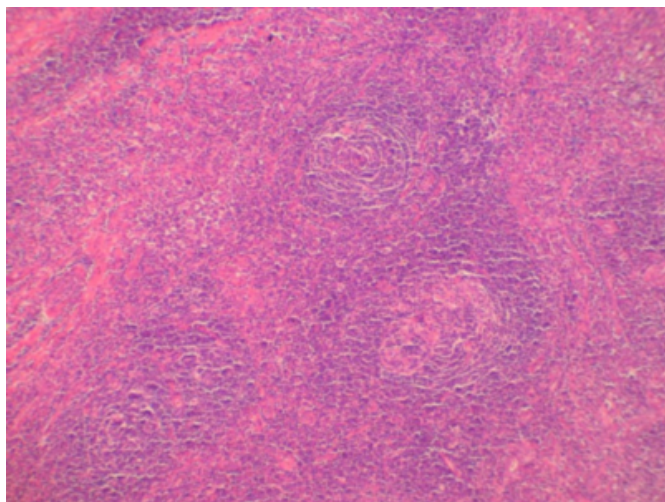
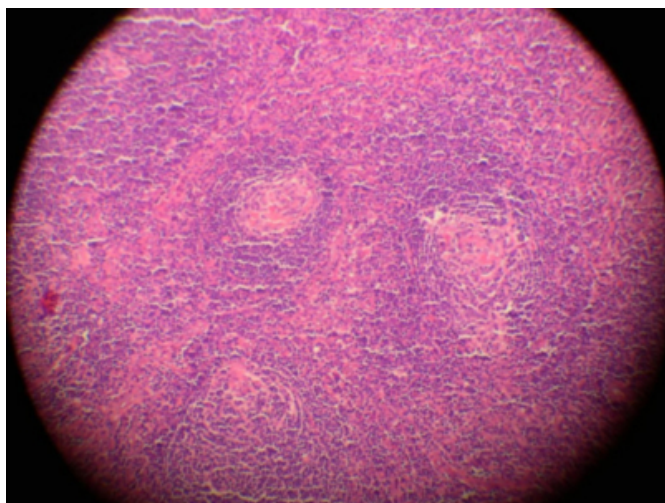


Figure 2

Figure 2: Haematoxyline eosine x 400. There is a tight concentric layering of lymphocytes at the periphery of the follicles (mantle zone area) giving an onion skin appearance



DISCUSSION

Castleman's disease is a unique type of lymphoproliferative disease. Its etiology is controversial and knowledge about morbidity is not settled yet. The disease has usually been reported in adults but in children the disease is rare. (6,7,8,9,10).

From the point of localization, neck is one of the rarest regions to be involved. The neck was the site of involvement only in a few children who were reported in the review of the literature by Salisbury (5,7). Grossly, lesion can be as large as 15 cm in diameter. Similar microscopic changes suggesting an early stage of the same process are

sometimes seen in the adjacent lymph nodes (3).

Approximately 90 % of the solitary cases are hyaline vascular subtype and remainders are plasma cell type. Hyaline vascular subtype usually doesn't present with any systemic symptom. Symptoms like fever and weight loss; abnormal laboratory results like elevated ESR and CRP, microcytic anaemia, which consists approximately 10 % of the solitary clinical form (3). Castleman's disease of plasma cell type can be associated with polyneuropathy, organomegaly, endocrinopathy, M-protein, skin changes and anasarca. The acronym "POEMS" is used to name this syndrome (11). The rare occurrence of Castleman's disease, especially multicentric forms in younger ages suggests a hypothesis that environmental events play an important role in etiology of Castleman's disease and paediatric forms present an earlier form of the process (7). The diagnosis is possible only through a surgical biopsy and excision of the node with the surrounding lymph nodes is satisfactory for the cure in localized cases as in our case. All the symptoms are expected to disappear after a successful removal of the involved node. But, recurrences have been reported in adults (12). Due to her relatively poor prognosis and severity of the disease, Castleman's disease of mixed type may be treated with combination chemotherapy consisting of cyclophosphamide, vincristine, doxorubicin, and prednisone (13). Although the clinical expression of the disease in adults is well described, further investigations are needed to clarify the pathophysiology of Castleman's disease, especially in children.

References

1. Castleman B, Iverson L, Menendez VP, Localised mediastinal lymph node hyperplasia resembling thymoma, *Cancer* 1956; Jul-Aug;9(4):822-30
2. Frizzera G, Peterson BA, Bayrd ED, Goldman A. A systemic lymphoproliferative disorder with morphologic features of Castleman's disease: clinical findings and clinicopathologic correlations in 15 patients. *J Clin Oncol*. 1985 Sep;3(9):1202-16
3. Rosai J Lymph nodes in Ackerman's surgical pathology, eight edition, vol,2 chap 21, Mosby, St Louis. 1996;1661-1773
4. Park JH, Lee SW, Koh YW. Zhang KR, Jia HM Castleman disease of the parotid gland in childhood: an unusual entity *Auris Nasus Larynx*. 2008 Sep;35(3):451-4. Epub 2007 Nov 8.
5. Salisbury JR. Castleman's disease in childhood and adolescence: report of a case and review of the literature. *Pediatr Pathol*. 1990; 10(4):609-15
6. Buesing K, Perry D, Reyes C, Abdessalam S. Castleman disease: surgical cure in pediatric patients. *J Pediatr Surg*. 2009 Jan;44(1):e5-8
7. Perez N, Bader-Meunier B, Roy CC, Dommergues JP. Pediatric Castleman disease: report of seven cases, review of the literature. *Eur J Pediatr*. 1999 Aug;158(8):631-7
8. Gidvani VK, Tyree MM, Bhowmick SK. Castleman's

disease: atypical manifestation in an 11-year old girl. South Med J. Feb;94(2):250-3

9. Zhong LP, Chen GF, Zhao SF, Cervical Castleman disease in children. BR J Oral Maxillofac Surg. 2004 Feb ; 42 (1) : 69-71

10. Samadi DS, Hockstein NG, Tom LW. Pediatric intraparotid Castleman's disease. Ann Otol Rhinol Laryngol. 2003 Sep; 112 (9 Pt 1) : 813-6

11. Kurotaki H, Kaimori M, Nagai K: Recurred Castleman's

disease containing a fibrohistiocytic nodular lesion with vascular occlusion. Acta Pathol Jpn. 1993 Oct;43(10):603-7.

12. Adelman HM, Cacciatore MI, Pascual JF, Mike JM, Alberts WM, Wallach PM: Case report: Castleman disease in association with POEMS. Am J Med Sci 1994 Feb;307(2):112-4

13. Baserga M, Rosin M, Schoen M, Young G Multifocal Castleman disease in pediatrics: case report J Pediatr Hematol Oncol. 2005 Dec;27(12):666-9

Author Information

Guven Yildirim, MD

Department of Otorhinolaryngology - Head and Neck Surgery, Okmeydanı Research and Education Hospital

Guler Berkiten, MD

Department of Otorhinolaryngology - Head and Neck Surgery, Okmeydanı Research and Education Hospital

Kemal Turkoz, MD

Department of Pathology, Okmeydanı Research and Education Hospital