

# A Radiographic Study Of Scaphoid Movement In A Conventional Short Arm Cast

A Nabavi, G Konidaris, R Chin, R Breit

## Citation

A Nabavi, G Konidaris, R Chin, R Breit. *A Radiographic Study Of Scaphoid Movement In A Conventional Short Arm Cast*. The Internet Journal of Orthopedic Surgery. 2005 Volume 3 Number 2.

## Abstract

It has been long debated whether inclusion of the thumb in a cast is necessary for scaphoid immobilization. This study aims to evaluate scaphoid movement in a conventional short arm cast with the thumb held in different positions using four standard radiographs. Four subjects (group A - control) were placed in short arm casts and radiographs taken with the thumb in a neutral position. Ten subjects (group B) were placed in short arm casts and radiographs taken with the thumb in abduction, adduction, flexion, and extension. The maximum amount of movement of the scaphoid between each thumb position was recorded for both groups. The mean maximum movement was compared using a student t-test. A mean maximum scaphoid movement of 1.06mm (sd 0.826) in group A and 2.35mm (sd 0.53) in group B. This was statistically significant with a p-value <0.002 using a student t-test. There have been numerous studies comparing short arm casts and short arm thumb spica casts. To date, there is no evidence supporting the inclusion of the thumb metacarpophalangeal joint in scaphoid fractures and subsequent non-union. Within its limits, this paper has shown that with exclusion of the thumb, there is significant scaphoid movement.

## INTRODUCTION

There have been numerous studies conducted on scaphoid fractures. There is debate on the best method treatment including long arm thumb spicas, short arm thumb spicas, conventional short arm casts or bandaging. There is no consensus on materials used for immobilisation, the position of the wrist in cast, duration in cast, or degree of displacement in the decision to proceed with surgery.

There is postulation that micromotion of the scaphoid occurs with thumb movement and therefore, the thumb must be immobilised to minimise the risk of scaphoid non-union. But the carpus is a structure of intercalating, interlocking bones. Movement of a single carpal bone should be accompanied by movement of the entire carpus. By immobilising the carpus in a short arm cast, we seek to prevent scaphoid movement. Morbidity from stiffness of the first carpometacarpal joint can be prevented and freedom of thumb movement allows for overall greater hand function.

To date, there is no study on scaphoid movement in a conventional short arm cast with different thumb positions.

## METHODS

After obtaining ethics committee approval and informed consent, 14 healthy individual subjects aged between 18 and

34 were enrolled into the study. Four subjects were allocated to the control group (Group A) and 10 to the experimental group (Group B).

All subjects had moulded conventional short arm fibreglass casts with the wrist in neutral.

Four radiographs were obtained from subjects in group B with the thumb in maximal abduction, extension, flexion and neutral. Four radiographs were taken in an identical manner from subjects in group A with the thumb in resting position and without movement between the radiographs.

The radiographs were performed by a senior radiographer onto a standard x-ray plate. The pronated forearm was resting on a foam bed with the same distance from the x-ray plate for all subjects.

An outline of the carpal bones and wrist were obtained from all radiographs using a sharp lead pencil and tracing paper. The tracings of the distal ends of the radius and ulna for each individual were identical between radiographs. This was used as a reference point for comparisons.

The maximum distance between the tracings of the scaphoid in the four radiographs of each individual was recorded. All measurements were done using a precision ruler to the

nearest 0.25mm. This was thought to be the maximum quantative measure of Scaphoid movement. The mean figure for each group was calculated and the means analysed for statistical difference using the standard student t-test.

## RESULTS

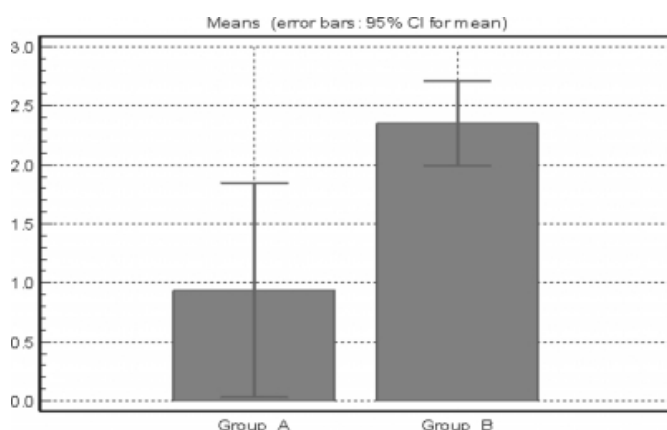
Maximal scaphoid movement in Group A and B are shown in table 1. The average movement is  $1.06 \pm 0.826$  (95% CI 0.5773 – 1.548) for Group A and  $2.35 \pm 0.530$  (95% CI 2.043 – 2.657) for Group B. This was statistically significant with a one-tailed p value of 0.0021.

**Figure 1**

Table 1: Maximum scaphoid movement between radiographs in a short arm cast

Group A (control)	Maximum movement (mm)
Control 1	0.5
Control 2	0.25
Control 3	1.5
Control 4	2.0
Average	1.06
Group B	
Subject 1	2.75
Subject 2	3.25
Subject 3	1.75
Subject 4	2.50
Subject 5	2.00
Subject 6	2.75
Subject 7	2.25
Subject 8	1.75
Subject 9	2.75
Subject 10	1.75
Average	2.35 (p-value 0.0021)

**Figure 2**



## DISCUSSION

Historically the management of scaphoid fractures has ranged from early mobilisation to the widely accepted “scaphoid plaster” which is the norm today. How this has evolved is unclear as there has been no good evidence why the inclusion of the thumb up to the interphalangeal joint in cast can affect union rates in scaphoid fractures.

The most important factor for union is early diagnosis and treatment. Between 1940 and 1990, numerous papers have advocated the inclusion of the thumb in cast for minimally displaced scaphoid fractures to provide stability and achieve union. Although inclusion of the thumb in the cast has not been shown to interfere with everyday activities, it is more inconvenient and less comfortable. This is particularly important as duration of immobilisation ranges from 8 to 12 weeks.

Gellman (1989) advocated a long arm thumb spica for 6 weeks followed by short arm thumb spica until union. By eliminating forearm rotation, this would give greater stability and higher union rates. This is supported recently by a biomechanical study by Kaneshiro (1999) and a cadaveric study by McAdams (2003).

Clay (1991) conducted a randomised prospective trial of 392 scaphoid fractures managed in “scaphoid” versus “colles” casts and concluded that there were no difference in non-union rates (10%). However the paucity of patients included in the trial may predispose it to a type B statistical error.

The scaphoid is a mobile carpal bone. It bridges both the proximal and distal carpal rows. Movement of the wrist in ulnar and radial deviation act to dorsiflex and palmar flex the proximal carpal row respectively. Similarly, the scaphoid dorsiflexes in wrist extension and palmar flexes in wrist flexion. By eliminating wrist movement, scaphoid mobility is diminished.

Furthermore, the scaphoid is held to the proximal and distal carpal rows by strong and complex volar and dorsal ligaments. It does not move independent of the other carpal bones, hence it is intercalated and interlocked. The majority of thumb movement is produced at the first carpometacarpal and metacarpophalangeal joints.

However, in our study movement of the thumb caused movement of the scaphoid. The amount of movement was significant when compared to the thumb in the neutral position, the position in which the thumb would be immobilised in cast.

## CONCLUSION

Within the limitations of this study, moving the thumb alone is enough to significantly displace a normal scaphoid in a short arm cast. Further studies are needed to firstly, evaluate the movement of a fractured scaphoid in a short arm cast, secondly, to assess the influence on union rates of non-

displaced scaphoid fractures and thirdly, to compare union rates between different types of casts.

## **CORRESPONDENCE TO**

Arash Nabavi, Level 1 Liverpool Day Surgery 105-119  
Longstaff Avenue Chipping Norton 2170 Sydney, Australia.  
Tel.: 0011 61 2 1300 1 JOINTs (56468) or 0011 61 2 0410  
535 608 e-mail: nabaviarash@optusnet.com.au

## **References**

1. Clay NR, Dias JJ, Costigan PS, Gregg PJ, Barton NJ. Need the thumb be immobilised in scaphoid fractures? *J Bone Joint Surg (Br)* 1991; 73-B : 828-32.
2. Kaneshiro SA, Failla JM, Tashman S. Scaphoid fracture displacement with forearm rotation in a short-arm thumb spica cast. *J Hand Surg* 1999; 24-A : 984-91.
3. Burge P. Closed cast treatment of scaphoid fractures. *Hand Clin* 2001; 17 (4) : 541-52.
4. Kulkarni RW, Wollstein R, Tayar R, Citron N. Patterns of healing of scaphoid fractures : the importance of vascularity. *J Bone Joint Surg (Br)* 1999; 81-B : 85-90.
5. King RJ, Mackenney RP, Elnur S. Suggested method for closed treatment of fractures of the carpal scaphoid : hypothesis supported by dissection and clinical practice. *J Royal Soc Med* 1982; 75 : 860-7.
6. Hambidge JE, Desai VV, Schranz PJ, Compson JP, Davis TRC, Barton NJ. Acute fractures of the scaphoid. *J Bone Joint Surg (Br)* 1999; 81-B : 91-2.
7. Gellman H, Caputo RJ, Carter V, Aboulaflia A, McKay M. Comparison of short and long thumb-spica casts for non-displaced fractures of the carpal scaphoid. *J Bone Joint Surg (Am)* 1989; 71-A : 354-7.
8. McAdams TR, Spisak S, Beaulieu CF, Ladd AL. The effect of pronation and supination on the minimally displaced scaphoid fracture. *Clin Orthop* 2003; 411 : 255-9.
9. Hambidge JE, Desai VV, Schranz PJ, Compson JP, Davis TR, Barton NJ. Acute fractures of the scaphoid. Treatment by cast immobilisation with the wrist in flexion or extension? *J Bone Joint Surg Br.* 1999 Jan; 81(1) : 91-2.
10. Marshall PD, Dibble AK, Walters TH, Lewis D. When should a synthetic casting material be used in preference to plaster-of-Paris? A cost analysis and guidance for casting departments. *Injury.* 1992; 23(8) : 542-4.
11. Terkelsen CJ, Jepsen JM. Treatment of scaphoid fractures with a removable cast. *Acta Orthop Scand.* 1988 Aug; 59(4) : 452-3.
12. Sjolín SU, Andersen JC. Clinical fracture of the carpal scaphoid--supportive bandage or plaster cast immobilization? *J Hand Surg [Br].* 1988 Feb; 13(1) : 75-6.
13. Cooney WP, Dobyns JH, Linscheid RL. Fractures of the scaphoid: a rational approach to management. *Clin Orthop.* 1980 Jun; (149) : 90-7.
14. Alho A, Kankaanpää. Management of fractured scaphoid bone. A prospective study of 100 fractures. *Acta Orthop Scand.* 1975 Nov; 46(5) : 737-43.

**Author Information**

**Arash Nabavi, MBBS, F.R.A.C.S., F.A.Orth.A**

Orthopaedic surgeon, Department of Orthopaedics, Fairfield/ Liverpool/Campbelltown Hospitals

**George Konidaris, MBBS**

Registrar, Department of Orthopaedics, Liverpool Hospital

**Raymond Chin, MBBS**

Registrar, Department of Orthopaedics, Sutherland Hospital

**Robert Breit, MBBS, F.R.A.C.S., F.A.Orth.A**

Orthopaedic Surgeon, Department of Orthopaedics, Concord Hospital