

# Management of oesophageal dilatation due to a paraoesophageal hernia presenting with stridor.

I Panagiotopoulou, T Jani, M Brockbank, R Frost, C Ranaboldo, S Dennis

## Citation

I Panagiotopoulou, T Jani, M Brockbank, R Frost, C Ranaboldo, S Dennis. *Management of oesophageal dilatation due to a paraoesophageal hernia presenting with stridor.* The Internet Journal of Otorhinolaryngology. 2009 Volume 11 Number 2.

## Abstract

**Objectives:** To show the importance of considering a mechanical and potentially treatable cause, such as a paraoesophageal hernia, in the differential diagnosis of stridor. Such cases can be referred to the upper GI multi-disciplinary team meeting for appropriate surgical input. **Case report:** We report the case of a 79-year-old man with Parkinson's disease presenting with intermittent stridor secondary to oesophageal dilatation from a paraoesophageal hernia. A computerised tomography (CT) scan of his thorax provided the diagnosis. The patient was referred to the upper GI multi-disciplinary team meeting and underwent a laparoscopic reduction and repair of the paraoesophageal hernia that resolved his symptoms. **Conclusion:** A paraoesophageal hernia can be a rare cause of stridor. Since surgical treatment is now available, we suggest that a referral to the upper GI multi-disciplinary team is important once prompt diagnosis has been made.

## INTRODUCTION

Stridor secondary to oesophageal disease is rare but has been reported previously<sup>1-6</sup>. Oesophageal dilatation leading to tracheal compression may be due to mechanical, neurological or idiopathic motility causes. Oesophageal dilatation due to a paraoesophageal hernia and gastric volvulus has been reported as an acute cause of stridor requiring emergency surgery<sup>1</sup>. Mega-oesophagus may also result as a complication of the autonomic dysfunction seen in Parkinson's disease. In addition, achalasia is an idiopathic primary oesophageal motility disorder characterised by aperistalsis and lower oesophageal sphincter dysfunction. Achalasia leading to progressive intermittent stridor or stridor with acute cardiorespiratory compromise is rare but well documented<sup>2-6, 7</sup>.

We report the case of a 79-year-old man with Parkinson's disease presenting with intermittent stridor secondary to oesophageal dilatation caused by a paraoesophageal hernia. The prompt diagnosis of a mechanical cause for a mega-oesophagus causing stridor is important, as surgical treatment is now available.

## CASE REPORT

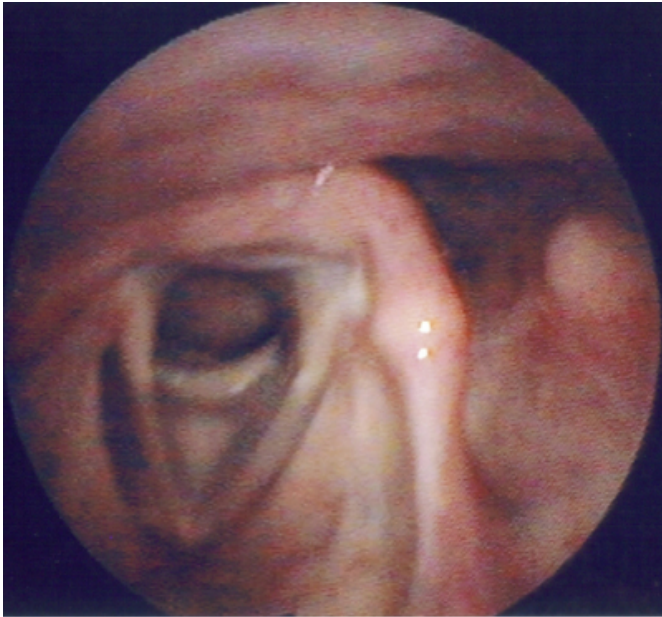
A 79-year-old man with Parkinson's disease presented with a seven-month history of worsening intermittent stridor, shortness of breath and dysphagia. Weight loss of 7lbs was noted despite a good appetite over this period. There was no

history of foreign body ingestion. Other significant past history included hypertension and transitional cell carcinoma of the bladder treated previously.

Physical examination revealed intermittent biphasic stridor with no respiratory or cardiovascular compromise. He also had kyphosis and dyskinesia consistent with Parkinson's disease. Flexible nasopharyngoscopy, whilst the patient was symptomatic, showed extrinsic tracheal compression (Figure 1) and good movement of the vocal cords.

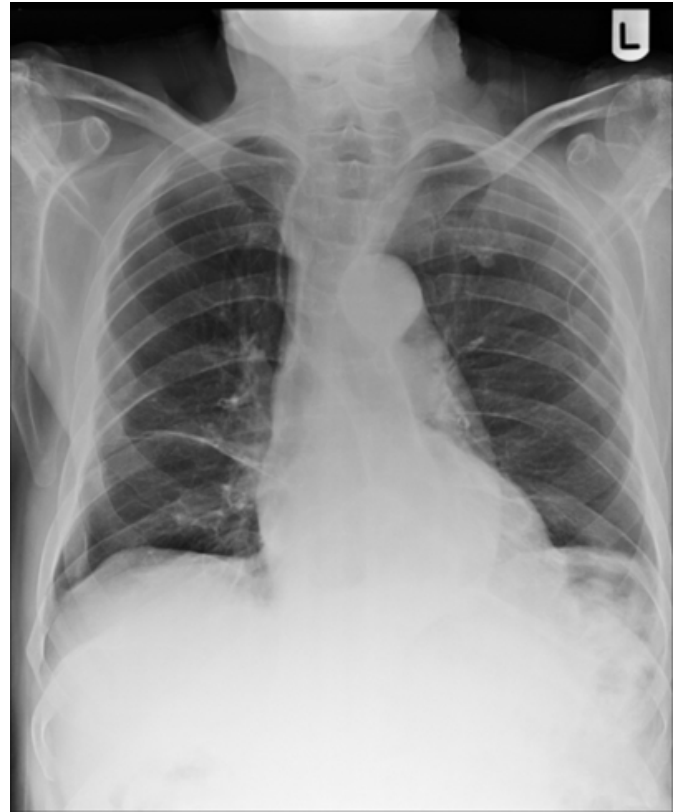
**Figure 1**

Figure 1: Flexible nasopharyngoscopy: Extrinsic tracheal compression from dilated oesophagus.



**Figure 2**

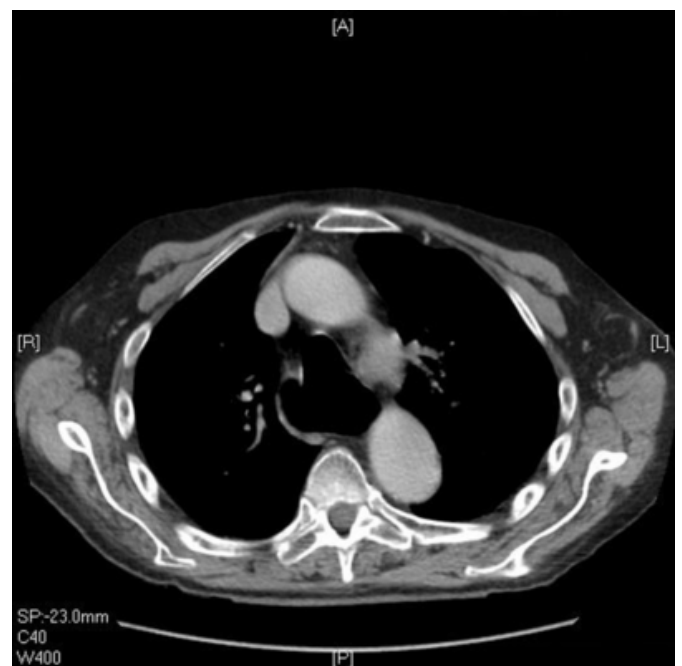Figure 2: Chest X-ray: Oesophageal dilatation seen on plain chest X-ray



Lateral soft tissue neck X-ray and chest X-ray (Figure 2) showed prominent gaseous distension of the pharynx and larynx, dilatation of the oesophagus and no active lung lesion. CT scan of the neck and chest with contrast (Figure 3) showed a markedly dilated oesophagus from the upper thoracic trachea down to a paraoesophageal hernia. The carina was displaced anteriorly by the dilated oesophagus but not significantly compressed. The stomach was not dilated. Gastrograffin swallow examination showed dilatation of the oesophagus mainly due to a moderate sized irreducible hiatus hernia and no evidence of achalasia. Oesophago-gastro-duodenoscopy (OGD) showed an 8cm paraoesophageal hernia and no malignancy.

**Figure 3**

Figure 3: Computerised tomography (CT) of thorax: Dilated oesophagus compressing the trachea



Whilst in hospital, the patient continued to eat and drink as

tolerated. We could not elicit an association between eating and the onset of stridor. He had a nasogastric tube inserted during an episode of stridor overnight. This only led to partial and temporary relief of his symptoms. Nebulised adrenaline provided no relief either.

In view of the investigations, the case was referred for review in the upper GI multidisciplinary team meeting and after discussion with the patient and the family a decision to proceed to laparoscopic repair of the paraoesophageal hernia was made. A laparoscopic reduction and repair of the paraoesophageal hernia was performed successfully. The patient was admitted to the High Dependency Unit post-operatively. He had no further stridor and was discharged home on the 6<sup>th</sup> post-operative day.

Six weeks following the operation, the patient had remained symptom free. A follow-up video swallow study showed no achalasia but severe oesophageal dysmotility as seen with long-standing acid reflux.

## DISCUSSION

This case demonstrates that surgical treatment is available for stridor that is caused by a dilated oesophagus secondary to a mechanical cause, such as a paraoesophageal hernia. In our patient, the paraoesophageal hernia was causing oesophageal dilatation that, in turn, would compress the patient's trachea leading to intermittent stridor. This is supported by the patient's follow-up video swallow study, which showed oesophageal dysmotility due to long-standing acid reflux rather than achalasia or an atonic oesophagus secondary to his Parkinson's disease.

In the emergency setting of a patient presenting with stridor secondary to a dilated oesophagus, the insertion of a nasogastric tube has been documented as lifesaving when dilatation of the oesophagus is either secondary to achalasia<sup>2,7</sup> or due to a diaphragmatic hernia<sup>8</sup>. In our patient, the passage of a nasogastric tube only partially and temporarily relieved his symptoms. Apart from the use of nasogastric tube in the acute setting, Davis et al (1992) had suggested that patients presenting with stridor due to achalasia should either undergo surgery, such as Heller's cardiomyotomy, or if unfit for the procedure the patient should be taught how to pass a nasogastric tube to relieve recurrent symptoms<sup>2</sup>.

In our patient, the ultimate treatment for his stridor was

provided once the diagnosis was made both with diagnostic imaging and after referral to the upper GI multi-disciplinary team meeting. A chest x-ray on admission has been the first diagnostic form of imaging in most reported cases of stridor secondary to a dilated oesophagus<sup>1-4,6,7</sup>. A computed tomography (CT) scan may be employed to investigate for potential causes for the tracheal compression causing stridor and in our case it revealed the presence of the para-oesophageal hernia. A contrast swallow can be useful in discerning the cause of oesophageal dilatation i.e. due to achalasia or a mechanical obstructive cause. Based on the investigations above the management of our patient was discussed in the upper GI multi-disciplinary team meeting where the diagnosis of a mechanical and surgically treatable cause for the patient's stridor was made.

To our knowledge, this is the second reported case of an elderly patient presenting with stridor secondary to oesophageal dilatation from a paraoesophageal hernia who has undergone laparoscopic hernia reduction and repair<sup>1</sup>.

In conclusion, it is important to consider oesophageal dilatation when dealing with patients admitted with stridor. Oesophageal dilatation may be due a potentially surgically treatable cause such as a paraoesophageal hernia. Referral of such patients to the upper GI multidisciplinary team is important in establishing the correct diagnosis and offering surgical treatment.

## References

1. Reardon DJ, Freschini A, Harrison M, Coulson C, Nangalia LL. Oesophageal dilatation due to a paraoesophageal hernia and gastric volvulus as a cause of stridor. *Emerg Med J* 2007; 24: 734.
2. Davis JP, Hyde JAJ. Management of acute dilatation of the oesophagus presenting as stridor. *J Laryngol Otol* 1992; 106: 744-745.
3. Tasker AD. Achalasia: An Unusual Cause of Stridor. *Clin Radiol* 1995; 50: 496- 498.
4. Turkot S, Goltzman B, Kogan J, Valid EB, Lebovici O, Oren S. Acute Upper-Airway Obstruction in a Patient With Achalasia. *Ann Emerg Med* 1997; 29: 687-689.
5. Wechalekar MD, Southcott AM. Achalasia cardia presenting as stridor. *Respirology* 2008; 13: 1088-1090.
6. Ho V, Whiting P. Acute airway obstruction secondary to achalasia mega-oesophagus. *Anaesth Intensive Care* 2008; 36: 582-584.
7. MacLachlan J, Giridharan W, Brittenden J, Woodhead CJ. Previously treated oesophageal achalasia re-presenting with stridor. *J Laryngol Otol* 2005; 119: 237- 238.
8. Berkman N, Simon Z, Almog Y, Kramer MR. Acute Gastric Dilatation Causing Respiratory Failure and "Tension Pneumothorax" in an Elderly Woman With a Diaphragmatic Hernia. *Chest* 1993; 104: 317- 318.

**Author Information**

**Ioanna G. Panagiotopoulou, BSc, MSc, BM, MRCS**

Department of General Surgery Salisbury Foundation NHS Trust

**Tushar Jani, AFRCSI**

Ear, Nose and Throat Department Salisbury Foundation NHS Trust

**Michael Brockbank, FRCS**

Ear, Nose and Throat Department Salisbury Foundation NHS Trust

**Roger A. Frost, FRCR**

Department of Radiology Salisbury Foundation NHS Trust

**Charles Ranaboldo, FRCS**

Department of General Surgery Salisbury Foundation NHS Trust

**Simon C. Dennis, FRCS**

Ear, Nose and Throat Department Salisbury Foundation NHS Trust