

Digoxin Toxicity in an Adolescent Female: Case Report

M Shadel

Citation

M Shadel. *Digoxin Toxicity in an Adolescent Female: Case Report*. The Internet Journal of Emergency Medicine. 2009 Volume 6 Number 2.

Abstract

ObjectiveTo present a case report of an adolescent who attempted to overdose on expired Digoxin tablets. **Methods**Chart review of presentation, physical exam, labs and treatment. **Results**Digoxin level obtained at three and one-half hours (3½) post-ingestion clearly in a toxic level. Treated with Fab antidote with normalization of digoxin level. Electrolyte abnormalities including hyperkalemia documented, and cardiac dysrhythmia with bradycardia observed and treated. **Conclusion**Toxic symptomatic presentation of an adolescent female using a two-year expired medication. Did the length of expiration contribute to the initially elevated blood digoxin level? Should the patient have received a higher dose treatment of Fab than what was given?

INTRODUCTION

This case illustrates the presentation and treatment of an overdose of digoxin in an adolescent female using digibind. A review of the pharmacology of digoxin is presented as well as its pathophysiology. This case is unusual due to an expired cardiac glycoside medication used as an overdose attempt by an impulsive adolescent female.

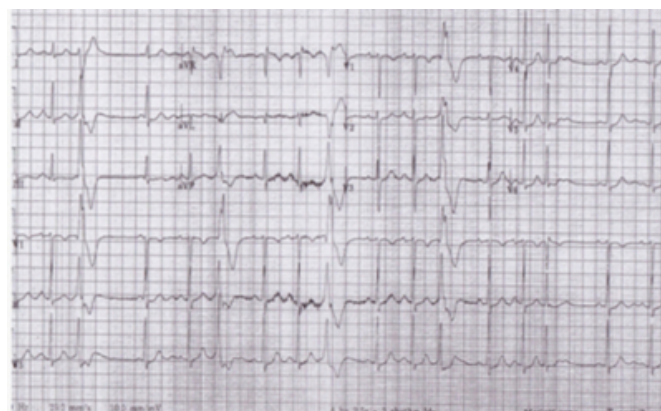
CASE REPORT

A 15 year old black female presented to the emergency department (ED) having been driven in by her mother. The patient states she was upset with her mother after arguing and in an effort to “calm herself down” she ingested 5 of her grandfather’s digoxin 0.25mg pills (total dose of 1.20mg) which had been filled on 11/25/2006 and were currently expired. She began to vomit at 7:30 pm and then told her mother of the intentional drug overdose.

Upon arrival to the ED, the patient was placed on a cardiac monitor, vitals were obtained, as well as an Electrocardiograph (EKG). Initial vitals were: blood pressure (BP) 150/86, Pulse 76, R20, Pox 99% room air (RA), Temperature 32°C oral, weight 62kg, height 70 inches. EKG shows a normal sinus rhythm with rate 98, PR interval 160 ms, with frequent premature ventricular contractions (PVC’s),

Figure 1

(figure 1)



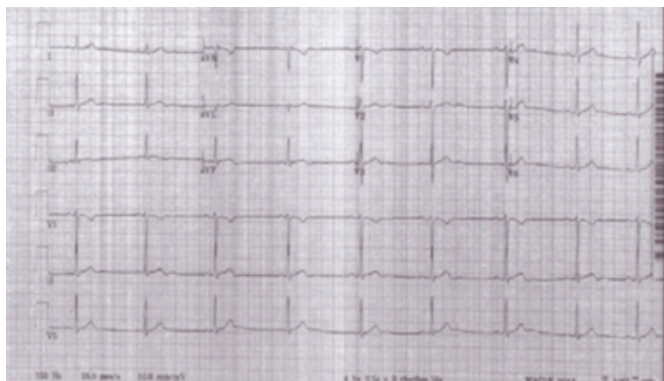Serial vital signs are shown in table 1. Physical exam revealed a healthy appearing black female adolescent in no apparent distress although tearful. Head, eyes, ears, nose and throat exam unremarkable, lungs clear to auscultation, heart sinus rhythm at a rate 76 -100 on monitor but no murmur noted, abdominal exam non-tender with normal bowel sounds, skin warm and dry, no diaphoresis with pink nail beds. The neurologic exam was normal other than depressed tearful mood.

Poison control was notified at 2032 with recommendation of potassium replacement if necessary and charcoal administration. The patient received an IV of 0.9% normal saline (NS) at a rate of keep vein open (KVO), and 60 grams charcoal orally at 2040. She promptly vomited the charcoal. An i-stat point of care testing done at 2050 showed Potassium (k) 2.9 mmol/L (range 3.5 -5.0 mmol/L) and

ionized calcium less than (<) 0.25mmol/L (range 1.13 -1.32 mmol/L). Urine pregnancy test was negative. 60 MEq of oral potassium was subsequently given along with 4 milligram IV Zofran for nausea. Full chemistry labs, complete blood count (CBC), digoxin level, and urine for toxicology were drawn at 2030, results however were unable to be reviewed until 2215 due to technical difficulties. Abnormal labs were as follows: urine opiates positive (non-qualitative); serum ethanol less than 10mg/dl (range 0-80); CBC normal; normal bilirubin total and direct, ALT and AST; serum calcium 9.8 mg/dl (range 8.4 – 10.5) as a follow-up on the abnormal i-stat calcium; Digoxin 10.0 ng/ml (range 0.8-2.0 ng/ml). After receiving oral potassium, a repeat potassium level at 22:50 was 5.3 mmol/L and a repeat i-stat potassium 5.4 mmol/L at 2300. Repeat EKG obtained at 2250 now showed abnormal sinus bradycardia, rate 52, with PR interval 162ms.

Figure 2

(figure 2)



Based on the elevated digoxin level, the decision was made to give digibind. The patient received 6 of 40 mg vials, total dose 240 mg, in 100 cc of NS infused over 30 minutes. During this time arrangements were made to transfer the patient to a pediatric facility for inpatient care. She was transferred by ACLS ambulance at 0100 in stable condition. Serial potassium and calcium levels monitored subsequently at the pediatric facility remained in the normal levels.

Figure 3

Table I: Vital Signs. Time frame*						
Time	BP	P	RR	Po ₂ RA	Temp (°C)	Rhythm
2004						EKG: NSR, PVC's
2007	150/86	76	20	99%	32 °	SR (Sinus Rhythm)
2050	155/93	100	19	97%		SR
2115	147/87	74	18	96%		SB (Sinus Brady)
2240	141/74	53	18	99%	36.6 °	SB
2250		52				EKG: SB,,
2315**	141/82	54- 50***	16	98%		SB/PVC's
2330	134/71	51	17	98%		SB
2345	138/67	59	16	98%		SB
0005	141/58	54	16	96%		SB
0020	136/58	48	16	98%		SB
0035	135/69	47	18	98%		SB
0050	126/64	52	18	98%		SB
0100	139/57	47	18	100%	32°	SB

*Time of ingestion 1700 **Time of digoxin treatment

***with short pauses

PATHOPHYSIOLOGY

Digoxin is the most widely used cardiac glycoside in the U.S. It was the most widely prescribed drug in the U.S. in the 1980's (1,2). Digoxin has a narrow therapeutic window but a large volume of distribution (1,3, 4), both of which contribute to its toxicity levels.

The tissue binding of digoxin and Na-K-ATPase activity is inversely correlated to age, with very young children (excluding neonates) demonstrating increased Na-K-ATPase activity (4). This may reflect the fact that acute toxicity is more dose dependent in children since children appear to tolerate higher serum concentration of digitalis glycerides (1,2,4). The half- life elimination is also inversely proportional to age, with premature having the longest half-life (4) and adolescents, beginning at ages 13-17 years, reaching expected adult rates for digoxin clearance. Approximately 25% of digoxin is protein bound in the plasma, compared to almost 90% of digitoxin. Thus the former is less lipid soluble with less absorption in the gastrointestinal track and in the renal tubules.

Digoxin acts by inhibiting the active transport of the Na and K ions across cell membranes by reversibly binding to a specific site on the NaK ATPase membrane, i.e. the sodium pump. This leads to an increase in the intracellular concentrations of sodium and calcium with a decrease in the intracellular potassium concentration thereby producing serum hyperkalemia. This increase in serum potassium can

be life threatening in acute cases of digoxin toxicity.

As noted above, younger children differ in their tolerance and reaction to digoxin. Adolescents tend to follow more adult reactions as discussed by Thomas G Wells et al (4). Cardiac symptoms in the younger age group show bradycardias, Atrioventricular (AV) blocks and increased PR intervals as the more common toxicity changes, especially in the acute setting. Adults will exhibit more ventricular ectopy including atrial fibrillation. However, the most common AV conduction disorders associated with digoxin toxicity in adults and older children include first-degree AV block mobility type I (Wenckebach), second-degree AV block, and AV junctional exit block. (4). These arrhythmias result from the slowing of conduction velocity and increased ectopic activity or both as discussed by Aloris R Hastrieter et al in his review article Digitalis Toxicity in Infants and Children (2).

Other non-cardiac symptoms related to digoxin toxicity include gastrointestinal, central neurological, and visual. Infants and younger children tend not to show any symptoms until the level of digoxin toxicity has reached 4ng/mL or they may become very drowsy initially. 75% of adults and older children will exhibit nausea and vomiting as earliest sign of acute digoxin toxicity with visual changes generally seen in chronic digoxin toxicity. Electrolyte changes, most commonly hyperkalemia, will be seen early in acute toxicity and must be treated appropriately and quickly while continuing to monitor during the overall treatment of digoxin toxicity. Serum potassium and plasma digoxin concentration levels have been noted to be good prognostic markers of acute massive digoxin overdoses (2,5).

TREATMENT

The use of digoxin-specific Fab antibody was first used in 1976 in adults (6). In 1982 the first use of fab fragments in the pediatric population was reported by Zecker et al (6). Digoxin was noted to be used as early as 1785, according to Witherings first account reported by Goldring, in Pediatrics 1973 (4).

In determining when to treat a digoxin overdose with fab, the time between ingestion of the drug and the time that the digoxin level is drawn is very important. If drawn less than 4-6 hours after the initial ingestion, the digoxin level may not be the actual time level but instead reflects the timing of the drug distribution. Lewander et al (1986) in his retrospective study of pediatric digoxin ingestion looked at serum half-lives of digoxin. Two phases were noted: 1) an

initial phase, referred to as primarily distribution, which reflects levels drawn less than 6 hours after ingestion and 2) a second phase, referred to as primarily elimination, that were applicable to levels drawn after 6 hours of ingestion. (7). Serum levels drawn before 6 hours may therefore not represent accurate toxicity levels, suggesting that repeat levels be obtained after this initial time frame.

In general, a review of several articles suggests that levels greater than or equal to (\geq) 4 mg of digoxin can be life-threatening in healthy young children. However Woolf et al suggests that a more accurate dosing of toxicity should be calculated as 0.3 mg of digoxin per kg of body weight. Furthermore, he states that “adolescents, perhaps more similar to adults in their cardiac sensitivity to digoxin, may become symptomatic at even lower doses” (8). In addition to the initial evaluation of the serum digoxin level, electrolytes and EKG for cardiac arrhythmias must be evaluated and treated. Patients should be placed on a continuous cardiac monitor with oxygen, IV support, and GI cathartic treatment using charcoal can be given in an awake alert patient.

DISCUSSION

Our patient was initially placed on oxygen, given an IV of NS, and labs were drawn as noted previously. Her digoxin level, drawn approximately 3½ hours after ingestion, was clearly in the toxic range of 10.0 ng/ml (0.8 -2.0 ng/ml reference range). Since this is in the primarily distribution time frame, an additional level at greater than 6 hours may have been beneficial. However our patient was clearly exhibiting signs and symptoms of toxicity, having already vomited pre-hospital, with a bradycardiac rhythm and abnormal EKG by the time results was known. Based on this alleged amount of medication taken, the total amount of digoxin consumed was 1.25 mg. However, these were expired medication from November 2006. One wonders if that fact might not have further contributed to the toxic state. If one calculates our patient’s total body load (TBL) using formula $TBL = \text{dose ingested in mg} \times 0.6$, where 0.6 represents the amount corrected for oral bioavailability of the digoxin preparation ingested, her $TBL = 0.75\text{mg}$. The number of vials of FAb needed then would be $TBL(\text{mg})/0.6\text{mg/vial}$ which in our patient would be 1.25 vials, or 50 mg of Fab. If however, one uses the serum digoxin level obtained prior to 6-8 hours post-ingestion, then TBL can be calculated as $\text{digoxin level} \times (5-7.5) \times \text{weight in Kg}$, where the 5-7.5 range represents volume of distribution as discussed in the table II of Wells, et al article: Age-related Differences in Digoxin Toxicity and its

Treatment (4). In this example our patient's TBL would be 3100 mg, which when divided by the factor 0.6 mg/vial would give us a Fab dose of 517 mg, or 13 vials. Our patient actually received 6 vials, or 240 mg of Fab. Remembering that each vial, or 40 mg, will eliminate 0.6 mg of digoxin, our patient received only one-half of the required amount if one bases the dose on a digoxin level obtained at 3½ hours after digestion. Or, if one uses the initial calculation, she may have truly been underdosed. A recommendation by Woolf is to use empiric dosing of 10-20 vials in acute toxicity for adults, and 5-20 vials for pediatric acute ingestion. As an adolescent our patient empirically could have been treated either way. Note also is the fact that the patient tested positive for opiates, although she denies drug abuse.

It is clear that following her digoxin treatment, her second potassium normalized and remained normal over the next several days until her discharge, and that her cardiac status reverted to a normal sinus rhythm without any further arrhythmias.

SUMMARY

In conclusion I have presented an adolescent case of an acute digoxin toxicity who exhibited abnormalities in cardiac rhythm and electrolytes. She was subsequently treated with

Fab based on a 3½ hour with ingestion digoxin level.

Several limitations are raised in this case, namely the timing of treatment based on a single digoxin level, and whether the expiration date of the digoxin contributed to a higher earlier level. Since Fab immediately reverses digoxin toxicity, a repeat digoxin level after administration of the antidote would be of limited value for evaluation of further treatment.

References

1. Kwon Kt. Toxicity, Digitalis. @medicine.medscape.com, updated November 6, 2008.
2. Hastreiter AR, Vander Horst RL, Chow-Tung E. Digitalis Toxicity in Infants and Children. *Pediatric Cardiology* 1984; 5: 131-148.
3. Hoffman BF, Bigger, Jr JT. In Goodman and Gilman eds *The Pharmacological Basis of Therapeutics*, 6th ed. New York MacMillan Publishing Co, Inc; 1980: 729-760.
4. Wells TG, Young RL, Kearns GL. Age-Related Differences in Digoxin Toxicity and its Treatment. *Drug Safety* 1992; 7(2): 135-151.
5. Husby Petal. Immediate Control of Life-Threatening Digoxin Intoxication in a child by use of Digoxin-specific Antibody Fragments (Fab). Case Report. *Pediatric Anesthesia* 2003; (13): 541-546.
6. Fazio A. Fab Fragments in the Treatment of Digoxin Overdose: Pediatric Considerations. *Southern Medical Journal*, December 1987; 80(12): 1553-1556.
7. Lewander WJ et al. Acute Pediatric Digoxin Ingestion A Ten-Year Experience. *AJDC* August 1986; 140:770-773.
8. Woolf AD, et al. The use of Digoxin-Specific Fab Fragments for Severe Digitalis Intoxication in Children. *NEJM* June 1992; 326 (26):1739-1744

Author Information

Martha J. Shadel, D.O.

Emergency Staff Physician, St John Macomb Hospital