

Raccoon eyes during general anaesthesia for joint replacement

S Gangoo, A Mahajan

Citation

S Gangoo, A Mahajan. *Raccoon eyes during general anaesthesia for joint replacement*. The Internet Journal of Anesthesiology. 2008 Volume 22 Number 1.

Abstract

INTRODUCTION

Raccoon eyes are described as bilateral peri orbital accumulation of blood producing "Panda bear-like appearance". It is often seen with basilar fractures of the skull.

Periorbital purpura due to skin infiltration is seen in primary amyloidosis either as a spontaneous event, or after prolonged eye-strain. It is not reported following general anaesthesia for Total joint replacement surgery .

CASE REPORT

A 76 years old lady with history of well controlled hypertension underwent elective right Total Knee Replacement(PFC, Johnson and Johnson, NJ). Anaesthetic induction was initiated with propofol and tracheal intubation was facilitated with succinylcholine. Before tracheal intubation, her eyes were gently closed and taped with latex-free transparent tape. Anaesthesia was maintained with isoflurane. Her surgery lasted 80 minutes and intraoperative anaesthesia was uneventful.

24 hours after surgery she developed B/L asymmetrical periorbital ecchymosis Surgical wound remained dry and patient was asymptomatic.

Underlying coagulopathy was considered, but subsequent coagulation studies were within normal limits: platelet count was $214 \times 10^9/L$, PT was 12.1 s, INR was 1.1, and aPTT was 35 s. The periorbital ecchymosis slowly faded over the next few days and the patient had an uneventful recovery.

Figure 1

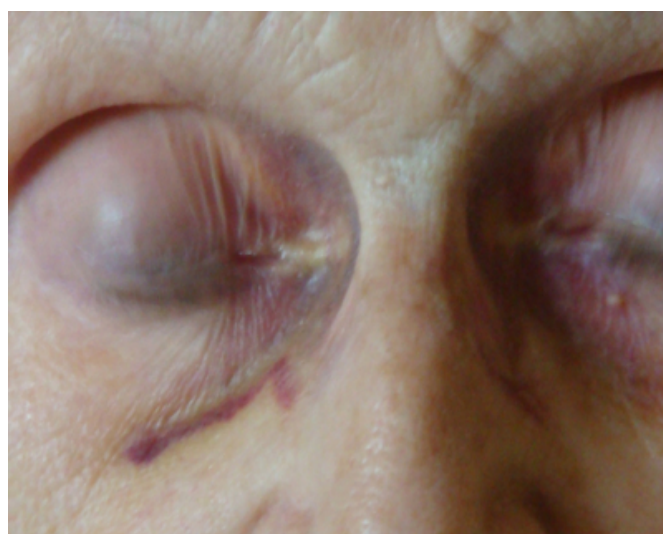
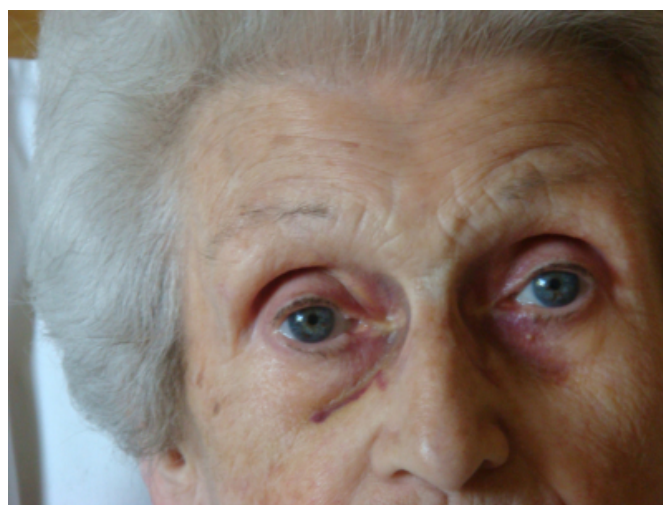


Figure 2



4 days postoperative.

DISCUSSION

“Raccoon eyes” or bilateral periorbital ecchymoses can result from direct trauma to the eye and surrounding soft tissues,¹ basal skull fracture,² rhinoplasty,³ amyloidosis,^{4,5} malignancy,⁶⁻⁸ trigeminal autonomic cephalgia,⁹ and vigorous sneezing¹⁰, coughing¹¹ and vomiting. This patient’s periorbital ecchymoses was most likely caused by the protective eye tape during anaesthesia. This was probably related to increased capillary fragility in an elderly patient with history of easy bruisability.

To our knowledge there is no reported case of raccoon eyes during general anaesthesia for joint replacement. Care needs to be exercised while putting and peeling of tap tape on the eyes especially in elderly population.

References

1. Ghazi-Nouri SM, Vote BJ, Sullivan PM. Periorbital ecchymosis as a sign of perforating injury of the globe. *Clin Experiment Ophthalmol*. 2005;33:194-196.
2. Odebo TO, Ademola-Popoola DS, Ojo TA, Ayanniyi AA. Ocular and visual complications of head injury. *Eye*. 2005;19:561-566.
3. Li Y, Xu G. Complications of nasal endoscopic surgery [in Chinese]. *Zhonghua Er Bi Yan Hou Ke Za Zhi*. 1998;33:142-145.
4. Bernardini FP. Periocular and orbital amyloidosis. *Ophthalmology*. 2007;114:1232.
5. Value of periorbital ecchymosis in the diagnosis of amyloidosis [in French]. *Presse Med*. 1991;20:658.
6. Dober I, Stranzinger E, Kellenberger CJ, Huisman TA. Periorbital ecchymosis—trauma or tumor? [in German]. *Praxis (Bern 1994)*. 2007;96:811-814.
7. Ahmed S, Goel S, Khandwala M, et al. Neuroblastoma with orbital metastasis: ophthalmic presentation and role of ophthalmologists. *Eye*. 2006;20:466-470.
8. Schwartz RA, Spicer MS, Thomas I, et al. Ecchymotic Kaposi’s sarcoma. *Cutis*. 1995;56:104-106.
9. Attanasio A, D’Amico D, Frediani F, et al. Trigeminal autonomic cephalgia with periorbital ecchymosis, ocular hemorrhage, hypertension and behavioral alterations. *Pain*. 2000;88:109-112.
10. Maramattom BV. Raccoon eyes following vigorous sneezing. *Neurocrit Care*. 2006;4:151-152.
11. Chuang YY, Chiu CH, Wong KS, et al. Severe adenovirus infection in children. *J Microbiol Immunol Infect*. 2003;36:37-40.
12. Hassan AA, Kroll MH. Acquired disorders of platelet function. *Hematology Am Soc Hematol Educ Program*. 2005:403-408.
13. Escolar G, Díaz-Ricart M, Cases A. Uremic platelet dysfunction: past and present. *Curr Hematol Rep*. 2005;4:359-367.

Author Information

S. Gangoo

Registrar, Weston General Hospital. Weston super mare, UK

A. Mahajan

Weston General Hospital. Weston super mare, UK