

Octreotide Acetate Uptake In Tuberous Sclerosis Complex With Lymphangioleiomyomatosis

D Upadhyay, T Corbridge

Citation

D Upadhyay, T Corbridge. *Octreotide Acetate Uptake In Tuberous Sclerosis Complex With Lymphangioleiomyomatosis*. The Internet Journal of Nuclear Medicine. 2001 Volume 1 Number 1.

Abstract

Lymphangioleiomyomatosis (LAM) is a rare progressive lung disease of reproductive age women. It occurs as an isolated disorder (sporadic LAM) or in an association with tuberous sclerosis complex (TSC). Coexisting renal angiomyolipomas occur in TSC and LAM, and there is an association between TSC and neuroendocrine tumors. Commonly used therapies aimed at decreasing endogenous estrogen in LAM have not been verified by randomized trial.

CASE REPORT

An octreoScan was performed to detect tumors/tissue containing somatostatin receptors (such as neuroendocrine tumors) in a 29 year-old woman with TSC, end-stage renal disease secondary to angiomyolipomas (figure 1), LAM lung (figure 2), and "potato-like" cerebral lesions. Whole body images were obtained 24 hours post IV injection of In-111 pentatreotide 5.5 mCi demonstrating increased uptake of the radio pharmaceutical diffusely in the lung and kidney (figure 3).

Figure 1

Figure 1: Triphasic Computerized Tomogram of kidneys showing multiple renal angiomyolipomas, a pseudoaneurysm (pointed by an arrow) and multiple renal cysts.

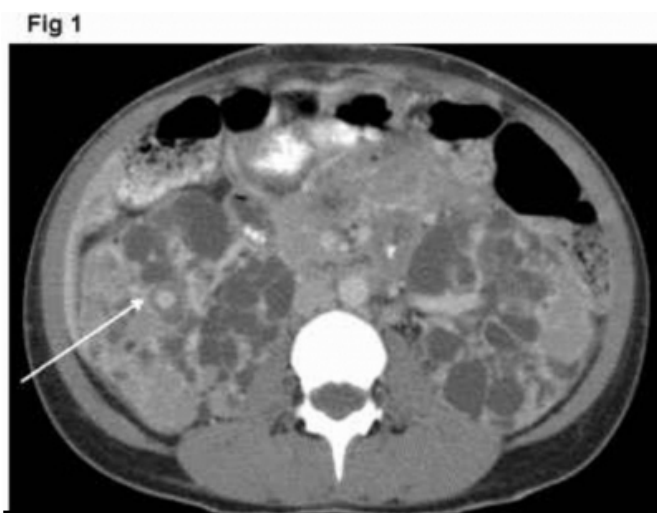


Figure 2

Figure 2: Computerized Tomogram of chest showing

bilateral, multiple thin walled cysts suggesting of LAM lung.

Fig 2

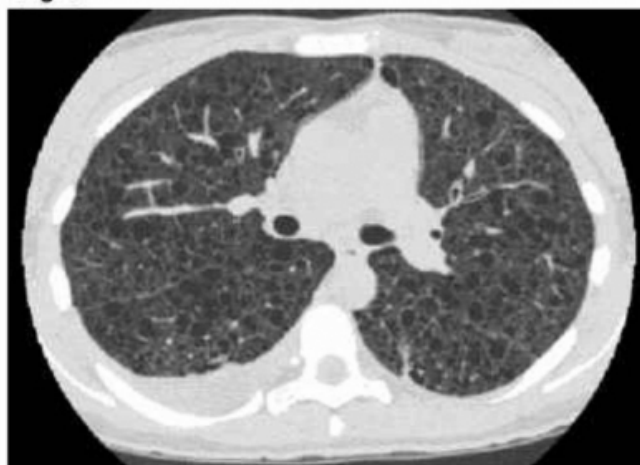
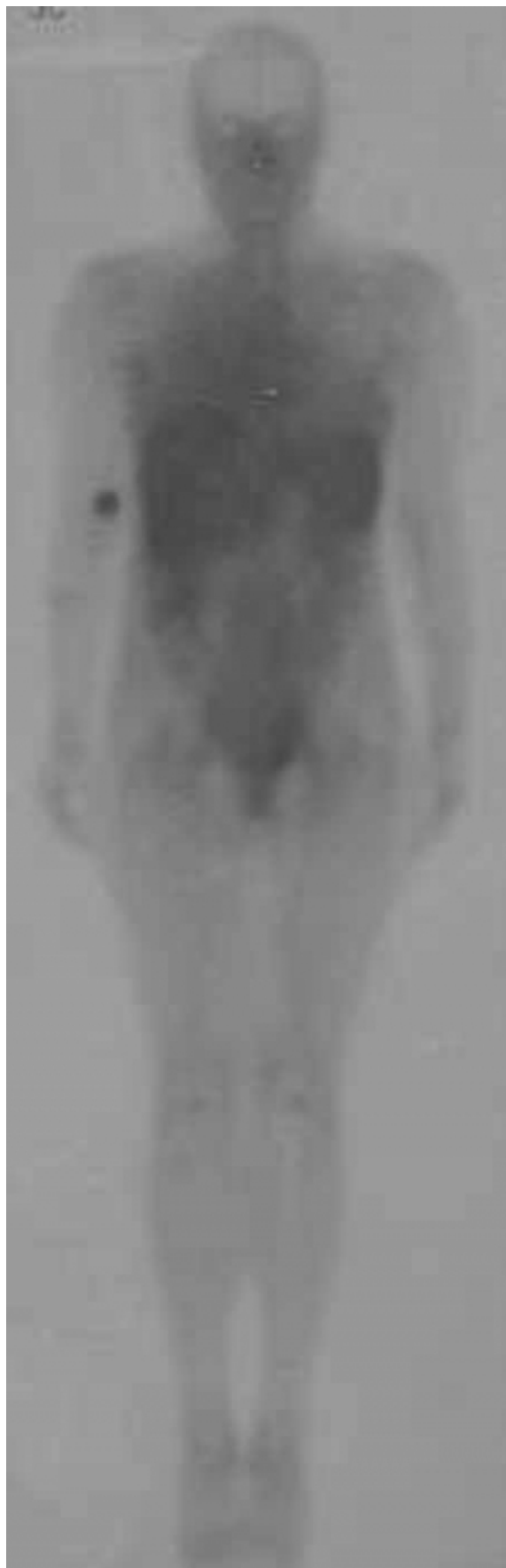
Figure 3

Figure 3: Whole body OctreoScan demonstrating diffusely increased uptake of 5.5mCi Indium 111 Octreotide in lung and kidney.



DISCUSSION

This result suggests somatostatin receptor-bearing tissue in TSC/LAM. This observation suggests a novel approach to the detection and monitoring of this disease and possible treatment with octreotide acetate, a cyclic octapeptide with down-regulating properties similar to the natural hormone somatostatin. Further studies addressing the importance of somatostatin receptor in these disorders is warranted.

CORRESPONDENCE TO

Daya Upadhyay, MD Division of Pulmonary and Critical Care Medicine 14-707 Tarry Building, 300 East Superior St, Chicago, Illinois 60611. Tel: (312) 908-8163, Fax: (312) 908-4650, E-mail: upadhyayd@pol.net

References

Author Information

Daya Upadhyay, M.D.

Division of Pulmonary and Critical Care Medicine, Northwestern University Medical School

Thomas Corbridge, M.D.,FCPP

Division of Pulmonary and Critical Care Medicine, Northwestern University Medical School