

# Olfactory neuroblastoma: Endoscopic- assisted cranial resection

S Bist, S Varshney, R Singh, S Bhagat, N Gupta

## Citation

S Bist, S Varshney, R Singh, S Bhagat, N Gupta. *Olfactory neuroblastoma: Endoscopic- assisted cranial resection*. The Internet Journal of Neurosurgery. 2008 Volume 6 Number 2.

## Abstract

Olfactory neuroblastoma (OAN) is an extremely rare malignant neoplasm of the nasal cavity. Here we report a case of OAN in a 30 years old man presenting with headache, unilateral progressive nasal obstruction and epistaxis. Nasal examination revealed a fleshy pink mass in the left nasal cavity. Computed tomographic scan showed a mass involving the nasal cavity, ethmoid sinuses and anterior cranial fossa. A diagnosis of OAN was established by histopathology and confirmed by immunohistochemistry. The nasal mass was excised via a lateral rhinotomy approach and the cranial extension of the tumor was resected completely from the cribriform plate, fovea ethmoidalis and dura by using endoscopes of different angles. An endoscopic assisted resection of the base of skull from the nasal cavity without a formal craniofacial resection was performed safely with oncologic safety. In this article, the potential advantages of endoscopic techniques along with past, present and future hope for the search for a better outcome of OAN will be discussed.

## INTRODUCTION

OAN is a malignant neoplasm of neuroectodermal origin that begins in neuroepithelial cells of the olfactory membrane in the roof of the nasal fossa. The tumor was first described in 1924 by Berger and Luc in the French medical literature under the name esthesioneuroepitheliome olfactif.<sup>1</sup> Various terminologies have been ascribed to this tumor, but the only two terms used in recent publications are esthesioneuroblastoma and olfactory neuroblastoma. It represents less than 5% of all sinonasal malignancies. The incidence of this tumor has a bimodal distribution with peaks at 20 and 50 years of age. Unlike most sinonasal malignancies, it is more common in women than men. This malignancy is still considered rare, although more than 1,400 cases had been reported in the literature. The majority of cases (80%) were reported within the past two decades. This certainly is the result of better recognition of this disease by pathologist's and probably because of the easier availability of immunohistochemistry, which currently forms the mainstay of diagnosis. Because OAN is so uncommon, it remains a neoplasm with controversy regarding its precise origin, staging and management. The source of this controversy primarily stems from the fact that almost no individual clinician, even institution, treats more than one case per year that has this diagnosis. Few data exist with respect to optimum management strategies, multiple

opinions exist regarding its management. Two other factors contribute to the controversy surrounding this neoplasm. First, this tumor exhibits varying biologic activity, ranging from an indolent growth to a highly aggressive neoplasm capable of rapid widespread metastasis. The second factor involves problems with precise histological diagnosis because OAN is often confused with other undifferentiated neoplasm of nasal cavity. Although diagnostic and treatment modalities have improved over the past two decades, treatment recommendations ranges from a minimally invasive approach<sup>2</sup> to craniofacial resection (CFR) combined with radiotherapy.<sup>3</sup> Although CFR remains the criterion standard for surgical resection of OAN, several recent series have focused on the role of endoscopic resection. The endoscopic approach may be divided into two categories: minimally invasive endoscopic resection (MIER) using an exclusive transnasal endoscopic technique and endoscopic-assisted cranionasal resection (EA-CNR) was using a combined craniotomy and endoscopic resection.

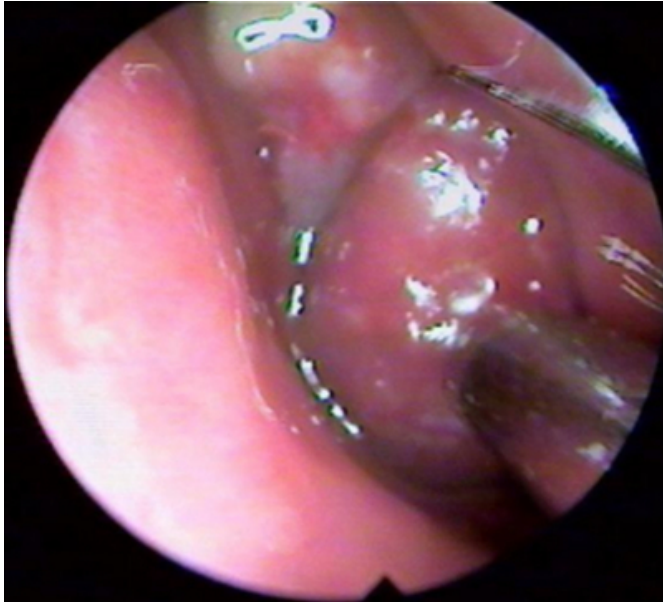
## CASE REPORT

A 30-year-old male consulted a Neurophysician with a 6 months history of progressive headache and single episode of epileptic fit for which he underwent CT scan of brain which incidentally revealed features of sinusitis, for which the patient was referred to the ENT department. On detailed history patient also complained of left sided progressive

nasal obstruction, blood stained nasal discharge and occasional frank epistaxis. On diagnostic nasal endoscopy (Fig.-1), a smooth, firm, fleshy pink mass was seen in the nasal cavity arising from the roof.

**Figure 1**

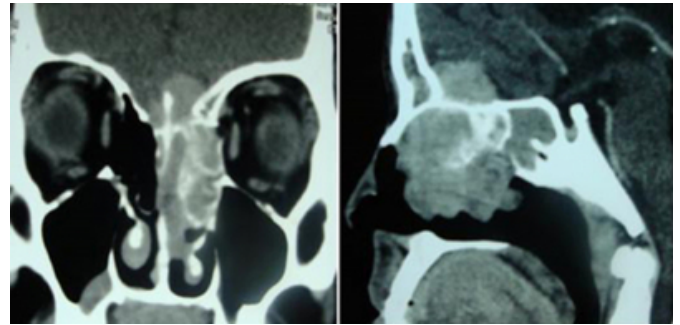
Fig.-1 Nasal endoscopy showing smooth fleshy pink mass in left nasal cavity



On probing, the mass was not attached to the septum or the lateral wall and bled on touch. Nasal patency test on left side was reduced and olfactory test revealed anosmia on both sides. Visual acuity and field of vision was normal in both the eyes and rest of the head and neck examination were un-remarkable. CECT Scan (Fig.-2) of nose and paranasal sinuses shows an enhancing soft tissue density mass involving the left ethmoidal air cells with breach in their bony margins. The mass was seen extending anteriorly into the left nasal cavity with thinning and erosion of nasal septum. Anterio- superiorly there was a breach in cribriform plate, fovea ethmoidalis with extradural intracranial extension of the mass. Posteriorly it was seen involving the left sphenoidal sinus.

**Figure 2**

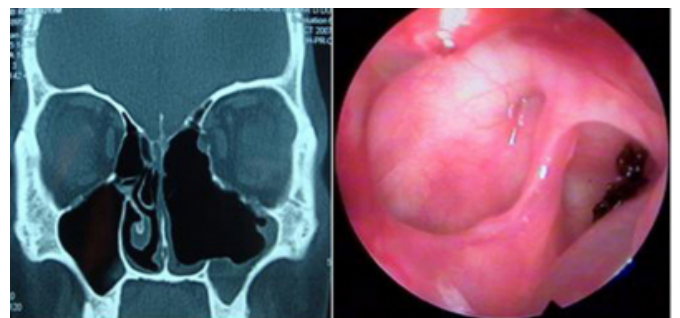
Fig.-2 Preoperative CT scans showing the tumor involving the cribriform area and extending in to the anterior cranial fossa.



Intranasal biopsy under local anaesthesia was performed. On histopathological analysis, the tumor was identified as OAN and later confirmed by immunohistochemistry. After complete systemic evaluation, the tumor mass was staged as T3N0M0 according to Dulguerov and Calcaterra classification. The treatment was planned as surgery and postoperative radiation. The sino-nasal part of the tumor was removed via lateral rhinotomy approach and medial maxillectomy with frontoethmoidectomy was performed. By using, the endoscopes of different angles, the cranial extension of the tumor was resected completely from the cribriform plate, fovea ethmoidalis and dura through the nasal cavity without a formal craniofacial resection. The postoperative period was uneventful and postoperative CT scan and nasal endoscopy (Fig-3) showed complete removal of the tumor mass.

**Figure 3**

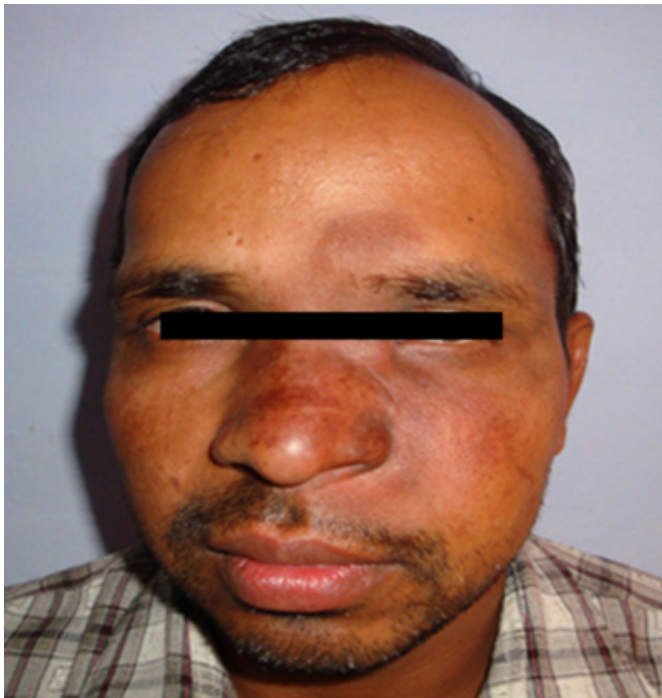Fig.-3 Postoperative CT scan and nasal endoscopy showing complete removal of the tumor mass.



Two weeks after the surgery the patient received involved field radiotherapy (40 Gy) without significant side effects (Fig-4). At six months follow up, there was no evidence of loco regional recurrence and systemic metastases. The patient was advised regular follow up.

**Figure 4**

Fig.-4 Post radiation clinical photograph



## DISCUSSION

OAN arises from olfactory neuroepithelium, which extends from the roof of the nose to the area of the superior turbinate and a portion of the nasal septum.<sup>3</sup> The exact cell origin of OAN is controversial but recently, it is regarded as originating from the basal cells of the olfactory neuroepithelium and no clear etiologic agent or exposure has been documented in humans. OAN shows no clear racial, geographic, or sexual predilection, though some studies do indicate a slight female predominance. The tumor has been reported in all age groups, but most of the cases described in literature involve adults, except for one case where it has been reported in a child as young as 2 years of age. The most common symptoms of OAN are nasal obstruction, recurrent epistaxis and headache. Patients with extensive tumor may have orbital features. Other symptoms include anosmia, facial pain, facial swelling and nasal discharge; sometimes patients might have undergone multiple procedures for removal of polyps. OAN is a neuroendocrine tumor capable of causing paraneoplastic syndromes by secreting peptides. The tumor usually appears as a gray to pink or red, firm polypoid mass high in the nasal vault, which bleeds easily during instrumentation. OAN can often be predicted from imaging characteristics, based on its location focused on the cribriform plate. It does not have a specific radiological appearance and appear as a homogeneous soft tissue mass with uniform and moderate contrast enhancement. High-

resolution CT scan and magnetic resonance imaging (MRI) can be used as complementary investigations to precisely delineate the extent of the tumor and to define the involvement of the cribriform plate, fovea ethmoidalis, anterior cranial fossa, lamina papyracea and retromaxillary space. Obstruction of the sinus-draining ostia results in an accumulation of nasal secretions, which is difficult to be differentiated from tumor tissue when viewed by a CT scan. But CT images are essential for correct staging and should be evaluated carefully for erosion of bones. MRI is often necessary for better delineation of sinonasal and intraorbital extension or an intracerebral extension. Using MRI, OAN appears as hypo intense to gray matter on T1-weighted images and isointense or hyper intense to gray matter on T2-weighted images. The typical histologic appearance of an OAN includes the presence of characteristic cells separated into nests or compartments by fibrovascular septae, neurofibrillary intercellular matrices, and rosette formations. The histologic diagnosis is often confounded by an architecture that is similar to many neurogenic tumors. Immunohistochemistry, however, can lead to a definitive diagnosis; this tumor is positive for neuroendocrine markers such as chromogranin, synaptophysin, neuron-specific enolase, and protein gene product.<sup>4</sup> Hyams et al<sup>5</sup> developed a four-point histological grading system for OAN based on features such as the degree of differentiation, the tumor architecture, mitotic index, nuclear polymorphism, fibrillary nature of the matrix and tumor necrosis. This tumor can either be extremely aggressive (grade 4) or relatively indolent (grade 1). Ancillary immunohistochemical analysis, ultra structural studies with electron microscope and DNA flow cytometry are currently the diagnostic tools available for OAN. Disease specific staging systems have been devised for OAN. The most useful and commonly used systems are those attributed to Kadish et al<sup>6</sup> and Dulguerov and Calcaterra<sup>7</sup>. Kadish et al were the first to devise more well accepted staging classification for OAN, which is based on the clinical spread of the tumor. Reservations about the Kadish system are based on the premise that there are minimal differences in the biologic behavior of stage A, B, and C tumors. Nevertheless, tumors in each of these classifications behave differently with respect to progression and metastasis, and therefore, survival patterns are different. Dulguerov and Calcaterra<sup>7</sup> introduced a staging system based on the TNM classification, which takes in to account the size of the primary tumor and the presence or absence of regional and distant metastasis. Their system is based on CT and or MRI finding. Dulguerov and Calcaterra staging

system has gained popularity and predicted disease-specific survival better than Kadish system. OAN have the potential to spread regionally. Neck metastasis can occur early in the disease or many years later. In 5% of patients, metastases to cervical nodes are evident at the time of presentation and distant metastases are already present in 7% of patients. Rinaldo et al reviewed 320 cases at 15 centres and found that the incidence of both synchronous and metachronous neck metastasis varied greatly, ranging from 5-100% (mean: 23.4%).<sup>4</sup> As is true for most head and neck cancers, cervical lymphadenopathy augurs poorly and increases the risk of distant metastasis, most often to bone.

The classical treatment strategies of OAN are based on surgery or radiotherapy as unique modalities or a combination of surgery and radiation therapy. More recently, chemotherapy has been introduced in therapeutic armamentarium. The literature gives little support to single – regimen because few studies advocate either surgery or radiation alone. Surgical resection combined with postoperative radiotherapy is considered the gold standard in the management of this tumor. Biller et al recommended craniofacial resection of all tumors, regardless of whether they invade the anterior cranial fossa or are confined to nasal roof.<sup>8</sup> They advocated resection of the dura over the cribriform plate, the olfactory bulb, the entire ethmoid labyrinth, and the anterior and posterior walls of the frontal sinus. A craniotomy probably is not justified for T1 tumors, where clear radiological evidence of a normal cribriform plate and upper ethmoid cells exist. All other patients should be treated by a transfacial approach combined with a bifrontal craniotomy. Craniofacial resection resulted in much better local control than other surgical resection, because craniofacial resection permits en-bloc resection of the tumor, with better assessment of any intracranial extension and protection of the brain and optic nerves. Although cranial floor defects as large as 4 cm may be present, bone grafts have not been necessary. The cranial floor is repaired by various techniques, including a pericranium flap, temporalis muscle and fascia transposition. This prevents the herniation of cranial contents in to the nasal cavity and the occurrence of cerebrospinal fluid leaks. Radical surgery of early lesions (T1 and T2) is not performed at all centers. As of now, craniofacial resection combined with radiotherapy is considered the gold standard in the management of this tumors.<sup>9</sup> The results of transnasal endoscopic resection followed by radiation have been reported to be comparable to those of craniofacial resection.<sup>9</sup> Although CFR remains the criterion standard for surgical resection of OAN, several

recent series have focused on the role of endoscopic resection. The endoscopic approach may be divided into two categories: (1) minimally invasive endoscopic resection (MIER) using an exclusive transnasal endoscopic technique and (2) endoscopic-assisted cranionasal resection (EA-CNR) using a combined craniotomy and endoscopic resection. Potential advantages of endoscopic techniques include enhanced visualization for preserving vital structures and determining tumor margins. Additionally, endoscopic approaches generally result in less collateral damage, offer superior cosmetic results and post-treatment surveillance. T1 and T2 lesions are most amenable to endoscopic resection because these tumors have not invaded the anterior cranial fossa or orbit. Cerebrospinal fluid leaks that result from a small violation of the dura during resection of the cribriform plate can be handled in the same fashion as handling an anterior skull base CSF leak encountered during more routine endoscopic sinus surgery. Because they invade the anterior cranial fossa, T3 and T4 lesions have been traditionally addressed solely with external approaches. The pursuit of minimally invasive techniques has also led to the use of endoscopic resection of the tumor combined with stereotactic irradiation of frontal skull base with a gamma-ray knife.<sup>2</sup> This approach avoids the morbidity associated with conventional radiation therapy (e. g., optic neuropathy or retinopathy). Neck dissection is indicated only in the presence of nodes; elective dissection appears to be unnecessary. Preoperative irradiation appears to have no beneficial effect. Postoperatively, some authors have recommended radiotherapy only for advanced tumors, while others have suggested that it should be administered to all patients regardless of tumor stage.<sup>7</sup> The availability of Intensity-modulated radiation therapy (IMRT) will be an effective tool to improve control rates while minimizing toxicity for patients with OAN. IMRT is an advanced form of three-dimensional conformal radiotherapy using computerized inverse treatment planning algorithms to achieve improved dose conformality and homogeneity of the target volumes and avoidance of adjacent critical normal tissues. The role of induction chemotherapy or concurrent chemoradiation therapy has not been defined. We know that OAN is chemosensitive and responsive to platinum- based agents, but chemotherapy is currently reserved for unresectable or recurrent tumors and for metastases.<sup>10</sup> In unresectable lesions, consideration may be given to the multimodal treatment such as preoperative chemotherapy and radiotherapy with local resection in an attempt to attain loco regional control and increase the chance of survival.



Despite aggressive therapy, recurrence can develop soon after treatment or even several years later. The time frame for recurrence in most head and neck malignancies is 18-24 months where in OAN it is much longer. Till date no morphologic features have been found to correlate reliably with prognosis, although clinical stage and tumor resectability with oncologically safe margins are more important factors to predict the outcome. However the “safe margin” of this tumor has not been ascertained. It is also difficult for the histopathologist to ascertain these margins due to the nature of the specimen. It is the responsibility of the surgical team to present the histopathologist with a specimen that can be assessed with reasonable accuracy. Treatment and survival rate are strongly dependant on stages. The 5 year survival rate for most widely used Kadish staging system are 90%, 70.9% and 46.7% for stage A, stage B and stage C respectively. The prognosis for long term survival is poor. Patients must be followed carefully with the understanding that loco-regional recurrences are common and may arise several years after treatment.

In conclusion, patients with OAN can be treated with various combinations of surgery, radiotherapy and chemotherapy; treatment philosophies vary among institutions. But it is common consensus that OAN requires aggressive surgical resection and radiation therapy. Newer craniofacial surgical techniques combined with radiotherapy have significantly improved disease-free long-term survival rates<sup>3</sup>. There are still areas for future research: (1) - the role of endoscopic surgery for OAN needs to be defined by multicentre outcome studies and for which stage of tumors it can be used for definitive resection without compromising survival, (2) -

What is the most appropriate treatment for OAN and are the results for neoadjuvant chemoradiotherapy better than the traditional approach of surgery followed by radiotherapy? Does the addition of chemotherapy improve survival or just add morbidity?

### References

1. Berger L, Luc H, Richard R.L, Esthesioneuroepitheliome olfactif. Bull cancer (Paris) 1924;13:1410-21.
2. Walch C, Stammberger H, Anderhuber W, et al. The minimally invasive approach to olfactory neuroblastoma: Combined endoscopic and stereotactic treatment. Laryngoscope 2000; 110:635-40.
3. Broich G, Pagliari A, and Ottaviani F. Esthesioneuroblastoma: A general review of the cases published since the discovery of the tumour in 1924. Anticancer Res 1997; 17:2683-2706.
4. Rinaldo A, Ferlito A, Shaha AR, et al. Esthesioneuroblastoma and cervical Lymph node metastases; clinical and therapeutic implication. Acta Otolaryngology 2002; 122:215-21.
5. Hyams VJ. Tumors of the upper respiratory Tract and ear. In Hyams VJ, Batsakis J G, Michaels L, eds. Atlas of tumor pathology. 2nd series, fascicle 25. Washington, D. C.: Armed Forces Institute of pathology, 1988:240-8.
6. Kadish S, Goodman M, Wang CC. Olfactory neuroblastoma. A clinical analysis of 17 cases. Cancer 1976; 37:1571-6.
7. Dulguerov P, Calcaterra T. Esthesioneuroblastoma: The UCLA experience 1970-1990. Laryngoscope 1992; 102:843-9.
8. Biller HF, Lawson W, Sachdev VP, Som P. Esthesioneuroblastoma: Surgical treatment without radiation. Laryngoscope 1990; 100:1199-1201.
9. Casiano RR, Numa WA, Falquez AM. Endoscopic resection of Esthesioneuroblastoma. Am J Rhinol 2001; 15:271-9.
10. McElroy EA, Jr., Buckner JC, Lewis JE. Chemotherapy for advanced. Esthesioneuroblastoma: The Mayo Clinic experience. Neurosurgery 1998; 42:1023-7, discussion 1027-8.

**Author Information**

**S. S. Bist, (M.S.)**

Department of E.N.T & Head-Neck Surgery, Himalayan Institute of Medical Sciences, HIHT University

**Saurabh Varshney, (M.S.)**

Department of E.N.T & Head-Neck Surgery, Himalayan Institute of Medical Sciences, HIHT University

**R. K. Singh, (M.S.)**

Department of E.N.T & Head-Neck Surgery, Himalayan Institute of Medical Sciences, HIHT University

**Sanjeev Bhagat, (M.S.)**

Department of E.N.T & Head-Neck Surgery, Himalayan Institute of Medical Sciences, HIHT University

**Nitin Gupta, (M.S.)**

Department of E.N.T & Head-Neck Surgery, Himalayan Institute of Medical Sciences, HIHT University