

Arthroscopic synovectomy, an alternative in the treatment of brucellar arthritis of the knee with prolonged course. A report of two cases.

C Martin-Hernandez, J Ballester-Jimenez, T Espallargas-Doñate, A Fuertes-Vallcorba

Citation

C Martin-Hernandez, J Ballester-Jimenez, T Espallargas-Doñate, A Fuertes-Vallcorba. *Arthroscopic synovectomy, an alternative in the treatment of brucellar arthritis of the knee with prolonged course. A report of two cases.*. The Internet Journal of Orthopedic Surgery. 2008 Volume 13 Number 2.

Abstract

Brucellosis is a systemic infectious disease which shows a broad spectrum of clinical features. Among them, septic arthritis is one of the most frequent presentations. The authors present to cases of brucellar monoarthritis of the knee with a prolonged course in which arthroscopic synovectomy was performed. Although a combination therapy with two or more antibiotics is the treatment of election, in some cases the clinical course of the disease may be prolonged for a long time. In such cases, arthroscopic synovectomy and drainage of the joint should be considered as the next step to prevent further damage to the joint and bones when initial antibiotic treatment provides no improvement of the symptoms after one week of treatment.

INTRODUCTION

Brucellosis is a systemic infectious disease caused by small, gram-negative nonsporulating coccobacilli, the *Brucella*. It is a zoonosis transmitted to humans from infected animals, mainly cattle (goats and sheep) and other domesticated animals such as camels. ¹ *Brucellae* are shed in the feces, milk and urine of these animals and are transmitted to humans through direct contact, consumption of unpasteurized dairy products, or indirectly by environmental exposure to aerosolized infected fecal particles. Many *Brucella* species can produce human disease, including *Brucella mellitensis*, *Brucella abortus*, *Brucella Suis* and, rarely, *Brucella canis*. Among them, *Brucella mellitensis* is the most common source of human infection. It is still endemic in many parts of the world, specially in the Mediterranean countries and the Middle East. The most common clinical features of human brucellosis are undulant fever, sweats, arthromyalgias, lymphadenopathy and hepatosplenomegaly. ² However, bone and joint infections are the most frequent localized sites, accounting for up to 85% of these cases. ^{3,4} In its acute form, peripheral poly- or mono-arthritis, specially of the larger joints, is a common clinical finding. A single swollen and painful joint is frequently observed as osteoarticular manifestation. The knee has in fact been found to be one of the most commonly

affected joint in endemic areas in Greece, Kuwait , and Peru

· 5

Brucellosis septic arthritis has become extremely rare in Western Europe and may be misdiagnosed because its variable clinical pictures and, in some chronic cases, microbiological and serological negativity . For this reason, suspicion of *Brucella* infection may sometimes be the key for correct diagnosis, specially in endemic regions.

Although a combination therapy with two or more antibiotics is the treatment of election, in some cases it fails and the clinical course of the disease may be prolonged for a long time. In these cases, as proposed for other septic arthritis, an alteration in the microbial regimen with more definitive drainage should be considered in order to prevent complications such as osteomyelitis, and chondral damage. ⁶

The authors present two cases in which antibiotic therapy failed and arthroscopic synovectomy was performed. Arthroscopic synovectomy should be the treatment of choice when antibiotic therapy provides no improvement of the symptoms after one week of treatment.

CASE REPORTS

CASE 1

A 53-year-old cattleman was admitted to our department with a three-week history of pain and swelling of the right knee without any history of trauma. Clinical examination revealed a temperature of 37.5°C, a swollen and tender knee with effusion and limited motion.

Haematological and biochemical tests were within the normal limits. Erythrocyte sedimentation rate (ESR) was 15 mm/h, C-reactive protein (CRP) showed an increase at 11 mg/l. Antistreptolysin O and rheumatoid factor were normal.

Plain radiographs revealed no pathological findings and magnetic resonance imaging showed an important hyarthrosis and synovitis.

A viscous white synovial fluid was obtained through aspiration under sterile technique. Cell count was 9000 cells/mm³ with lymphocytic predominance (72% Lymphocytes, 26% neutrophils, 2% monocytes). Positive Rosa Bengal test and microagglutination tests were positive. Definitive isolation of *Brucella melitensis* was made after culture.

Anti-inflammatory drugs and oral combined therapy with Doxycycline (100 mg/12 hours) and Rifampicin (300 mg/12 h) were then initiated.

Slight relief of the symptoms was achieved, but four weeks later, effusion was still present.

Trimethoprim/sulfamethoxazole was then added for two more weeks when

arthrocentesis was performed again, and the same bacterium was isolated in a new culture. Then, an arthroscopy was decided. An important and panarthritic nodular synovitis and a full thickness 20x10 mm chondral lesion in the medial condyle were found (fig. 1 a,b).

Figure 1

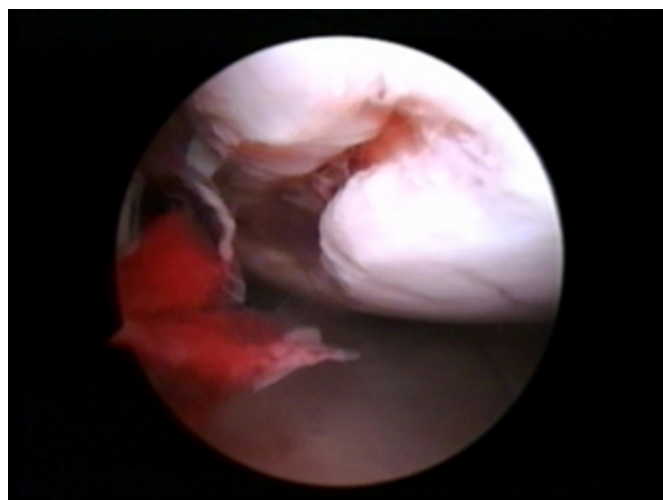
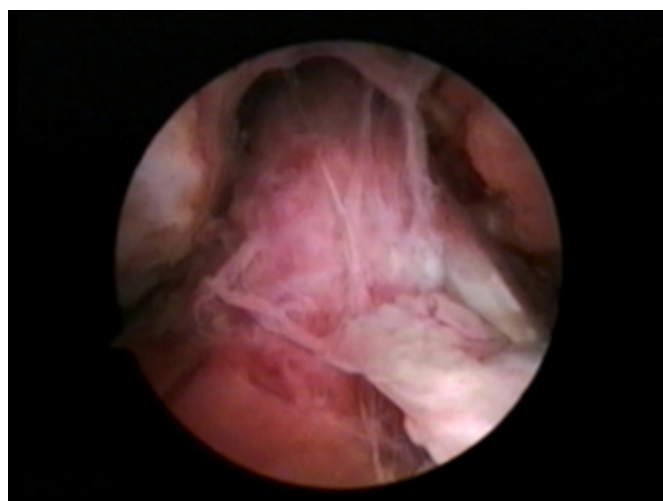
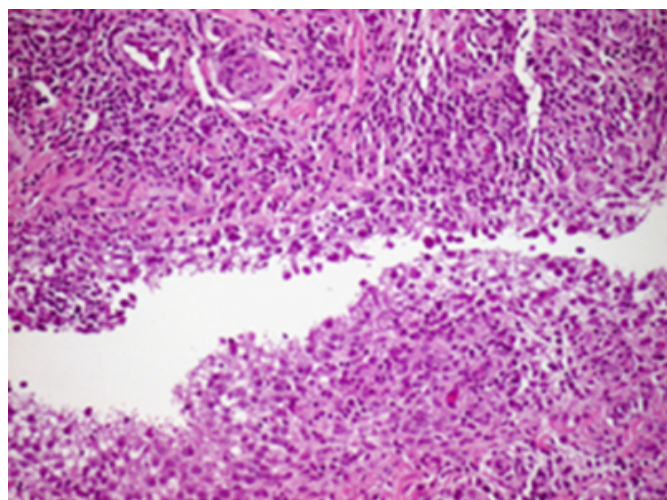


Figure 2



Subtotal synovectomy was performed by means of radiofrequency vaporization. Fragments of synovium were harvested for histological and microbiological examination. Histological study of the synovium showed chronic nonspecific synovitis with areas of acute activity (fig.2).

Figure 3



Symptoms improved quickly after the operation with complete resolution after two weeks. The antibiotic therapy was continued for a total duration of six more weeks when CRP and ASR returned to normal values.

CASE 2

A 45-year-old male veterinarian was admitted to our department with swelling and limited range of motion of the right knee that had started two months before. As he was a formerly known hyperuricemic patient, he had been treated initially with colchicines and indometacine by his general practitioner, but symptoms had not relieved. Laboratory tests revealed white blood cell count of 12000 cells/mm³, an ESR of 34 mm/h, CRP of 9.5 and positive Rosa Bengal and microagglutination tests. Radiographic and MRI studies showed nothing but intraarticular effusion. Arthrocentesis was performed and culture of the synovial fluid was positive for *Brucella melitensis*. Antibiotic therapy with Doxycycline, Rifampicin and intramuscular Streptomycin (750 mg per day for two weeks) was started and continued for six weeks without improvement of the symptoms. Based on the previous experience of case 1, an arthroscopic subtotal synovectomy was performed. Same nodular synovitis was found (fig 4) and cultures of the synovium were still positive. Three weeks after surgery, patient was completely relieved and antibiotic treatment was finished.

DISCUSSION

Osteoarticular involvement in brucellosis is the second most frequent presentation of the disease, and most commonly affects spine, sacroiliac, and peripheral joints. ⁷ Eradication of bovine brucellosis in Western Europe and pasteurising milk and dairy products has made the human disease very

rare, and it has thus become less well known by the practitioners. ⁸ Definitive diagnosis of brucellosis can be difficult, because this disease is less frequent than other arthritis and usually acquires a chronic evolution. Moreover, blood and synovial cultures are often negative. ^{9,10} Nevertheless, in the two cases presented, diagnosis was easily made after positive results of cultures.

Initial treatment in case 1 consisted in a two-antibiotic therapy that was ineffective. The addition of a third antibiotic did not improve results.

In case 2, a three-antibiotic therapy was initiated as suggested in the literature. ¹¹

In these cases, eradication of the infection could not be achieved by means of antibiotic treatment. The prolonged clinical courses could have yielded to complications such as osteomyelitis or osteolytic lesions as previously described. ^{12,13} Conservative antibiotic therapy is the treatment of choice for brucelloseptic arthritis although neither an optimal antibiotic combination nor its duration can be recommended. In 1986, the World Health Organization recommended the use of doxycycline and rifampicin for six weeks for systemic brucellosis. ¹⁴ However, a higher number of relapses have been described when using this treatment as compared with the classic regimen of doxycycline and streptomycin. ¹⁵ Initial triple therapy with extensive surgical debridement has been recommended when infection occurs around orthopaedic implants. It is also well known that, if initial treatment fails, an alteration in the microbial regimen with more definitive joint drainage by means of arthroscopic or open techniques should be considered in bacterial arthritis to prevent further damage to the joint and bones. Thus, arthroscopic debridement and synovectomy should be performed when disease shows no response to antibiotic therapy.

In both our cases persistent positive cultures made it advisable surgical debridement by means of radiofrequency vaporization to avoid intraarticular bleeding and bacteremia.

CONCLUSIONS

Arthroscopic synovectomy and drainage of the joint should be considered as the next step when initial antibiotic treatment of brucelloseptic arthritis fails and provides no improvement of the symptoms after one week of treatment.

References

1. Corbel MJ. Recent advances in brucellosis. *J Med Microbiol* 1997;46:101-3.
2. Young EJ (2000) *Brucella* species. In: Mandell GL, Bennett JE, Dolin R (ed) *Mandell, Douglas and Bennett's principles and practice of infectious diseases*, 5th ed. Churchill Livingstone, Philadelphia: pp 2386-93.
3. Alarcon GS, Bocanegra TS, Gottuzo E, Espinoza LR. The arthritis of brucellosis: a perspective one hundred years after Bruce's discovery. *J Rheumatol* 1987;14:1083-5.
4. Moussa AR, Muhtaseb SA, Almudallai DS, Khodeir SM, Marafie AA. Osteoarticular complications of brucellosis: a study of 169 cases. *Rev Infect Dis* 1987; 9:531-43.
5. Andonopoulos AP, Asimakopoulos G, Anastasiou E, Bassaris HP. *Brucella* arthritis. *Scand J Rheumatol* 1986; 15(4):377-80.
6. Wirtz DC, Marth M, Miltner O, Schneider U, Zilkens KW. Septic arthritis of the knee in adults: treatment by arthroscopy or arthrotomy. *Int Orthop* 2001;25:239-41.
7. Cairó M, Calbo E, Gómez L, Matamala A, Asunción J, Cuchi E, Garau J. Foreign-body osteoarticular infection by *Brucella melitensis*: A report of three cases. *J Bone Joint Surg Am* 2006;88(1):202-4.
8. Pourbagher A, Pourbagher MA, Savas L, Turunc T, Demiroglu YZ, Erol I, Yalcintas D. Epidemiologic, clinical, and imaging findings in brucellosis patients with osteoarticular involvement. *Am J Roentgenol* 2006;187(4):873-80.
9. Bosilkovski M, Krteva L, Dimzova M, Kondova I. Brucellosis in 418 patients from the Balkan Peninsula: exposure-related differences in clinical manifestations, laboratory test results, and therapy outcome. *Int J Infect Dis* 2007;11(4):342-7.
10. Taşova Y, Saltoğlu N, Sahin G, Aksu HS. Osteoarthricular involvement of brucellosis in Turkey. *Clin Rheumatol* 1999;18(3):214-219.
11. Solera J, Martinez-Alfaro E, Espinosa A. Recognition and optimum treatment of brucellosis. *Drugs* 1997;53:245-256.
12. Ayaşlıoğlu E, Özlük O, Kiliç D, Kaygusuz S, Kara S, Aydın G, Cokca F, Tekeli E. (2005) A case of brucellar septic arthritis of the knee with a prolonged clinical course. *Rheumatol Int* 25(1):69-71.
13. Wernaers P, Handelberg F. (2007) Brucellar arthritis of the knee: a case report with delayed diagnosis. *Acta Orthop Belg* 73(6):795-798.
14. World Health Organization. Joint FAO/WHO expert committee on brucellosis (1986). Sixth report. Technical Report Series 740. Geneva: World Health Organization.
15. Ariza J, Gudiol F, Pallares R, Viladrich PF, Rufi G, Corredoira J, Miravittles MR. (1992) Treatment of human brucellosis with doxycycline plus rifampicin or doxycycline plus streptomycin. A randomized, double-blind study. *ANN Intern Med* 117:25-30.

Author Information

Carlos Martin-Hernandez, MD

Department of Orthopaedics, Hospital Obispo Polanco

Juan J. Ballester-Jimenez, MD

Department of Orthopaedics, Hospital Obispo Polanco

Teresa Espallargas-Doñate, MD

Department of Orthopaedics, Hospital Obispo Polanco

Ariana Fuertes-Vallcorba, MD

Department of Orthopaedics, Hospital Obispo Polanco