

First case report of totally trans-umbilical laparoscopic de-roofing of large renal cyst with “Najran technique”

A Al Dowais, H Samei

Citation

A Al Dowais, H Samei. *First case report of totally trans-umbilical laparoscopic de-roofing of large renal cyst with “Najran technique”*. The Internet Journal of Surgery. 2008 Volume 21 Number 2.

Abstract

Solitary cysts in the kidney are common, but rarely cause any symptoms. Asymptomatic renal cysts may simply be followed up and often do not require treatment; however, symptomatic renal cysts must be treated, initially beginning with analgesic medication, although poor responders may require other more invasive methods. At present, the commonly used treatment methods include percutaneous aspiration with or without sclerosing agent injection, surgical resection and laparoscopic surgery. Laparoscopic de-roofing involves draining the cyst and removing part of the cyst wall. Here we report to our knowledge the first case of large symptomatic renal cyst in a 54-year-old lady treated successfully by laparoscopic de-roofing through totally trans-umbilical trans-peritoneal technique using three percutaneous stitches which we called “Najran technique”.

INTRODUCTION

Renal cysts are a very common condition that can occur in anyone from newborns to the elderly. Their incidence from birth to 18 years ranges from 0.1% to 0.45%, with an average incidence of 0.22%¹. In adults, their incidence gradually increases with age, and by age 40, is about 20%, while at age 60, it rises to 33%². As the majority of renal cysts are asymptomatic, they are often incidentally discovered. However, some renal cysts can cause symptoms such as flank pain (which is the most frequent complaint), palpable lumps in the abdomen, hematuria, hypertension, or urinary tract obstruction³⁻⁵. Diagnosis is made with ultrasound, computed tomographic (CT) scans, or urography.

Renal cysts were classified using morphological characteristics by Bosniak in 1986⁶. Simple cysts are classified as Bosniak category I, which are smooth-walled, without calcification, septation, or enhancement after contrast studies. They have a very low risk of becoming malignant. Treatment of symptomatic large simple cysts is mandatory because they may produce mechanical effects of a space-occupying lesion and also have a higher risk of rupture.

The use of laparoscopic surgery to treat renal cysts was first proposed by Hulbert et al. in 1989⁷. It combines a high success rate of open surgery with low invasiveness and has thus gained wide acceptance.

Laparoscopic surgery typically uses three to six ports for a given procedure, with each port increasing the potential morbidity from bleeding, port-site hernia, internal organ damage and decreasing the cosmetic outcome^{8,9}. As a result of the risks associated with additional ports, a surge of interest has arisen in less-invasive alternatives.

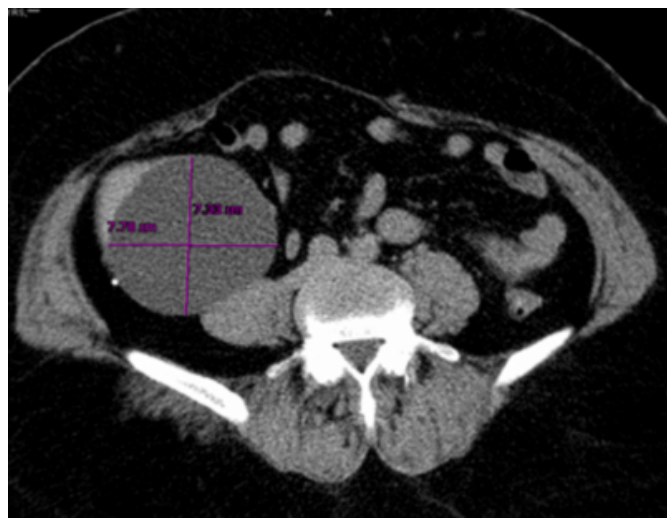
Attempts to perform urologic surgery through a single incision began with a report by Hirano et al.¹⁰ in 2005. Here we report a case of simple renal cyst treated successfully by a totally trans-umbilical laparoscopic de-roofing with our “Najran technique”.

CASE REPORT

A 54-year-old lady presented with right loin pain and with no urinary symptoms. Laboratory work-up showed normal values. US, CT (fig. 1) and IVU showed an about 8 x 7cm smooth-walled simple cyst of the lower pole of the right kidney with splaying of the pelvi-calyceal system, mild rotation and renal ptosis.

Figure 1

Figure 1: CT showing a right renal cyst

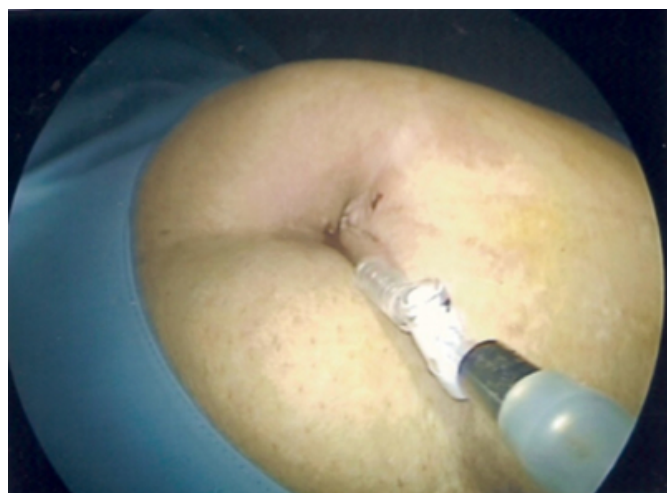


The patient was treated by totally trans-umbilical trans-peritoneal laparoscopic de-roofing using our technique:

Pneumoperitoneum created through an infra-umbilical incision using a Veres needle (fig. 2).

Figure 2

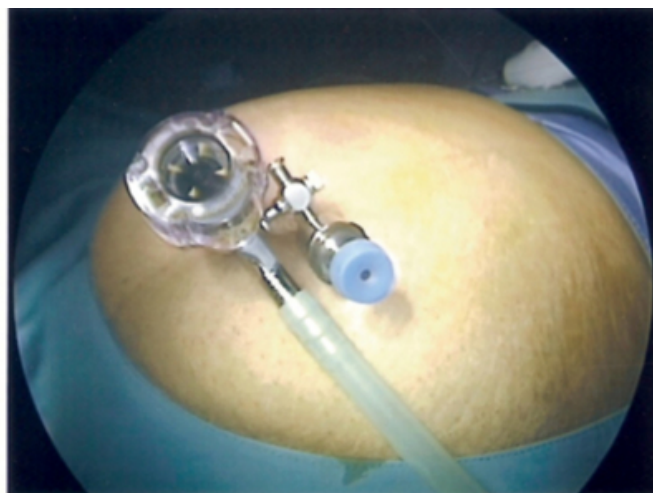Figure 2: Pneumoperitoneum by trans-umbilical Veres needle



Two 5mm ports were used, one supra-umbilical and other infra-umbilical (fig. 3).

Figure 3

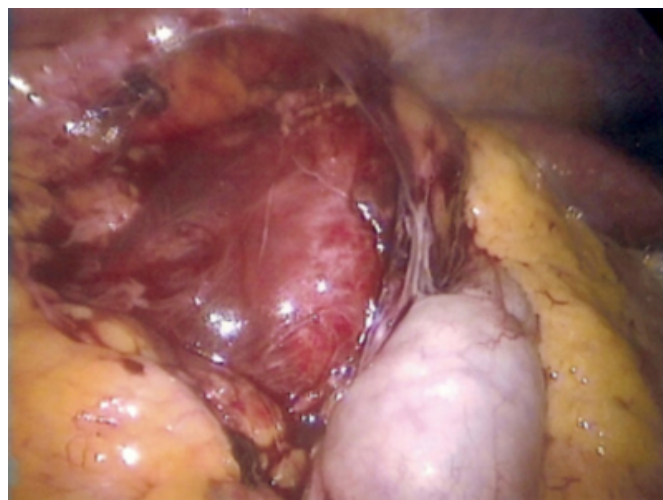
Figure 3: Two 5mm trocars through the umbilicus



Laparoscopic exploration revealed a large renal cyst at the lower pole of the right kidney (fig. 4).

Figure 4

Figure 4: The cyst has been surgically exposed



The cyst wall was suspended by three per-cutaneous sutures, the contents of cyst were percutaneously aspirated with a large-bore needle revealing clear fluid (fig. 5, 6) and the cyst was de-roofed with excision of part of the cyst wall using a harmonic scalpel (fig. 7).

Figure 5

Figure 5: Aspiration of cyst fluid

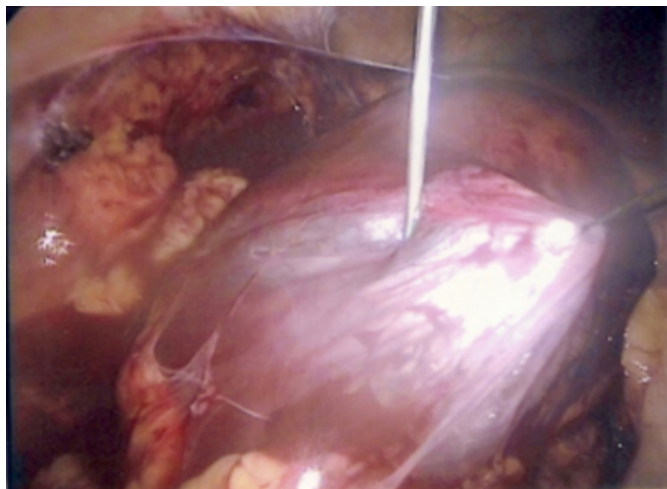


Figure 6

Figure 6: The cyst open

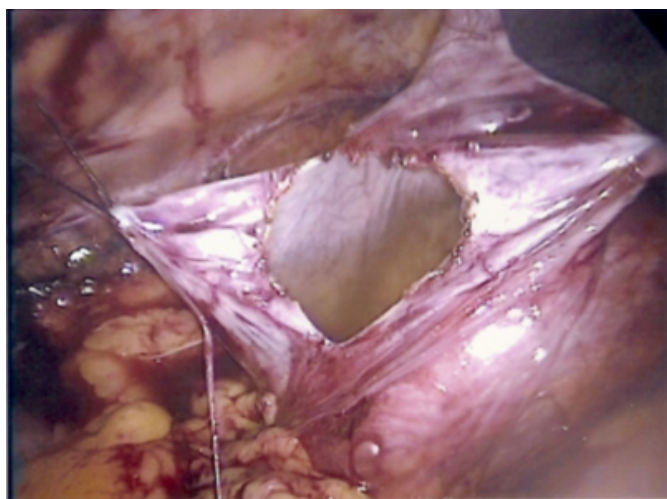
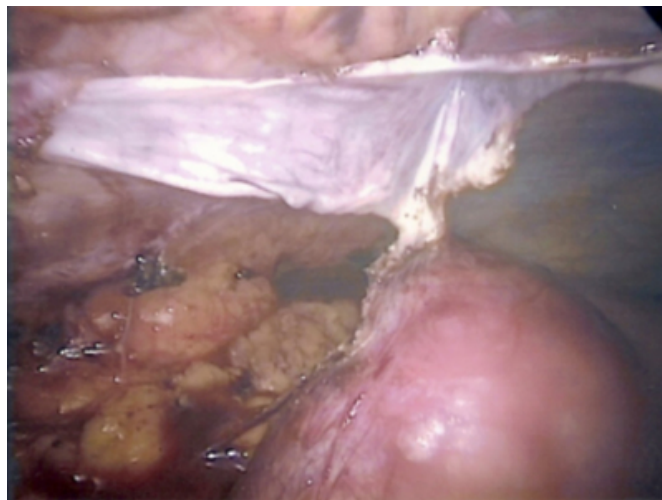


Figure 7

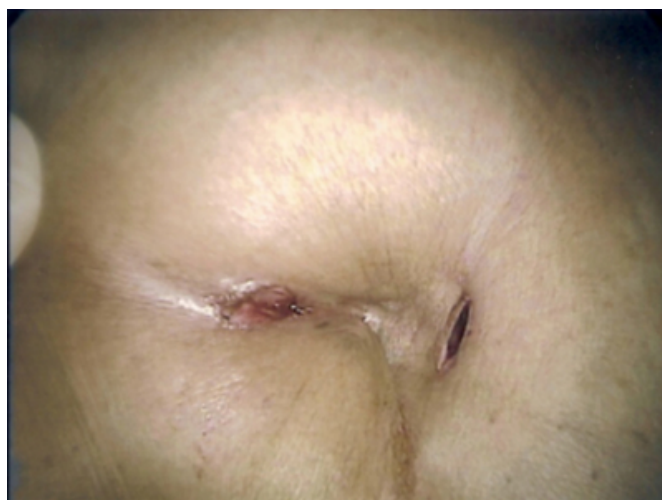Figure 7: Part of cyst wall removed after de-roofing



No leak was found (confirmed by retrograde pyelogram). The wounds at the end of the operation are shown in figure 8. Operating time was 53 minutes.

Figure 8

Figure 8: Trans-umbilical incisions at the end of the operation (two with 5mm)



The patient was mobilized and started oral intake on the same operation day and was discharged on the following day in a good general condition. Cytology of the cyst fluid was negative for malignancy. Histo-pathological examination of the cyst wall revealed an inflammatory simple renal cyst and no malignancy. The patient was reviewed after two weeks in the outpatient clinic and she was doing well.

DISCUSSION

Management of renal cysts includes percutaneous aspiration with or without sclerotherapy and un-roofing by either open

surgery or laparoscopy¹¹. Open surgery is now rare because of its invasiveness, and the concomitant risks and complications. Simple cyst aspiration for diagnosis and treatment results in cyst recurrence in 50%-80% of cases¹². Percutaneous aspiration and instillation of various kinds of sclerosing agents have been used but because of higher recurrence rates (20%-50%) they are no more favored¹²⁻¹⁴.

Laparoscopic un-roofing is an attractive minimally invasive alternative^{15,16}. The advantages include minimal postoperative pain and blood loss, a short hospital stay, and early convalescence. However, disadvantages of laparoscopic un-roofing include longer operation times, expensive equipment, and significant technical demands. In addition, strict criteria must be used in selecting patients for laparoscopic un-roofing to reduce the incidence of unsuspected malignancy. Only lesions that clearly meet the ultrasound or CT criteria for simple cysts should be approached laparoscopically. When a symptomatic large simple renal cyst (with a diameter >8cm) is diagnosed and definitive treatment of a cyst is indicated, laparoscopic un-roofing of the cyst is a more effective treatment than sclerotherapy.

Improvements in technology and refinement of technique have allowed urologists to perform a wide variety of complex procedures with laparoscopy, ranging from treatment of malignancy to reconstructive surgery¹⁷⁻¹⁹. With the advent of urologic laparoscopy in the 1990s, urologists have effectively changed procedures that once used one large incision to procedures that now use several small incisions.

Traditionally, multiple ports are a key prerequisite for laparoscopic surgery to allow optimal instrument triangulation. Due to the widespread acceptance of standard multiple-port laparoscopic surgery, currently ongoing efforts are focused on developing strategies to further reduce incisional morbidity with improved cosmetic outcomes as a secondary benefit.

The concept of scar-free, pain-free surgery has been a long-standing surgical fantasy, a chimera. Natural orifice trans-luminal endoscopic surgery (NOTES), a recent innovation, implies intra-abdominal surgery via natural orifices (vagina, mouth/stomach, and rectum). In a similar manner, the umbilicus is an embryonic (E) natural orifice which, since it is a scar itself, conceals the intra-abdominal entry point for surgical procedures²⁰.

Attempts to perform urologic surgery through a single incision began with a report by Hirano et al.¹⁰ in 2005. Here we report, to our knowledge, the first case of simple renal cyst treated successfully by a totally trans-umbilical laparoscopic de-roofing with our new technique which proved to be safe and effective with the advantages of short operating time, immediate postoperative symptomatic relief and a short convalescence period.

CONCLUSION

Totally trans-umbilical laparoscopic de-roofing with “Najran technique” is a safe and effective method to treat symptomatic renal cysts, with immediate postoperative symptomatic relief and a short convalescence period.

References

1. McHugh K, Stringer DA, Hebert D, et al. Simple renal cysts in children: diagnosis and follow-up with US. *Radiology* 1991;178:383-5.
2. Laucks SP Jr, McLachlan MSF. Aging and simple renal cysts of the kidney. *Br J Rad* 1981;54:12-4.
3. Holmberg G, Hietala SO. Treatment of simple renal cysts by percutaneous puncture and instillation of bismuth phosphate. *Scand J Urol Nephrol* 1989;23:207-12.
4. Hinman F Jr. Obstructive renal cysts. *J Urol* 1978;119:681-3.
5. Rockson SG, Stone RA, Gunnells JC Jr. Solitary renal cysts with segmental ischemia and hypertension. *J Urol* 1974;112:550-2.
6. Bosniak MA. The current radiological approach to renal cysts. *Radiology* 1986;158:1-10.
7. Hulbert JC, Shepard TG, Evans RE. Laparoscopic surgery for renal cystic disease (abstract). *J Urol* 1992; 147(Pt 2):433A.
8. Lowry PS et al. Symptomatic port-site hernia associated with a non-bladed trocar after laparoscopic live-donor nephrectomy. *J Endourol* 2003;17:493-494.
9. Marcovici I. Significant abdominal wall hematoma from an umbilical port insertion. *JSLS* 2001;5:293-295.
10. Hirano D et al. Retroperitoneoscopic adrenalectomy for adrenal tumors via a single large port. *J Endourol* 2005;19:788-792.
11. Richter S, Karbel G, Bechar L, et al. Should a benign renal cyst be treated? *Br J Urol* 1983;55:457-9.
12. Hanna RM, Dahniya MH. Aspiration and sclerotherapy of symptomatic simple renal cysts: value of two injections of sclerosing agents. *AJR Am J Roentgenol* 1996;167:781-3.
13. Okeke AA, Mitchelmore FX, Keeley JR, Timoney AG. A comparison of aspiration and sclerotherapy with laparoscopic de-roofing in the management of symptomatic simple renal cysts. *BJU Int* 2003;92:610-3.
14. Paananen I, Hellstrom P, Leinonen S, Merikanto J, Perala J, Paivansalo M, Lukkarinen O. Treatment of renal cysts with single-session percutaneous drainage and ethanol sclerotherapy: long-term outcome. *Urology* 2001;57:30-3.
15. Rane A. Laparoscopic management of symptomatic simple renal cysts. *Int Urol Nephrol* 2004;36:5-9.
16. Rubenstein SC, Hulbert JC, Pharand D, Schuessler WW, Vancaillie TG, Kavoussi LR. Laparoscopic un-roofing of symptomatic renal cysts. *J Urol* 1993;150:1103-6.
17. Rane A. Laparoscopy in urology: indications and

training. BJU Int 2002;90:142.

18. Smaldone MC et al. Laparoscopy in paediatric urology: present status. BJU Int 2007;100:143-150.

19. Stolzenburg JU et al. Role of laparoscopy for

reconstructive urology. Curr Opin Urol 2006;16:413-418.

20. Gill IS, Canes D, Aron M, Haber GP, Goldfarb DA, Flechner S, Desai MR, Kaouk JH, Desai MM. Single port transumbilical (E-NOTES) donor nephrectomy. J Urol 2008;180:637-41.

Author Information

Ali M. Al Dowais, MD

Department of General Surgery, King Khalid Hospital

Hamada A. Samei, MD, MRCS

Department of General Surgery, King Khalid Hospital