

Advanced Sinus Carcinoma Mistaken for a Malignant Glioma

N Agrawal, P Chokkalingam, D McRae

Citation

N Agrawal, P Chokkalingam, D McRae. *Advanced Sinus Carcinoma Mistaken for a Malignant Glioma*. The Internet Journal of Otorhinolaryngology. 2004 Volume 3 Number 2.

Abstract

A tumour mass involving the ethmoid sinus, the cribriform plate and the frontal lobe of the brain should be assumed to originate from the ethmoid sinus. The case history of a 61-year-old gentleman with ethmoid sinus adenocarcinoma extending to the frontal lobe is reported which demonstrates this.

INTRODUCTION

Direct spread of an ethmoid sinus carcinoma through the frontal bone and lamina cribrosa to the frontal lobe of the brain is not unusual. In contra distinction direct spread from a frontal lobe malignant glioma to the ethmoid sinus has not been reported. The corollary in the case of this is that a patient with a tumour involving the ethmoid sinus and the frontal lobe of brain prompt referral to an Otolaryngologist to obtain endoscopic biopsies of the ethmoid mass is advocated. If the diagnosis of a malignant sinus tumour is confirmed palliative treatment is advocated for patients with such advanced disease. This is because even if an aggressive treatment policy is attempted by means of frontal lobectomy combined with cranio-facial resection of the anterior skull base and involved fronto-ethmoid sinuses, no long term survivors have been reported. In the world's largest published series no patient survived longer than 10 months post surgery [1]. We report a case which demonstrates the basis for advocating this approach.

CASE REPORT

A 61-year-old gentleman was admitted by the Physicians with a 2-month history of increasing disorientation, headaches and personality change. He was a heavy smoker and worked as an office furniture manufacturer and in particular worked with hardwoods. Neurological examination was normal as was a chest x-ray. A CT scan of the brain was reported as showing a rounded heterogeneous mass in the right frontal lobe, extending inferiorly through the cribriform plate into the ethmoid sinuses. The patient was referred for neurosurgical assessment. An MRI scan of the brain confirmed a tumour extending from the right

ethmoid sinus through the lamina cribrosa and frontal bone to the frontal lobes of the brain. A presumptive diagnosis of glioblastoma multiforme extending to the ethmoid sinuses was made. The patient underwent a craniotomy for excision of the intracranial portion of the tumour. Histological examination confirmed a diagnosis of adenocarcinoma and the patient was referred for otolaryngology assessment. After discussions with Oncology colleagues, the patient had radical radiotherapy to the residual tumour, anterior skull base repair and residual frontal lobe. A planned debulking of his residual intranasal disease was abandoned after the patient developed meningeal metastases. The patient died 5 months post craniotomy.

Figure 1

Figure 1: Coronal MRI section showing tumour involving the ethmoid sinus and frontal lobe of the brain

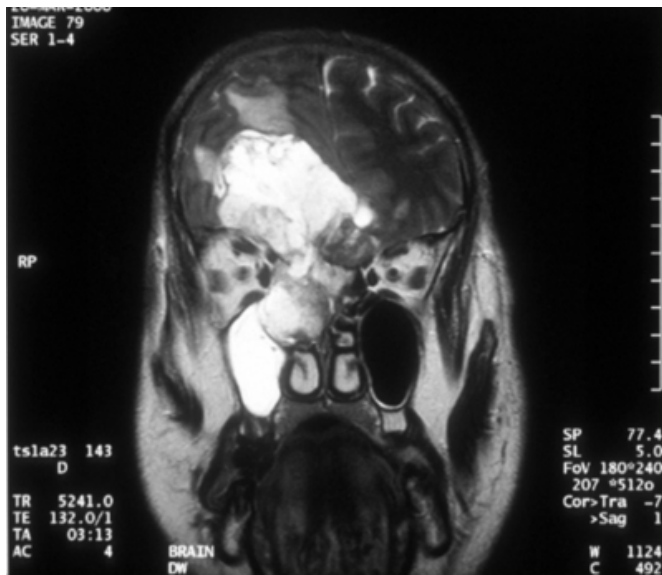
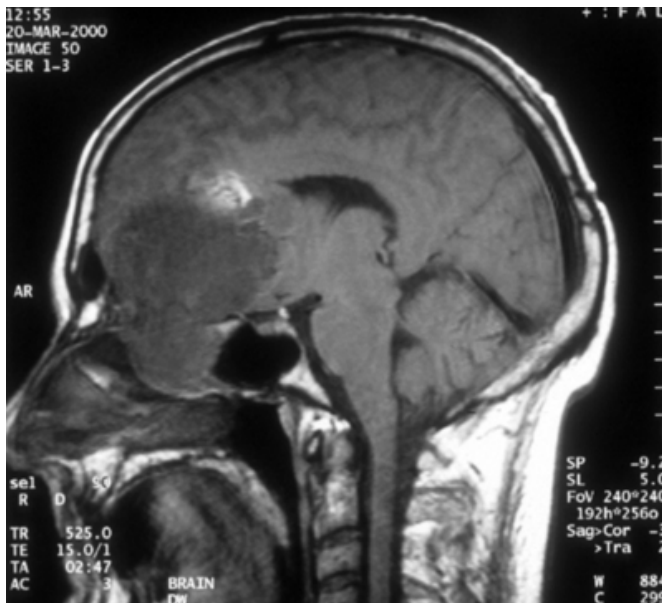

Figure 2

Figure 2: Sagittal MRI again demonstrating ethmoid sinus involvement spreading to brain



DISCUSSION

Malignant ethmoid tumours are rare sinonasal tumours [2]. This histologically diverse group includes squamous cell carcinoma, adenocarcinoma and aesthesioneuroblastoma. Epidemiologically adenocarcinoma has been associated with workers exposed to hardwood dust [3] (as in this case), nickel [4], chromium and leather dyes. The low incidence of sinonasal malignancy makes it difficult to accrue large numbers of patients and therefore there are relatively few

reports which have described long term outcomes from different treatment modalities for such cancers. Craniofacial resection is the treatment of choice for tumours that have reached the lamina cribrosa [1,5]. An extended lateral rhinotomy incision onto the forehead allows a midline window of bone to be elevated from the anterior frontal bone providing access to the floor of the anterior cranial fossa. This allows an en-bloc resection of both ethmoid complexes including the roof of the ethmoid sinuses, which comprises the floor of the frontal bone and the lamina cribrosa. In the largest published series survival graph for adenocarcinoma with brain invasion showed no survivors beyond 10 months post surgery [1]. However there was a ten per cent 5 year survival rate if tumor invaded dura but not brain. It is therefore clear that ethmoid carcinomas extending to the frontal lobe of the brain can only be treated palliatively. The effect on survival of giving radiotherapy before and after cranio-facial resection was compared in this series and showed no statistical difference.

Glioblastoma multiforme is a highly malignant tumour originating from astrocytes. Twenty percent of brain tumours are of this type. They have a poor prognosis with an average survival time of 6-18 months with 82-90% of patients dying within 2 years [6]. Glioblastoma multiforme rarely metastasise, with an estimated incidence of symptomatic metastases of 0.5 – 2%. [6,7] There were only 5 gliomas with spontaneous extracranial dissemination among 282 reported cases in a series review of extracranial metastases of primary brain tumours.[7] The most common sites of metastatic spread from glioblastoma multiforme are lung (60%) lymph nodes (50%) bone (30%) and liver (22%). [6] There are no reports of glioblastoma multiforme spreading directly through the lamina cribrosa to the ethmoid sinuses. Most cases of extracranial metastases from glioblastoma multiforme occur after invasive procedures such as craniotomy and cerebrospinal fluid shunting. [6] There have been a few cases reported where patients have not had a craniotomy. [6,8] The main factors responsible for the rarity of extracranial metastases of malignant brain tumours are considered to be the short post operative life span of these patients not allowing time for metastases to develop [9], the absence of cerebral lymphatics, early occlusion of venous channels by tumour compression and immune responses to the tumour cells [10].

CONCLUSION

Our case highlights how the misdiagnosis of a tumour, which involves the frontal lobe of the brain and the

ethmoids, led to unnecessary surgery. Any tumour with an intranasal component can be approached endoscopically thus allowing histologic confirmation. This would have allowed palliative care to be instigated and such care would not involve a craniotomy or a cranio-facial resection, which is associated with the rapid demise of such patients.

CORRESPONDENCE TO

Mr Namit Agrawal 1a Blackroot Road Sutton Coldfield
West Midlands B74 2QH Tel 07718-916214 Email
namitagrawal@yahoo.com

References

1. Lund VJ, Howard DJ, Wei WI, Cheeseman AD. Craniofacial Resection for Tumors of the Nasal Cavity and Paranasal Sinuses - A 17 year experience. *Head Neck* 1998;20:97-105
2. Katz TS, Mendenhall WM, Morris CG, Amdur RJ, Hinerman RW, Villaret DB. Malignant tumors of the nasal cavity and paranasal sinuses. *Head Neck* 2002;24(9):821-29
3. MacBeth R. Malignant disease of the paranasal sinuses. *J Laryngol Otol*. 1965;79:592-612
4. Doll R, Mathews JD, Morgan LG. Cancers of the lung and nasal sinuses in nickel workers: A reassessment of the period of risk. *Br. J. Industr. Med.* 1977;34:102-105
5. Shah JP, Kraus HK, Bilsky MH, Gutin PH, Harrison LH, Strong EW. Craniofacial resection for malignant tumors involving the anterior skull base. *Arch Otolaryngol Head Neck Surg.* 1997;123:1312-1317
6. Pasquier B, Pasquier D, N'Golet A, Panh MH, Couderc P. Extraneural metastases of astrocytomas and glioblastomas. *Cancer* 1980;45:112-125
7. Hoffman HJ, Duffner PK. Extraneural metastases of central nervous system tumours. *Cancer* 1985;56:1778-1782
8. Gamis AS, Egelhoff J, Roloson G et al. Diffuse bony metastasis at presentation in a child with glioblastoma multiforme. *Cancer* 1990;66:180-84
9. Smith DR, Hardman JM, Earle KM. Metastasizing neuroectodermal tumors of the central nervous system. *J Neurosurg* 1969;31:50-58
10. Grace JT Jr, Perese DM, Metzger RS, Sasabe T, Holdrige B. Tumor autograft response in patient with glioblastoma multiforme. *J Neurosurg* 1961;18:159-66

Author Information

Namit Agrawal, FRCS

Department of Otorhinolaryngology, Colchester General Hospital

Perumal G. Chokkalingam, FRCS

Department of Otorhinolaryngology, Colchester General Hospital

Duncan R. McRae, FRCS

Department of Otorhinolaryngology, Colchester General Hospital