

Extraskelatal osteosarcoma with rhabdomyosarcomatous differentiation in local recurrence and lung metastases or so-called malignant mesenchymoma of soft tissue: A phenomenon related with chemotherapy?

S Percinel, S Sak, H Erinanc, B Savas, A Sertcelik, I Okten

Citation

S Percinel, S Sak, H Erinanc, B Savas, A Sertcelik, I Okten. *Extraskelatal osteosarcoma with rhabdomyosarcomatous differentiation in local recurrence and lung metastases or so-called malignant mesenchymoma of soft tissue: A phenomenon related with chemotherapy?*. The Internet Journal of Pathology. 2007 Volume 7 Number 1.

Abstract

Extraskelatal osteosarcoma (ESOS), the soft tissue counterpart of primary skeletal osteosarcoma, is a rare tumor. Although rhabdomyosarcomatous differentiation may be seen in a variety of sarcomas, it has not been described in an ESOS. We report a case of ESOS, osteoblastic type, in the right upper extremity of a 50-year-old woman showing rhabdomyosarcomatous differentiation in the local recurrence and lung metastases, so-called malignant mesenchymoma of soft tissue. Rhabdomyoblasts, which were not observed in the initial specimen, were detected in the recurrent and metastatic tumors, which were obtained after the administration of chemotherapy with cisplatin and adriamycin. The patient died with a metastatic giant soft tissue mass occupying the inferior part of left hemithorax 17 months after the appearance of the initial tumor. We discuss the differential diagnosis of soft tissue tumors showing more than one differentiated tissue type and the factors that might play a role in the histogenesis of tumors with rhabdomyosarcomatous differentiation.

INTRODUCTION

A variety of sarcomas may contain rhabdomyoblastic elements. Liposarcomas^{1,2,3} and chondrosarcomas^{4,5}, which have a propensity for undergoing dedifferentiation, and malignant mesenchymoma^{6,7} may exhibit rhabdomyosarcomatous differentiation. To date, four primary skeletal osteosarcomas having rhabdomyoblasts as the sole sarcomatous component have been reported in the literature^{8,9,10,11}.

A computerized Medline search in the English literature has revealed only one case report of an osteosarcoma with rhabdomyosarcomatous differentiation in which rhabdomyoblasts were detected in lung metastasis⁹. To the best of our knowledge, the present case is thought to be the first case showing rhabdomyoblasts in local recurrence and metastases of extraskelatal osteosarcoma (ESOS). The literature is reviewed in an attempt to emphasize the diagnostic dilemma in the classification of soft tissue tumors showing more than one differentiated tissue type and to discuss the factors, which might play a role in the histogenesis of tumors with rhabdomyosarcomatous

differentiation.

CLINICAL HISTORY

A 50-year-old woman, without any previous history of trauma or radiation was admitted to our hospital with a 5-month history of a soft tissue mass, without any attachment to bony structures, in the distal one-third of right upper extremity in May 2002. The patient had a history of an excisional biopsy of the initial tumor, 8x6x6 cm in dimensions, performed in another hospital 4 months ago. On admission to our hospital, magnetic resonance imaging (MRI) revealed a recurrent soft tissue mass measuring approximately 7x4x4 cm with irregular borders in the distal one-third of right arm without an involvement of bone or periosteum. Computed tomography (CT) of the thorax showed six nodular lesions consistent with metastases in the superior and inferior lobes of the right lung and another mass in the inferior lobe of the left lung measuring 3x2.5x2 cm. Chemotherapy including cisplatin (20 mg/m², 5 days) and adriamycin (25 mg/m², 3 days) was started. At the end of two cycles of chemotherapy, the nodules detected in both lungs had dramatic regression; however, there was a

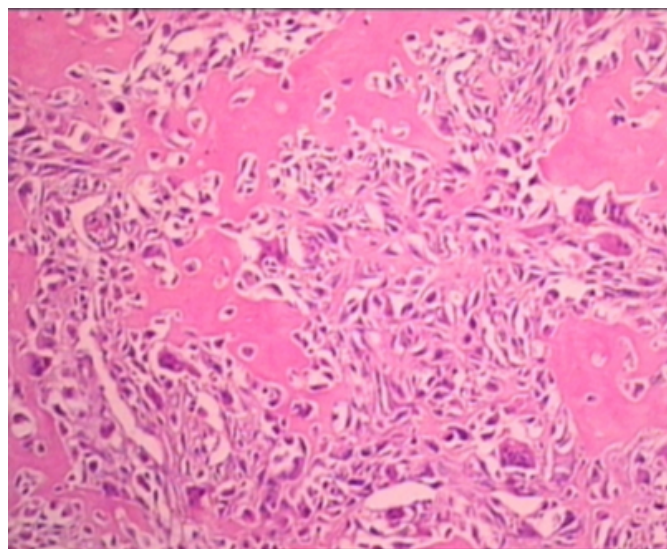
progressive growth of the mass in the right arm. Resection of the recurrent lesion was performed in August 2002. After six cycles of chemotherapy were completed, there was still regression in the dimensions of the nodules in both lungs. By MRI there was no recurrent lesion in the right arm at this stage of therapy. However, at the end of the seventh cycle of chemotherapy, progression was detected in all of the nodules seen in both lungs by thoracic CT in January 2003 and the metastatic nodules were resected. In May 2003, a giant soft tissue mass occupying the inferior part of left hemithorax with extrapleural extension was detected by thoracic CT. The patient received ifosfamide+mesna (1800 mg/m^2 , 5 days) but died shortly after, on May 29, 2003.

PATHOLOGIC FINDINGS

The initial resection material had been examined at an outside laboratory and only eight hematoxylin and eosin (H&E) sections were received. Histological examination of the slides at our department showed a tumor composed of irregular trabeculae containing osteoid, focal areas of necrosis, spindle/oval cells with hyperchromatic nuclei and osteoclast-like multinucleated giant cells. All slides examined revealed a similar morphological appearance and no area suggesting another type of tissue differentiation was observed. Based upon the lack of connection with the underlying bone, the tumor was diagnosed as an ESOS, osteoblastic type (Fig. 1).

Figure 1

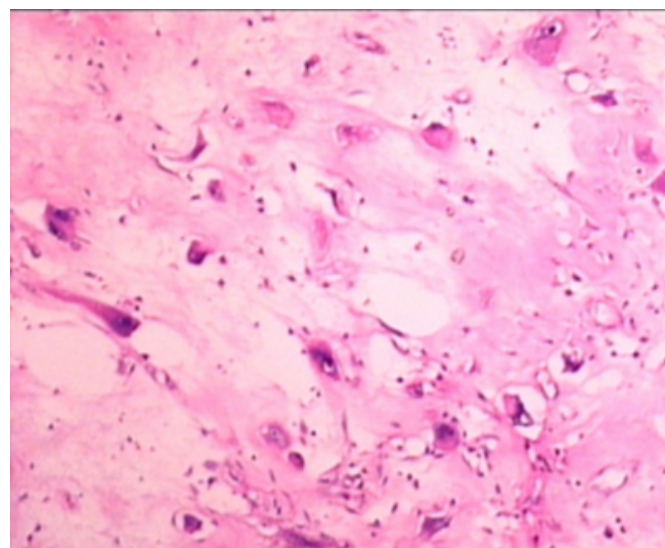
Figure 1: Initial tumor: extraskeletal osteosarcoma composed of irregular trabeculae of osteoid formation and osteoclast-like giant cells (Hematoxylin and eosin, x200).



The resection material of the local recurrence consisted of 12.5x4 cm skin ellipse with a depth of 8 cm. Beneath the skin ellipse, there was a lesion of 10x6x6 cm in dimensions, 5 mm from the closest resection margin, having gray-tan, necrotic, solid areas, focally showing infiltrative growth pattern and partially surrounded by subcutaneous adipose tissue and skeletal muscle. On histology, it was dramatically different from the initial tumor. The recurrent lesion was hypocellular with widespread necrosis, cystic myxoid and hyaline degeneration, composed of highly pleomorphic cells with abundant deeply eosinophilic cytoplasm. Some of the cells were strap-shaped and had conspicuous nucleoli; obvious cross striation was not seen (Fig. 2).

Figure 2

Figure 2: Local recurrence: hypocellular areas showing highly pleomorphic cells with abundant deeply eosinophilic cytoplasm and cells with strap forms (Hematoxylin and eosin, x200).



Many atypical mitoses were observed. Although the tumor was extensively sampled and examined carefully, no osteoid formation was detected. Immunohistochemically, some of the pleomorphic cells and particularly cells with abundant eosinophilic cytoplasm and cells with strap forms showed cytoplasmic positivity for desmin (DAKO; monoclonal antibody, 1:100) but not for myoglobin (Immunon; polyclonal antibody, 1:600) or myogenin (DAKO; monoclonal antibody, 1:50).

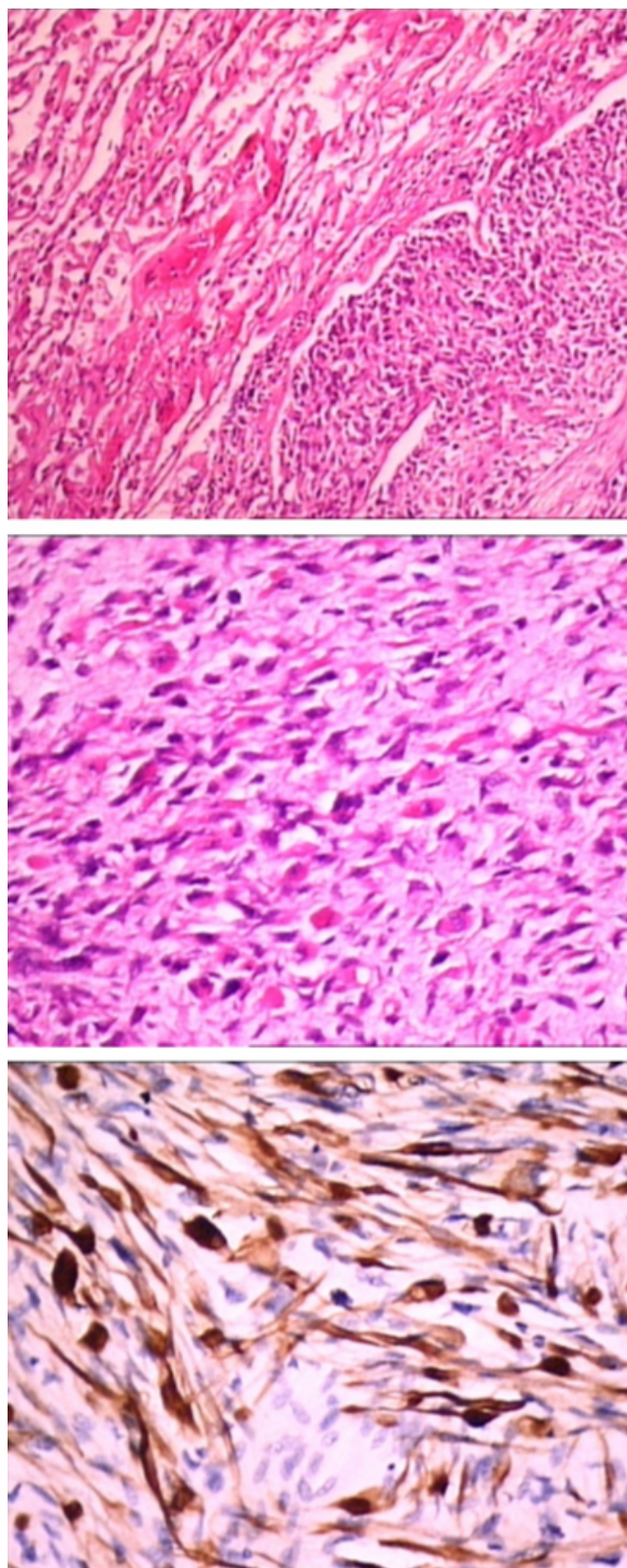
Examination of the metastasectomy specimens revealed three nodules, the largest showing a maximum diameter of 7 cm (Fig. 3A). The metastatic lesions showed pleomorphic sarcomatous areas with cells containing conspicuous

nucleoli and abundant deeply eosinophilic cytoplasm, globoid cells, and strap shapes having cross striations (Fig.

3B). A very minute focus suggesting osteoid formation was also observed. Most of these cells expressed strongly desmin (Fig. 3C) and myogenin but not myoglobin.

Figure 3

Figure 3: Metastatic nodule in the lung (A) (Hematoxylin and eosin, x200). Cells with abundant deeply eosinophilic cytoplasm, globoid cells, and strap forms having cross striations (B) (Hematoxylin and eosin, x400). Rhabdomyoblasts showing strong cytoplasmic positivity for desmin (C) (Diaminobenzidine, x400).



DISCUSSION

The tumor described in this report is composed of two

distinct differentiated malignant mesenchymal components, osteosarcoma and rhabdomyosarcoma. The initial biopsy was an ESOS, osteoblastic type. We were not able to perform immunohistochemical analysis on the initial tumor but the tumor was meticulously examined and there were no cells suggesting rhabdomyosarcomatous or any other sarcomatous differentiation. In contrast, the recurrent and metastatic tumors showed a dramatic change in morphology and rhabdomyoblasts became the dominant cellular component. At this point, there may be several explanations for this series of events: i) the rhabdomyosarcomatous component might have been overlooked in the initial tumor due to the specimen not being sufficiently sampled, ii) it has been shown that local recurrences and metastases can histologically display only one or dominant sarcomatous component¹², rhabdomyosarcomatous differentiation as in this case, and iii) chemotherapy itself may have resulted in a morphologic change since rhabdomyosarcomatous component may appear⁹, persist¹³, or disappear¹⁴ after chemotherapy.

A comparable case to ours was reported by Otsuka et al., in which the specimens obtained from the biopsy, first surgery, and subsequent hip disarticulation showed a primary bone osteosarcoma but no rhabdomyosarcomatous or any other sarcomatous component that could be interpreted as malignant mesenchymoma or dedifferentiated chondrosarcoma. Similar to our case, rhabdomyoblasts appeared in the second lung metastasis. The authors interpreted this morphological change as “rhabdomyosarcomatous metamorphosis” which was thought to be the result of differentiation in osteosarcoma cells. The chemotherapeutic agent ifosfamide was considered a possible cause of rhabdomyoblastic differentiation because rhabdomyoblastic differentiation was not observed during cisplatin and adriamycin therapy until chemotherapy was switched to ifosfamide. Similar to the aforementioned case, rhabdomyoblastic differentiation was not detected prior to use of chemotherapy in the present case. The detection of rhabdomyoblastic differentiation in the recurrent and metastatic tumors after the administration of chemotherapy but not in the initial tumor suggests a possible role for the chemotherapeutic agents used, cisplatin and adriamycin. In a study comparing morphological changes in rhabdomyosarcoma tissue specimens obtained before and after polychemotherapy (various combinations of cyclophosphamide, actinomycin D, adriamycin, bleomycin,

methotrexate, and vincristine) showed that the most striking features detected in the well- and moderately differentiated rhabdomyosarcomas were relative increases in the numbers of strap and round rhabdomyoblasts and increases in the size, eosinophilia, and fibrillary character of the cytoplasm after treatment¹⁵. It is interesting to note that cells with abundant deeply eosinophilic cytoplasm, some of which were globoid cells and strap-shaped cells having cross striations were detected after polychemotherapy in the recurrent and metastatic tumors in our case and in the second lung metastasis in the case of Otsuka et al.⁹. It may seem justified, therefore, to attribute at least part of these morphological changes to chemotherapy. Although it is unclear by which mechanisms chemotherapy affects tumor cells morphologically, it has been suggested that the major factor is the selective destruction of primitive tumor cells, which may in turn enhance the development of further differentiated cell lines and lead to a decrease in tumorigenicity¹⁵. However, the very rare occurrence of rhabdomyoblastic differentiation despite the common use of chemotherapy in osteosarcoma, suggests other factors may have played a role in this transformation.

Classification of soft tissue tumors showing more than one differentiated tissue type is still debatable. From a historic perspective, the term malignant mesenchymoma was first coined by Stout¹⁶ to describe non-epithelial malignant tumors “showing two or more unrelated, differentiated tissue types in addition to the fibrosarcomatous element” in 1948. The definition was later refined by Stout himself and Lattes¹⁷ as sarcomas composed of two or more unrelated, differentiated tissue elements, other than a fibrosarcomatous component. This term, however, has been used in different settings since. In 1991, Newman and Fletcher⁶ attempted to refine the criteria regarding this entity by excluding the morphologic patterns that were judged to show no specific differentiation, such as fibrosarcoma, hemangiopericytoma, pleomorphic malignant fibrous histiocytoma, myxofibrosarcoma, and dedifferentiated sarcomas. There are several neoplasms that fulfill Stout's definition of malignant mesenchymoma but they are arbitrarily regarded as distinct entities. This group includes malignant Triton tumor, dedifferentiated liposarcoma, and chondrosarcoma with a second differentiated component¹⁸. The last World Health Organization classification of soft tissue tumors states that this group of tumors does not form a separate clinicopathologic entity and grouping them together under

one heading is misleading. Thus it is proposed that potential candidates for the designation can be more appropriately classified in other ways¹⁹. Weiss and Goldblum¹⁸ also believe that the label "malignant mesenchymoma" is best deleted from classification schemes, and that sarcomas displaying two or more lines of differentiation are best diagnosed by identifying the lines of differentiation, their approximate amounts, and the grade of the most aggressive component.

The histogenesis of this group of lesions remains obscure. These tumors may arise from a primitive mesenchymal cell with the ability to differentiate into various components, or the neoplasm may itself contain multiple clones from which the various components are derived. It seems likely that aberrant gene expression or inhibition plays a role. Several human muscle-specific regulatory factors like myogenin, MyoD, Myf-3, Myf-5, and Mrf-4 are capable of inducing skeletal muscle differentiation when introduced in non-muscle cells²⁰; e.g., MyoD DNA transfection in fibroblasts and differentiated melanoma, neuroblastoma, liver, and adipocyte cell lines results in skeletal muscle differentiation²¹. The exact role, however, of these and other muscle-specific regulatory factors in the histogenesis of tumors with rhabdomyoblastic differentiation remains to be elucidated.

In summary, we present the first case of ESOS with rhabdomyosarcomatous differentiation in which the local recurrence and lung metastases developed rhabdomyoblastic differentiation, possibly related with the chemotherapeutic agents. Rhabdomyosarcomatous differentiation in skeletal or extraskelatal osteosarcoma seems to have a negative prognostic effect. Therefore, it may be useful to report the lines of tissue differentiation, their approximate amounts, and the grade of the most aggressive component in sarcomas displaying more than one line of differentiation and to note if any differentiated tissue occurs, persists or disappears in relation to chemotherapy.

CORRESPONDENCE TO

Sibel Percinel, M.D. Address: Ankara Universitesi Tip Fakultesi Patoloji Anabilim Dalı, Morfoloji Binasi, Sihhiye, 06100, Ankara, Turkey email: sibelpercinel@yahoo.com Tel.: +90.312.310.30.10/303 Fax: +90.312.310.63.70

References

1. Tallini G, Erlandson RA, Brennan MF, Woodruff JM. Divergent myosarcomatous differentiation in retroperitoneal liposarcoma. *Am J Surg Pathol* 1993;17:546-56.

2. Evans HL, Khurana KK, Kemp BL, Ayala AG. Heterologous elements in the dedifferentiated component of dedifferentiated liposarcoma. *Am J Surg Pathol* 1994;18:1150-7.
3. Henricks WH, Chu YC, Goldblum JR, Weiss SW. Dedifferentiated liposarcoma: a clinicopathological analysis of 155 cases with a proposal for an expanded definition of dedifferentiation. *Am J Surg Pathol* 1997;21:271-81.
4. Niezabitowski A, Edel G, Roessner A, Grundmann E, Timm C, Wuisman P. Rhabdomyosarcomatous component in dedifferentiated chondrosarcoma. *Path Res Pract* 1987;182:275-9.
5. Reith JD, Bauer TW, Fischler DF, Joyce MJ, Marks KE. Dedifferentiated chondrosarcoma with rhabdomyosarcomatous differentiation. *Am J Surg Pathol* 1996;20:293-8.
6. Newman PL, Fletcher CDM. Malignant mesenchymoma: clinicopathologic analysis of a series with evidence of low-grade behavior. *Am J Surg Pathol* 1991;15:607-14.
7. Brady MS, Perino G, Tallini G, Russo P, Woodruff JM. Malignant mesenchymoma. *Cancer* 1996;77:467-73.
8. Marcial-Seoane RA, Marcial Seoane MA, Davila-Toro FJ, Marcial-Rojas RA. Bone tumors of mixed origin: osteo-liposarcoma and osteo-rhabdomyosarcoma. *Bol Asoc Med PR* 1990;82:378-93.
9. Otsuka T, Matsui N, Ohta H, Hattori M, Nakamura T. Osteosarcoma with deeply eosinophilic rhabdomyoblast cells in a lung metastatic focus. A case report. *Clin Orthop Relat Res* 1993;293:307-9.
10. Kessler S, Mirra JM, Takeshi I, Thompson JC, Brien EW. Primary malignant mesenchymoma of bone: case report, literature review, and distinction of this entity from mesenchymal and dedifferentiated chondrosarcoma. *Skeletal Radiol* 1995;24:291-5.
11. Dorpe JV, Sciort R, Samson I, Vos RD, Brys P, Damme BV. Primary osteorhabdomyosarcoma (malignant mesenchymoma) of bone: a case report and review of the literature. *Mod Pathol* 1997;10:1047-53.
12. Mirra JM, Marcove RC. Fibrosarcomatous dedifferentiation of primary and secondary chondrosarcoma. *J Bone Joint Surg* 1976;56A:285-96.
13. Mrad K, Sassi S, Smida M, Oubiche F, Mekni A, Romdhane KB. Osteosarcoma with rhabdomyosarcomatous component or so-called malignant mesenchymoma of bone. *Pathologica* 2004;96:475-8.
14. Lamovec J, Zidar A, Bracko M, Golouh R. Primary bone sarcoma with rhabdomyosarcomatous component. *Path Res Pract* 1994;190:51-60.
15. Molenaar WM, Oosterhuis JW, Kamps WA. Cytologic "differentiation" in childhood rhabdomyosarcomas following polychemotherapy. *Hum Pathol* 1984;15:973-9.
16. Stout AP. Mesenchymoma: the mixed tumor of mesenchymal derivatives. *Annu Surg* 1948;127:278-90.
17. Stout AP, Lattes R. Tumors of the soft tissues. In: Firminger HI, ed. *Atlas of Tumor Pathology*. 2nd series. Fascicle 1. Washington, DC: Armed Forces Institute of Pathology; 1967:172-5.
18. Weiss SW, Goldblum JR. Malignant soft tissue tumors of uncertain type. In: Weiss SW, Goldblum JR, eds. *Enzinger and Weiss's soft tissue tumors*. 4th ed. St. Louis: Mosby; 2001:1550-2.
19. Fletcher CDM, Unni KK, Mertens F. Malignant mesenchymoma. *World Health Organization Classification of Tumours. Pathology and Genetics of Tumours of Soft Tissue and Bone*. Lyon: International Agency for Research on Cancer Press; 2002:215.

20. Rawls A, Morris JH, Rudnicki M, Braun T, Arnold HH, Klein WH, Olson EN. Myogenin's functions do not overlap with those of MyoD or Myf-5 during mouse embryogenesis. Dev Biol 1995;172:37-50.

21. Weintraub H, Tapscott SJ, Davis RL, Thayer MJ, Adam MA, Lassar AB, Miller AD. Activation of muscle-specific genes in pigment, nerve, fat, liver, and fibroblast cell lines by forced expression of MyoD. Proc Natl Acad Sci U S A 1989;86:5434-8.

Author Information

Sibel Percinel, M.D.

Senior Registrar in Pathology, Department of Pathology, Faculty of Medicine, Ankara University

Serpil Dizbay Sak, M.D.

Professor of Pathology, Department of Pathology, Faculty of Medicine, Ankara University

Hilal Erinanc, M.D.

Resident in Pathology, Department of Pathology, Faculty of Medicine, Ankara University

Berna Savas, M.D.

Senior Registrar in Pathology, Department of Pathology, Faculty of Medicine, Ankara University

Ayşe Sertcelik, M.D.

Professor of Pathology, Department of Pathology, Faculty of Medicine, Ankara University

Ilker Okten, M.D.

Professor of Thoracic Surgery, Department of Thoracic Surgery, Faculty of Medicine, Ankara University