

Strangulated Umbilical Hernia After Routine Barium Enema

M Nayar, S Ford, M Lombard

Citation

M Nayar, S Ford, M Lombard. *Strangulated Umbilical Hernia After Routine Barium Enema*. The Internet Journal of Gastroenterology. 2005 Volume 4 Number 2.

Abstract

We report a unusual case of strangulated umbilical hernia as a result of a routine barium enema performed for the investigation of iron deficiency anemia.

A 72 year-old female presented to our hospital with symptoms of exertional dyspnea, abdominal pain and altered bowel habit. Clinical examination revealed a reducible umbilical hernia. There was no past history of abdominal surgery. She was otherwise healthy. Preliminary investigation revealed a microcytic anemia (Hemoglobin 5.5 g/dL; MCV 59.7) with a low ferritin. Upper gastrointestinal endoscopy was normal and duodenal biopsies were within normal limits. A barium enema was done to exclude occult neoplasia as a cause for her anemia. Both the standard bowel preparation and the procedure were well tolerated. The radiological appearances of the barium enema showed the presence of diverticular disease and a possible rectal polyp. There was no terminal ileal reflux. No part of colon was present in the umbilical hernia. (Figures 1&2). Six hours following the barium enema, the patient complained of severe abdominal pain, nausea and vomiting. She was afebrile, tachycardic and appeared sick in. Abdominal examination revealed a large umbilical hernia which could not be manually reduced. It was very tender and bowel sounds were absent. Plain abdominal radiograph demonstrated dilated small bowel loops and a central density due to the umbilical hernia. Barium was present throughout the collapsed colon. (Fig 3). A clinical diagnosis of a probable large bowel lesion causing small bowel obstruction was made and patient was referred to surgery. Laparotomy revealed a 17 cm segment of ischemic small and large bowel with the small bowel incarcerated in a paraumbilical hernia with a very narrow neck. No adjacent vessels were palpable and therefore the segment was resected and the hernia reduced. There was no obstructing lesion seen intraoperatively. Post operatively she had a small bowel ileus which resolved spontaneously. Thereafter she made an uneventful recovery and was discharged home. She

continues to be in good health without any further complications.

Figure 1

Figure 1 : Barium enema (during procedure) – normal appearance

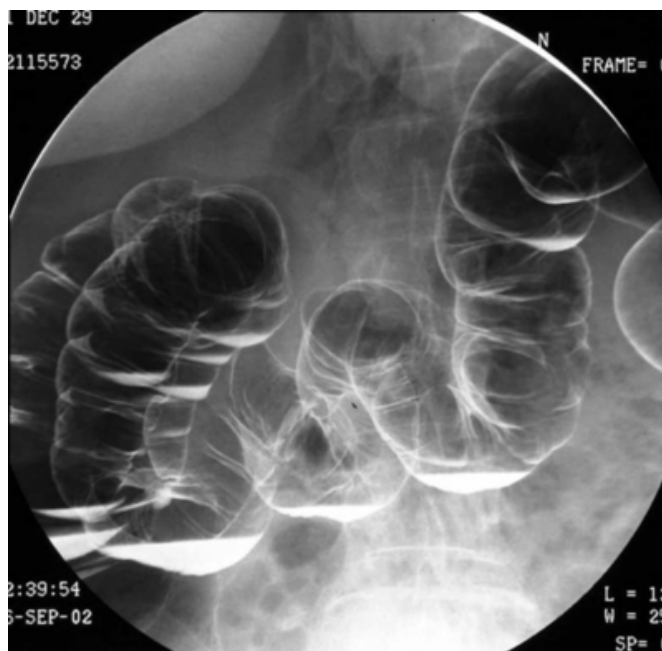


Figure 2

Figure 2: Barium enema (end of procedure) – normal appearance

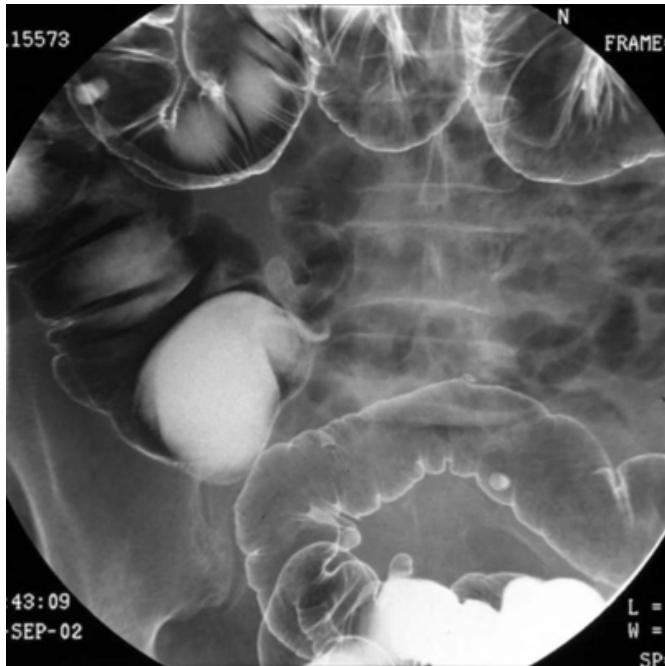
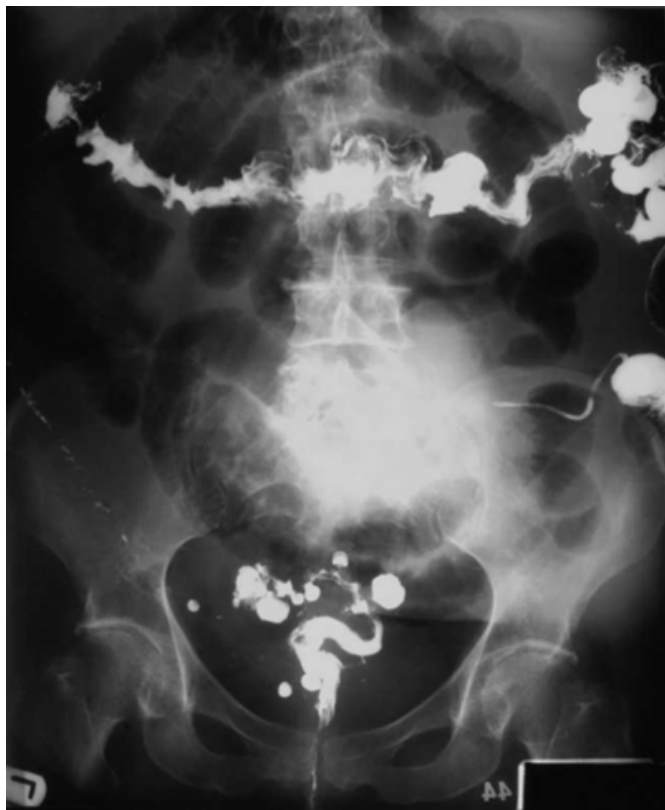

Figure 3

Figure 3: Plain abdominal x ray – small+large bowel dilatation



DISCUSSION

The most comprehensive survey of complications of barium enema was published in 1997 by Blakeborough and colleagues (1). They reported a serious complication rate of 0.01% with a mortality rate of approximately 0.002%. The common complications were intestinal perforation, barium impaction, accidental vaginal intubation, venous intravasation, allergy, septicaemia, acute appendicitis, rectal bleeding, septicaemia and cardiac arrhythmias. Arrhythmias and intestinal perforation were the most important causes of morbidity and mortality. Other series describe similarly low complication rates. Williams and Harned reported perforation in 0.02-0.04% of patients (2); Kewenter and Brevinge describe no complications in nearly 2,000 barium enemas performed for screening of colorectal cancer. (3)

To our knowledge the literature does not have a recorded case of strangulated umbilical hernia following barium enema. We think in our patient the barium enema precipitated the strangulation leading to bowel ischemia. Despite barium not being forced into the small intestine, the introduction of air may have raised intra-luminal pressure beyond which the hernia could be contained. Incarceration and strangulation of umbilical hernias occur both in children and adults. Spontaneous rupture of umbilical hernias may occur among patients with ascites and rarely in pregnant women. Mortality is around 5-6 % in patients who develop a strangulated umbilical hernia and elderly females with prolonged hospitalization have a poorer outcome. (4,5) We therefore suggest that barium enema should be performed cautiously in patients with large umbilical hernias to avoid potential bowel strangulation.

CORRESPONDENCE TO

Dr M Nayar 17, Druids Cross Road, Calderstones, Liverpool, L18 3EA United Kingdom Phone: +44 7841 575793 Fax: +44 (0)151 4261686 E-mail: nayarmanu@hotmail.com

References

1. Blakeborough A, Sheridan MB, Chapman AH. Complications of Barium Enema Examinations: A Survey of UK Consultant Radiologists 1992 to 1994. *Clinical Radiology* 1997; 52: 142-8.
2. Williams SM, Harned RK. Recognition and prevention of barium enema complications. *Current Problems in Diagnostic Radiology* 1991; 20 (4): 123-51.
3. Kewenter J, Brevinge H. Endoscopic and surgical complications of work-up in screening for colorectal cancer. *Diseases of the Colon and Rectum* 1996; 39 (6): 676-80.
4. Kulah B et al. Presentation and outcome of incarcerated external hernias in adults. *American Journal of Surgery* 2000; 181(2): 101-4.

5. Kulah B et al. Emergency hernia repairs in elderly patients. American Journal of Surgery 2001; 181(5): 455-9.

Author Information

M. Nayar

Department of Gastroenterology, Royal Liverpool University Hospital

S. Ford

Department of Gastroenterology, Royal Liverpool University Hospital

M. Lombard

Department of Gastroenterology, Royal Liverpool University Hospital