

Images in Neurology: Periodic Sharp Wave Complexes in patient with Creutzfeldt- Jakob Disease

N Sethi, P Sethi, J Torgovnick

Citation

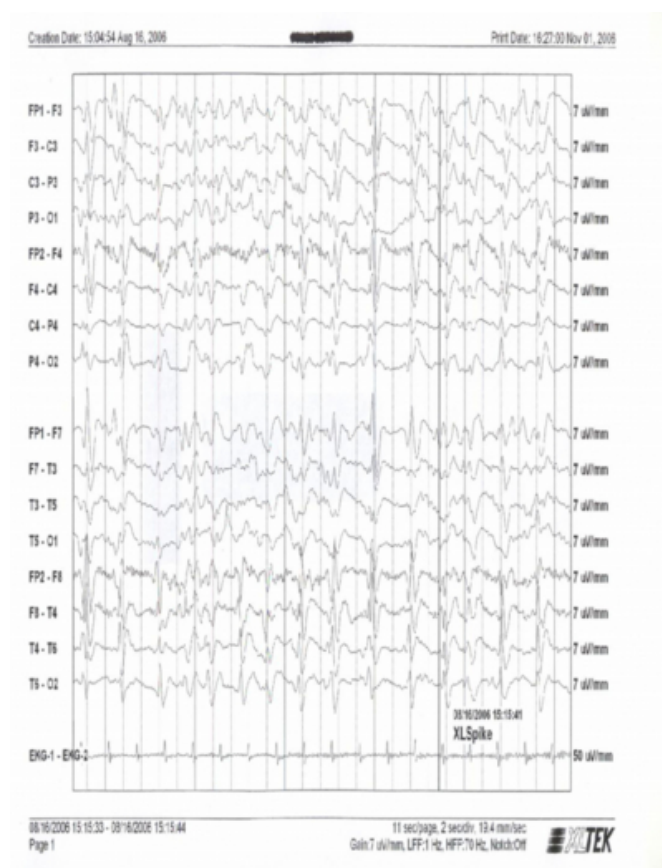
N Sethi, P Sethi, J Torgovnick. *Images in Neurology: Periodic Sharp Wave Complexes in patient with Creutzfeldt- Jakob Disease*. The Internet Journal of Neurology. 2006 Volume 7 Number 2.

Abstract

Creutzfeldt- Jakob disease (CJD) is included under the umbrella of prior related neurodegenerative diseases. Other prior related diseases include Gerstmann-Sträussler-Scheinker (GSS), fatal familial insomnia (FFI), Kuru and new variant CJD (BSE) in humans, chronic wasting disease (CWD) in deer and scrapie in sheep. Sporadic CJD presents with rapidly progressive dementia and myoclonus. Diagnosis is typically clinical and supplemented by electroencephalography (EEG) and analysis of cerebrospinal fluid. During the course of sporadic CJD, most patients develop a characteristic picture on EEG with one second periodic or pseudoperiodic sharp waves complexes (PSWC) or spikes superimposed on a slow background (Fig 1). The sensitivity and specificity of PSWC varies from 60% to 80 % on a single EEG recorded from a suspected patient of CJD. They may not be present on the initial EEG but as the disease progresses more than 90% of the patients show the characteristic periodic EEG abnormalities. No PSWC occur in EEG recordings of patients with new variant CJD .

Figure 1

EEG showing periodic sharp wave complexes (PSWC) in a patient with CJD.



CORRESPONDENCE TO

Nitin Sethi, MD Comprehensive Epilepsy Center Weill
Cornell Medical Center New York, NY 10021 Email:
sethinitinmd@hotmail.com

References

1. Wieser HG, Schindler K, Zumsteg D. EEG in Creutzfeldt-Jakob Disease. Clin Neurophysiol. 2006; 117(5):935-51.

Author Information

N.K. Sethi, M.D.

Weill Cornell Medical Center

P. K. Sethi, M.D.

Sir Ganga Ram Hospital

J. Torgovnick, M.D.

Saint Vincent's Hospital and Medical Centers