

Posterior cranial fossa extradural haematoma managed conservatively

B Jayathilaka, A Hussain, J Martin

Citation

B Jayathilaka, A Hussain, J Martin. *Posterior cranial fossa extradural haematoma managed conservatively*. The Internet Journal of Neurosurgery. 2008 Volume 6 Number 1.

Abstract

Posterior fossa extradural (PFED) uncommon but potentially fatal condition. Extradural haematomas in the posterior fossa is rare. Extradural haematoma are commonly associated with direct trauma to the temporal bones of the cranium resulting in damage to the middle meningeal artery or its branches. This case describes of an occipital skull fracture with venous sinus bleeding that resulted in a posterior cranial fossa extradural haematoma which was managed conservatively.

CASE REPORT

A 60 year old lady fell while walking on the beach and hit her head. She loss her consciousness but was fully conscious when she reached the local A&E. She was known to have hypertension, well controlled epilepsy for over past 20 years and she had undergone right carotid endarterectomy 2 years before. She was on aspirin 150mg at the time this injury. She was independent and mobile at the time of the injury.

She had a CT scan in her Local Hospital which showed a right occipital fracture and extra dural haematoma in the posterior fossa with no mass effect(Figure1,2)

She was immediately transferred to a regional neurosurgical unit for further evaluation and management. At the time of her arrival to the neurosurgical department her GCS was 15/15.

Since she was asymptomatic it was decided to manage her conservatively.

She was later discharged from the hospital with no residual neurological deficit and back to her usual functional level. Her antiplatelet drugs were withheld.

She was seen in the neurosurgical clinic 6 months after the initial trauma she was doing well no neurological deficit or fictional loss. She is able to walk unaided.

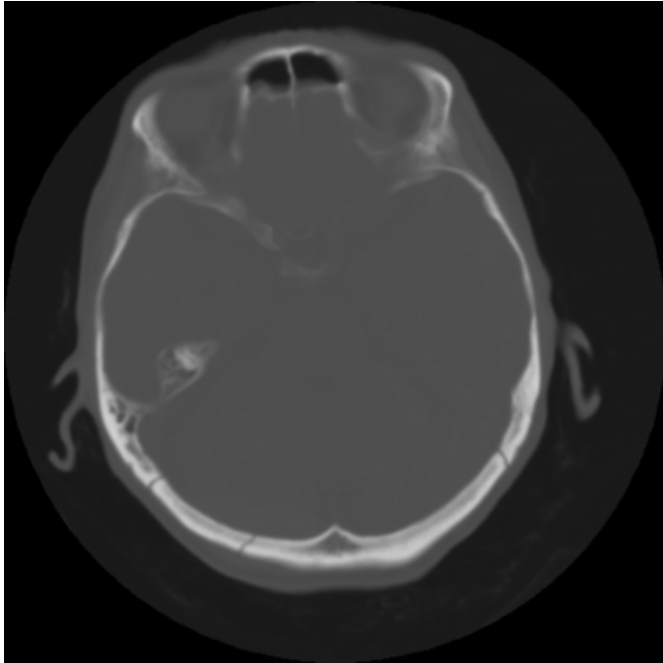
Figure 1

Figure 1

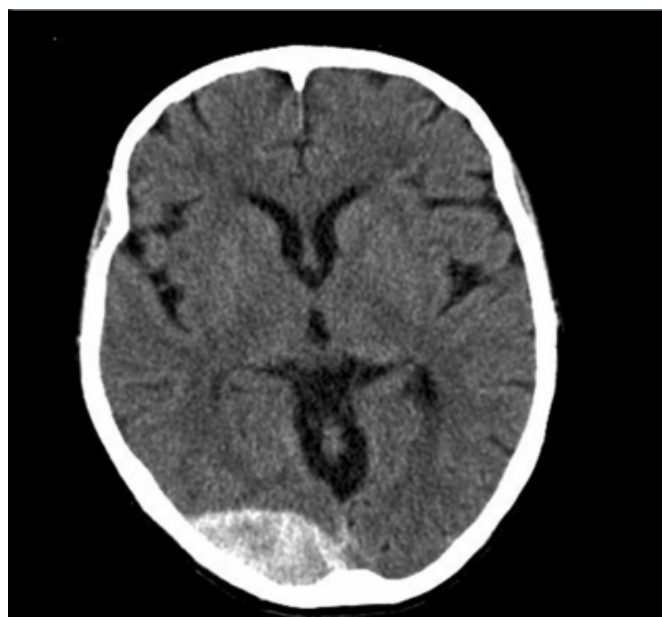

Figure 2

Figure 2



DISCUSSION

Posterior cranial fossa extradural haematomas account for 0.3% of all head injuries and 1.2% -10% of all extradural bleeds.¹²³ Posterior fossa extradural haematomas are difficult to diagnose and clinically silent, and symptoms are non-specific. Even before clinical findings exist, neuroradiologic findings appear.²⁴⁵ Hence, CT scan is of great importance in the diagnosis.⁴⁶

The new technological development has allowed early diagnosis and close monitoring of this condition. Natural history of the condition is variable patients can be initially stable but can rapidly deteriorated and go on to have respiratory arrest.⁷

Radiological evident fracture has been demonstrated in 86% of cases of proven extradurals though such bleeds may develop despite no demonstrable fracture.⁸ Posterior cranial fossa fracture in the presence of occipital trauma is of paramount significance. In such patients serious complications develop in 33% of patients compared with 7%

of those without a fracture.⁹

This patient had a demonstrable fracture in the occipital area. (Figure 2). The likely cause of the posterior fossa haemorrhage in this patient is bleeding from the venous sinuses (trucula).

Conservative management has been demonstrated in the literature in the past after invention and wide use of CT scans.¹⁰ The decision to operate on patient with posterior fossa extradural haematoma is based on the mass effect of the haematoma.¹¹ If there is no mass effect from the haematoma patients can be managed conservatively. This will avoid patients exposure to anaesthetic and operative risk. In the long term it may be cost effective

References

1. Boiten J. Epidural haematoma of the posterior fossa: good results after prompt diagnosis with CT. *J Neurol Neurosurg Psychiatry* 1989;52:914–15.
2. Bozbuga M, Izgi N, Polat G. Posterior fossa epidural hematomas: observations on a series of 73 cases. *Neurosurg Rev* 1999;22:34 – 4
3. Bullock MR, Chesnut R, Ghajar J. Surgical Management of Traumatic Brain Injury Author Group: surgical management of posterior fossa mass lesions. *Neurosurgery* 2006;58[[[3 Suppl]]]:47 - 55.
4. Dirim BV, Oruk C, Erdogan N. Traumatic posterior fossa hematomas. *Diagn Interv Radiol* 2005;11[[[1]]]:14 - 8.
5. Neubauer UJ. Extradural haematoma of the posterior fossa. Twelve years experiences with CT-scan. *Acta Neurochir [[Wien]]* 1987;87:105 - 11.
6. Holzschuh M, Schuknecht B. Traumatic epidural haematomas of the posterior fossa: 20 new cases and a review of the literature since 1961. *Br J Neurosurg* 1989;3:171 - 80.
7. Garza-Mercado R. Extradural haematoma of the posterior cranial fossa. *J Neurosurg* 1983;59:664–72
8. Koc RK, Pasaoglu A, Menku A, et al. Extradural haematomas of the posterior cranial fossa. *Neurosurg Rev* 1998;21:52–7.
9. Fisher RG, Kim JK, Sachs E. Complications in posterior fossa due to occipital trauma—their operability. *JAMA* 1958;167:176–82
10. Pozatti E, Tognetti F, Cavallo M. Extradural hematomas of the posterior cranial fossa. Observations on a series of 32 consecutive cases treated after the introduction of computed tomography scanning. *Surg Neurol* 1989;32:300 - 3.
11. Aykut Karasu, MD, Pulat Akin Sabanci, MD4, Nail Izgi, MD, Murat Imer, MD, Altay Sencer, MD, Tufan Cansever, MD, Ali Canbolat, MD. Traumatic epidural hematomas of the posterior cranial fossa. *Surgical Neurology* 69 [[[2008]]] 247– 252

Author Information

B.R.G. Jayathilaka

Morrison Hospital Neurosurgical Department

A.R. Hussain

Morrison Hospital Neurosurgical Department

J.L. Martin

Morrison Hospital Neurosurgical Department