

Hydroxyapatite Granules For Mastoid Cavity Obliteration: A Study Of 25 Cases

M Munjal, J Passey, A Agarwal, R Meher

Citation

M Munjal, J Passey, A Agarwal, R Meher. *Hydroxyapatite Granules For Mastoid Cavity Obliteration: A Study Of 25 Cases*. The Internet Journal of Otorhinolaryngology. 2004 Volume 3 Number 2.

Abstract

Standard surgery for atticotranal disease is modified radical mastoidectomy, which results in open cavity problems mainly debris, discharge, dizziness and dependence on the surgeon for cleaning the cavity at regular intervals. In this study of 25 patients (age 5-60), porous hydroxyapatite, which is an osteogenic bone analogue, was used to achieve reduction in mastoid bowl size and decrease cavity problems. To prevent extrusion, an inferiorly based periosteal flap was devised. Complete epithelization with absence of discharge in 21 (84%) cases with no other cavity problems was reported. An average (2.04dB) shortening of AB gap was also noted.

INTRODUCTION

In spite of the now universal use of microscopes and other advanced surgical instruments in the management of atticotranal disease modified radical mastoidectomy results in cosmetically unacceptable open cavity along with problems of chronic discharge (20-60%) deafness, dizziness and dependency on the otologist for cleaning of ear and ultimately desperation to be free of the problem.

Amongst all surgical options available including usage of epithelial grafts, large meatoplasty, revision mastoidectomy and obliteration, the last seems to be the most appropriate as it addresses all the problems at the same time.

With the incredible success of hydroxyapatite reported when used as a bone graft in orthopaedics, an attempt was made to repeat a similar kind of achievement in mastoid cavity obliteration because of its useful osteogenic/osteoconductive nature in terms of bone integration.

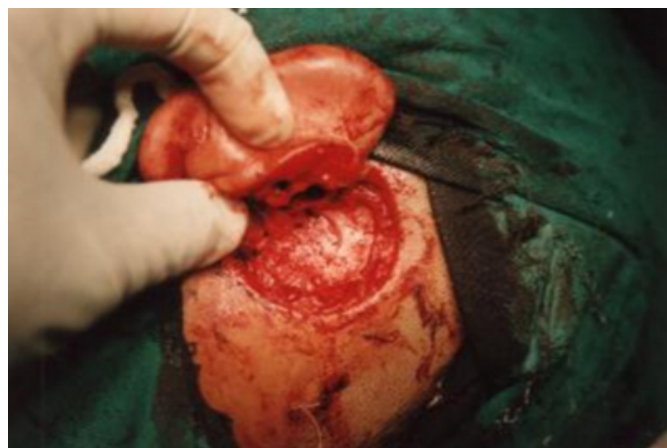Figure 1

Figure 1: Commercially available hydroxyapatite crystals and block




Figure 2

Figure 2: Mastoid obliteration with hydroxyapatite.



MATERIAL AND METHODS

A randomized trial of 25 patients of either sex less than 60 years of age having atticotympanic type of disease without any history of intracranial complication were included in the study.

All the patients underwent initially modified radical mastoidectomy under general anaesthesia. An inferiorly based periosteal flap was then devised near the tip of mastoid process. Porous hydroxyapatite granules obtained by crushing commercially available hydroxyapatite blocks ($0.5 > 1$ cm) were dipped in antibiotic solution (Co-amoxycylav) for 10 minutes and then filled into the cavity completely and covering the lateral semi-circular canal. The epitympanum was not obliterated. The inferiorly based periosteal flap was then rotated into the mastoid cavity to cover the granules and over it dry temporalis fascia was inserted to line the eardrum. Final packing with ointment-impregnated gauze was done.

All the patients were put on I/V, antibiotics, decongestants and painkillers in the post operative follow up for 10 days after which the pack was removed.

The patients were followed up in the OPD on 15th, 30th, 45th, 60th, 90th, 180th day and then 6 months and 1 year post operatively. The parameters for study included pain, discharge, granule extrusion, dizziness, epithelization rate, debris and other complications.

OBSERVATIONS AND RESULTS

Figure 3

Symptoms	Pre Op	Post Op					
		Day 7	Day 15	Day 30	Day 45	Day 90	Day 180
Discharge	100%	8%	52%	54%	40%	12%	12%
Ab gap	27.9 dB	NA	NA	NA	NA	NA	25.8 dB
Pain	32%	20%	0	0	0	0	0
Extrusion	-	8%	20%	16%	4%	4%	0
Dizziness	0	0	0	0	0	0	0
Debris	0	0	0	0	0	0	0
Epithelization	-	0	0	0	88%	88%	88%

Percentage denotes the number of cases included in the study and AB gap denotes the pre-op and post-op audiometry findings

Epithelization denotes the first sign of appearance of cavity epithelium seen on otoscopic examination.

It was noted that majority of patients were in age group 11 to 20, i.e. 72% of the total. While 8 (32%) patients complained of the occurrence of dull earache, all patients complained of foul smell discharge, 13(52%) had h/o mucopurulent discharge while 21(84%) gave h/o scanty discharge. Almost all patient gave h/o subjective decrease in hearing, 18 (72%) reported average gap 20-30 dB, while 7(28%) had an average gap of 30-40 dB. As for the pathology 5 (20%) patients had frank cholesteatoma, 15 (60%) had granulations and 5 (20%) patients had both.

There was no major complications reported intraoperatively as well as post operatively while in 2 (8%) cases, the post aural pack had to be removed due to formation of aural hematoma/abscess in 3(12%). There were minor problems in form of stitch abscesses or collections that were drained without removal of pack.

By 90th day 4 (16%) cases reported better hearing up to 10-20 dB, and also minor increase (5 dB) in 9 (36%) patients, 11 (44%) patients did not report any improvement in hearing. 6 (24%) also reported decreases in hearing. The average AB gap gain was a minor 2.04 dB.

DISCUSSION

With the evolution of Modified Radical Mastoidectomy in the past century of surgical development, Mastoidectomy Elimination techniques have come to the forefront.

Diverse materials and techniques have been used including fat and blood clots (1906-1922), which caused infection and resorption. Flaps have been more popular (Mosher 1911) but suffer from hematoma formation, infective abscesses, flap necrosis, granulations etc. Auto cartilage and bone leads to resorption and atrophy, not to forget the donor site morbidity [1,4,5,6].

In order to satisfy all the requirements and at the same prevent the above problems, the needs to search for an ideal bone replacement graft arose with following main questions in mind:

- Is it acceptable to the host?
- Will it survive in presence of infection?
- Is there adequate blood supply to nourish the tissue?
- Will it obliterate the cavity permanently?

Out of various synthetic materials commercially available today for e.g. Ionomer cement, silicone proplast and calcium phosphate ceramics, porous hydroxyapatite ($\text{Ca}_{10}(\text{PO}_4)_6(\text{OH})_2$) has been found to be ideal for cavity obliteration/canal wall reconstruction. The material in synthetic form has a macroporosity of 30% with a pore size of 3M. 65-70% osseous component is organic, principal component being hydroxyapatite.

With respect to properties, it has been found that hydroxyapatite biomaterials are osteoconductive but are not intrinsically osseousinductive. This material is highly biocompatible, but cannot accept rigid material fixation hardware. With evidence of denovo woven bone formation with in the pores of the graft, it may be called osteogenic under certain conditions [1,2].

Previous studies using muscle flaps have reported complete epithelization rates of around 83% after 90 days whereas in our study, because of the resistance properties and porous nature of the material, results is excellent biocompatibility with the host bone and gives a bioactive lining on which epithelium can regenerate. High rate of complete epithelization 22 (88%) with or without presence of discharge was noted.

Similar results have been obtained using bone pate [4] but by using the same diseased bone for obliteration, one cannot overlook the increased chances of recurrence of disease.

There is no doubt regarding the fact that the cost of material is significantly higher as compared to the other techniques, however the benefits do outweigh the costs in terms of decreased morbidity and patient satisfaction. It saves on considerable time in the operative technique as minimal or no meatoplasty is required. Also there is no element of donor site morbidity or disease recurrence in the cases done.

CONCLUSION

The study supports the use of hydroxyapatite as a suitable biomaterial to obliterate mastoid cavities. Along with stable reduction in mastoid bowl size, the use of inferiorly based periosteal flap promotes epithelization and prevents extrusion of granules. There is no element of donor site morbidity as compared to the other techniques of harvesting bone tissue.

CORRESPONDENCE TO

Dr Manish Munjal 19-D, Pocket-III, Mayur Vihar, Phase-I, Delhi-110091 Ph 011-35999878 E mail-
may2manish@rediffmail.com, meherravi@hotmail.com

References

1. Black B: Mastoidectomy elimination. Laryngoscope, 105: 1-30,1995.
2. Daculsi G: Macro porous bi phasic calcium phosphate efficiency in mastoid cavity obliteration: Experimental and clinical findings. Ann Otol Rhinol Laryngol, 101: 669-674,1992.
3. Jahn F.A.: Experimental applications of porous (coralline) hydroxyapatite in middle ear and mastoid re-construction. Laryngoscope, 102: 289-299,1942.
4. Moffat D.A, Irving R.M: Mastoid obliteration using bone pate. Otolaryngol, 19:149-157,1994.
5. Palva A.T: Surgery of chronic ear without cavity. Arch Otolaryngol, 77: 570-580,1963.
6. Robinson J.M Moffat D.A: Mastoid Reconstruction and Obliteration. Yearbook of ENT, 6:87-98,1996.
7. Yung M W: The use of hydroxyapatite granules in mastoid obliteration. Clin Otolaryngol, 21: 480-484,1996.

Author Information

M. Munjal

Senior resident, Department of Otolaryngology and Head and Neck Surgery, Maulana Azad Medical College and associated Lok Nayak, G.B Pant and GNEC hospitals

J. Passey

Professor, Department of Otolaryngology and Head and Neck Surgery, Maulana Azad Medical College and associated Lok Nayak, G.B Pant and GNEC hospitals

A.K. Agarwal

Director, Professor, and Head, Department of Otolaryngology and Head and Neck Surgery, Maulana Azad Medical College and associated Lok Nayak, G.B Pant and GNEC hospitals

R. Meher

Senior resident, Department of Otolaryngology and Head and Neck Surgery, Maulana Azad Medical College and associated Lok Nayak, G.B Pant and GNEC hospitals