

Primary Duodenal Lymphoma presenting as Obstructive Jaundice

S Rahman, E Reyes, A Mehta, Z Virk, J Gintautas, J Cervantes

Citation

S Rahman, E Reyes, A Mehta, Z Virk, J Gintautas, J Cervantes. *Primary Duodenal Lymphoma presenting as Obstructive Jaundice*. The Internet Journal of Gastroenterology. 2008 Volume 7 Number 2.

Abstract

Although the gastrointestinal (GI) tract is the most prominent site of extra nodal lymphoma, primary duodenal lymphoma is very atypical. Furthermore, obstructive jaundice is a very rare presenting symptom of Non-Hodgkin Lymphoma (NHL). Here we present a case of a 57-year-old, previously healthy male who presented to the emergency room with jaundice, dark yellow urine and abdominal pain. Computed Tomography (CT) scans of the abdomen and pelvis revealed a 7cm, ill-defined mass in the pancreatic head region with involvement of the adjacent duodenum, peri-pancreatic adenopathy and mild biliary duct dilatation. After no response from percutaneous drainage and radiation therapy, chemotherapy was successfully employed. After 8 months of follow-up, the patient remained in remission. Early and accurate diagnosis of this illness is important for positive prognosis; this case illustrates that jaundice, though rare, can be a presenting symptom of duodenal lymphoma.

INTRODUCTION

Presentation of primary duodenal lymphoma is variable and depends on the location and degree of obstruction. Although the gastrointestinal (GI) tract is the most prominent site of extra nodal lymphoma, primary GI lymphoma constitutes a small amount of all cases¹. Furthermore, primary duodenal lymphoma is an exceedingly uncommon type of GI lymphoma^{2,3,4}. Obstructive jaundice has very rarely been documented as a presenting symptom of any type of non-Hodgkin's lymphoma (NHL)^{5,6,7,8}. Reoccurrence and morbidity are typical in cases of lymphoma even after radiation therapy, chemotherapy, or surgery^{3,9,10}. In our case, we describe a patient with primary duodenal lymphoma who presented initially with jaundice to our clinic and who was successfully treated with chemotherapy after insufficient response to percutaneous drainage and radiation therapy.

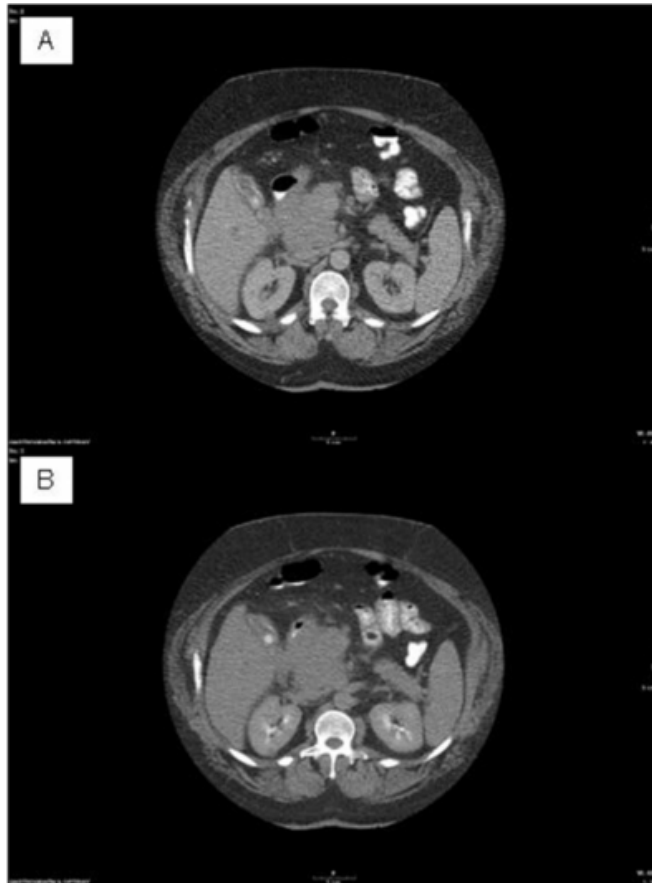
CASE REPORT

A 57-year-old, previously healthy male presented to our clinic with jaundice, dark yellow urine and abdominal pain. Physical examination was unremarkable except for obesity, icteric sclera and mild right upper quadrant tenderness. His hematological profiles on the day of his admission were normal. Serum biochemistry results included aspartate transaminase of 234U/L, alanine transaminase of 230U/L, alkaline phosphatase of 530U/L, and total bilirubin of 6.7

mg/dl as well as conjugated bilirubin 3.6mg/dl, which suggest obstructive jaundice. Other serum electrolytes were within normal limits. Hepatitis profile was negative. Computed Tomography (CT) scan of the abdomen and pelvis were performed with contrast. It revealed a large 7cm, ill-defined mass in the pancreatic head region with involvement of the adjacent duodenum, peri-pancreatic adenopathy and mild biliary duct dilatation (see Figures 1 A and B).

Figure 1

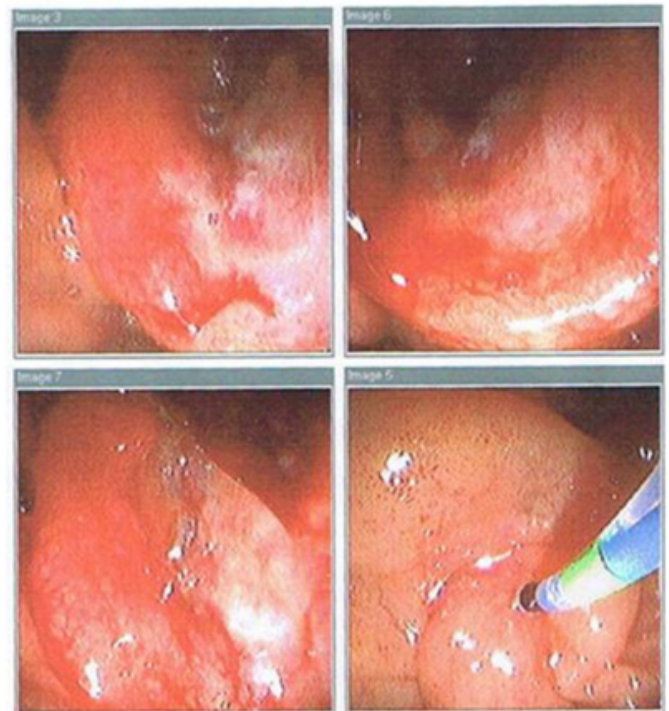
Figures 1 A and B: CT scan (with contrast) of the abdomen and pelvis revealing 7cm, ill-defined mass in the pancreatic head region with involvement of the adjacent duodenum, peri-pancreatic adenopathy and mild biliary duct dilatation.



Endoscopy of the upper gastrointestinal tract revealed a large, 2 x 3 cm ulcerated mass in the duodenum, proximal to the ampulla arising from the apex of the duodenal bulb and extending to the second portion of the duodenum (see Figure 2). Multiple biopsies were taken; results revealed atypical large cell lymphoid infiltrate. The tumor cells had round to occasionally irregular nuclei with one or more nucleoli (see Figure 3). Tumor cells expressed CD20, PAX-5, BCL-2 and BCL-6 and were interpreted as diffuse large B-cell lymphoma.

Figure 2

Figure 2: Endoscopy of the upper gastrointestinal tract revealing 2 x 3 cm ulcerated mass in the duodenum, proximal to the ampulla arising from the apex of the duodenal bulb and extending to the second portion of the duodenum.



The patient initially underwent percutaneous drainage for obstructive jaundice, after which he began radiation therapy; radiation therapy was not effective. R-CHOP (rituximab-cyclophosphamide, doxorubicin, vincristine and prednisone) chemotherapy was started. The patient received a total of 6 cycles of chemotherapy. He was followed by the attending oncologist for 8 months without an occurrence of relapse. Some chemotherapy-induced complications were observed including agranulocytosis, septic shock, and aureas infection, which were all successfully managed.

DISCUSSION

PRESENTATION AND DIAGNOSIS

The majority of patients with gastrointestinal lymphoma present with vomiting, abdominal pain, weight loss, and fever¹⁰. Few cases to date have been presented in the English language literature that describes cases of primary gastrointestinal, particularly primary duodenal^{5,6,7,8}, lymphoma presenting as jaundice.

In order to diagnosis primary GI tract lymphoma, the following criteria need to be met: 1) absence of palpable superficial lymphadenopathy; 2) absence of enlargement of

mediastinal lymph nodes on chest x-ray; 3) normal leukocyte and differential counts; 4) predominance of alimentary tract lesions with only regional lymph node involvement; and 5) absence of tumor involvement of the liver and spleen. Our case fulfilled all of the above criteria⁸. There are various mechanisms that have been proposed as causes of development of obstructive jaundice¹¹. These include diffuse infiltration of the liver by lymphoma, granulomatosis hepatitis, intrahepatic cholestasis, primary hepatic lymphoma, obstruction of the extra hepatic ducts by involved portal nodes, or toxic hepatitis caused by drug treatment. In our case, obstructive jaundice was caused by the compression of the common bile duct by the enlarged malignant lymph nodes.

TREATMENT AND PROGNOSIS

Literature suggests that chemotherapy may be the most successful treatment for primary GI tract lymphoma cases and that the need for surgical removal of affected areas is not always necessary for, nor guarantees, patient recovery^{3,10,12}. Furthermore, percutaneous drainage may be indicated and can be followed by radiation therapy, chemotherapy, or surgery if necessary. As previously noted, mortality is a common outcome of GI lymphoma, either from the illness itself or complications from therapy⁹. Even with therapy, GI lymphoma can result in death. Early diagnosis and treatment of the disease will help to ensure the best outcome for the patient.

Though percutaneous drainage was performed in our case, there was a need for continued therapy for remission. Radiation therapy was begun after drainage, but was also unsuccessful. Chemotherapy resulted in remission in our patient with no relapse during his 8 months of follow-up. The patient requires continuous follow-up to screen for re-occurrences of the disease.

This case underscores the importance of the physician to be alert of the possibility of duodenal lymphoma when evaluating a patient with obstructive jaundice. Though it is a

rare presentation of the illness, this differential diagnosis is important for precise and timely diagnosis of the patient and commencement of the appropriate treatment.

CORRESPONDENCE TO

Dr. Jonas Gintautas, MD, PhD, MBA Department of Clinical Research Jamaica Hospital Medical Center 8900 Van Wyck Expressway Residency Suite 7M Jamaica, NY, 11418l (p) 718.206.5800 (f) 718.206.5805 (e) kcervell@jhmc.org

References

1. Crump M, Gospodarowicz M, Shepherd FA. Lymphoma of the gastrointestinal tract. *Semin Oncol* 1999; 26:324-337.
2. Shibata Y. Primary malignant lymphoma of the duodenum: Report of a case. *Hepatogastroenterology* 1998;45:2171-2174.
3. Yoshino T. Increased incidence of follicular lymphoma in the duodenum. *Am J Surg Pathol* 2000;24:688-693.
4. Papaxoinis G, Papageorgiou S, Rontogianni D, et al. Economopoulos T. Primary gastrointestinal non-Hodgkin's lymphoma: a clinicopathologic study of 128 cases in Greece. A Hellenic Cooperative Oncology Group study (HeCOG). *Leuk Lymphoma* 2006;47:2140-2146.
5. Najem AZ, Porcaro JL, Rush BF. Primary Non-Hodgkin's lymphoma of the duodenum: Case report and literature review. *Cancer* 1984;54:895-898.
6. Schoeppner HL, Wong DK, Bresalier RS. Primary small bowel lymphoma manifested as obstructive jaundice in a patients with AIDS. *South Med J*. 1995;5:583-585.
7. Yildirim N, Oksuzoglu B, Budakoglu B, et al. Primary duodenal diffuse large cell non-Hodgkin lymphoma with involvement of ampulla of Vater: report of 3 cases. *Hematology* 2005;10:371-374.
8. Ugur H, Tacyildiz N, Yavuz G, et al. Obstructive jaundice: an unusual initial presentation of intra-abdominal non-Hodgkin lymphoma in a child. *Pediatr Hematol Oncol* 2006;23:87-90.
9. Kosits C, Callaghan M. Rituximab. A new monoclonal antibody therapy for non-Hodgkin's lymphoma. *Oncol Nurs Forum* 2000;27:51-59.
10. Cunningham J, Aleali R. Advances in surgical technique. *Ann Surg* 1997;225:300-306.
11. Dawson IMP, Cornes JS, Morson BC. Primary malignant lymphoid tumors of gastrointestinal tract: Report of 37 cases with a study of factors influencing prognosis. *Brit J Surg* 1961;49:80-89.
12. Raina V, Sharma A, Vora A, et al. Primary gastrointestinal non Hodgkin's lymphoma chemotherapy alone an effective treatment modality: experience from a single centre in India. *Indian J Cancer* 2006;43:30-35.

Author Information

Shafiqur Rahman, MD

Department of Internal Medicine and Clinical Research, Jamaica Hospital Medical Center

Eduardo Reyes, MD

Department of Internal Medicine and Clinical Research, Jamaica Hospital Medical Center

Asit Mehta, MD

Department of Internal Medicine and Clinical Research, Jamaica Hospital Medical Center

Zahid Virk, MD

Department of Internal Medicine and Clinical Research, Jamaica Hospital Medical Center

Jonas Gintautas, MD

Department of Internal Medicine and Clinical Research, Jamaica Hospital Medical Center

Jose Cervantes, MD

Department of Internal Medicine and Clinical Research, Jamaica Hospital Medical Center