

# Paraganglionoma of ureter

P Kumar, K Natarajan, P Hegde

## Citation

P Kumar, K Natarajan, P Hegde. *Paraganglionoma of ureter*. The Internet Journal of Urology. 2009 Volume 7 Number 1.

## Abstract

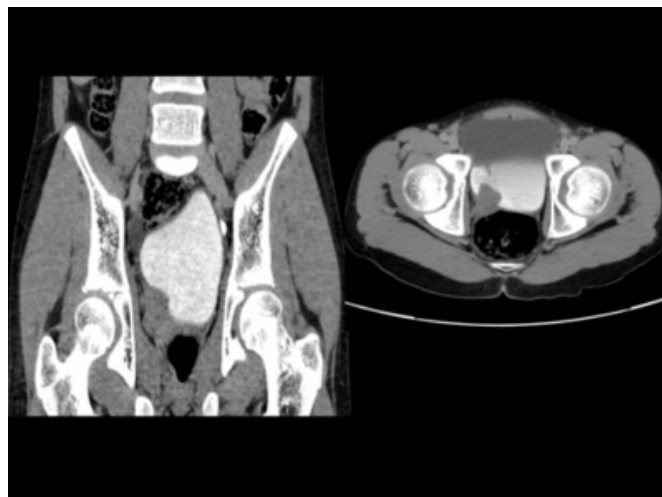
Paraganglioma of the retroperitoneum is not uncommon <sup>(1)</sup>. In the genitourinary tract it usually occurs in the bladder and prostate <sup>(1, 2)</sup>. Here in we present a case of ureteric paraganglioma, to our knowledge this has not been reported in literature.

## CASE REPORT

A 12 yr male child presented with history of gross painless hematuria – 2 episodes in last 2 months. No other complaints. Examination was uneventful. Sonography revealed Right hydroureteronephrosis with 4 x 3 cm echogenic mass lesion in right lower ureter extending into bladder. Left kidney and rest of the bladder was normal. Urine cytology was negative. Contrast enhanced CT scan showed 4x4 cm enhancing mass lesion in lower ureter with extension into the bladder (Fig 1). No obvious regional lymphadenopathy. Cystoscopy showed mass lesion protruding from right ureteric orifice and left ureteric orifice and bladder was normal. Resection biopsy done which showed – packed nests of polygonal to ovoid cells with abundant eosinophilic cytoplasm anisonucleosis arranged in Zell ballen patterns, Grimelius stain shows few cytoplasmic brown black granules in few of the well preserved tumor cells, tumour cells were positive for chromogranin ,suggestive of paraganglioma(Fig 2). Retrospectively, urinary VMA was done which was normal. Patient underwent wide excision of the mass with right ureteric reimplantation. Histopathology and immuno cytochemistry was consistent with paraganglionoma. There is no recurrent at one year of follow up.

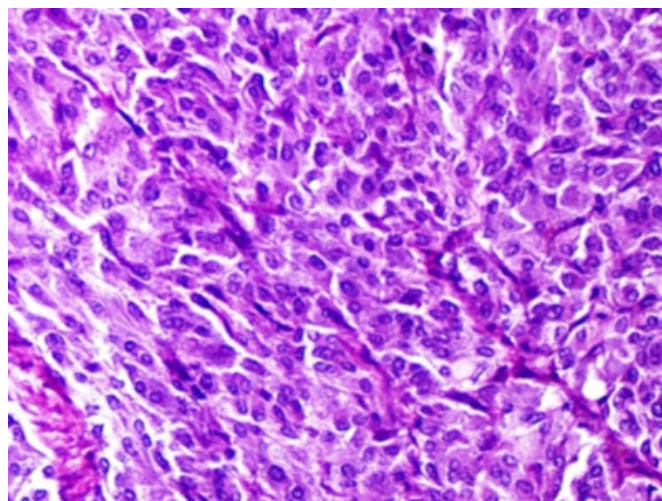
**Figure 1**

Figure 1 – Juxta Vesical mass with protrusion in to bladder



**Figure 2**

Figure 2 – High power microscopy showing Zell ballen patterns



## **DISCUSSION**

Paraganglioma thought to arise from extra adrenal chromaffin cells, usually originates from sympathetic, parasympathetic system or parasympathetic ganglia<sup>(2)</sup>. Those arising from parasympathetic ganglia are found in head and neck region, such as carotid bodies. Tumors arising from sympathetic ganglia are hormonally active and arise in the retroperitoneum. Retroperitoneal paraganglioma are 60% functional tumors. Paraganglioma in relation to genitourinary tract is known to occur in kidney, bladder, prostate, urethra and spermatic cord<sup>(4)</sup>. Mostly they present in adults rarely reported in Pediatric<sup>(3)</sup>. Paraganglioma of urinary system is uncommon<sup>(4)</sup>. Paraganglioma in bladder (10% of the extra adrenal) commonly occurs in trigone and dome. It is usually hormonally inactive<sup>(4, 6)</sup>. In biopsy it is characterized with organoid nests and trabeculae of polygonal cell with Zellballen formation, central nucleus with peppery chromatin, abundant granular cytoplasm, it may be misinterpreted as transitional carcinoma of bladder<sup>(6)</sup>. In familial syndromes it may be multifocal. This may be misinterpreted as metastatic lesion. But ureteric paraganglioma has not yet been described. These

Paraganglioma may be malignant but could be proved only by their clinical behavior rather than histological feature. The treatment of choice for these paragangliomas is surgical excision. R T may be an option. These patients require long follow-up since this known to occur at other sides and chance of multifocality in familial syndromes.

## **References**

1. Boyle M, Gaffney EF, Thurston A. Paraganglioma of the prostatic urethra: a report of three cases and a review of the literature. *Br J Urol* 1996;77:445–448
2. Dennis PJ, Lewandowski AE, Rohner TJ Jr, Weidner WA, Mamourian AC, Stern DR. Pheochromocytoma of the prostate: an unusual location. *J Urol* 1989;141:130–132
3. Voges GE, Wippermann F, Duber C, Hohenfellner R. Pheochromocytoma in the pediatric age group: the prostate—an unusual location. *J Urol* 1990;144:1219–1221
4. Cheng L, Leibovich BC, Cheville JC. et al. Paraganglioma of the urinary bladder: can biologic potential be predicted?. *Cancer* 2000;88:844–852.
5. Hasselager T, Horn T, Rasmussen F. Paraganglioma of the prostate: a case report and review of the literature. *Scand J Urol Nephrol* 1997;31:501–503
6. Anil V. Parwani, Dengfeng Cao, Jonathan I. Epstein. Pathologic Quiz Case: A 35-Year-Old Man With Hematuria Archives of Pathology and Laboratory Medicine: Vol. 128, No. 8, pp. e104–e106.

**Author Information**

**P.B Barani Kumar, MS, MCh**

Associate professor, Division Of Urology, Kasturba Medical College

**K. Natarajan, MS, FRCS (EDIN), FRCS (IRE), DNB, MCh**

Professor, Division Of Urology, Kasturba Medical College

**Padmaraj Hegde, MS, MCh**

Professor, Division Of Urology, Kasturba Medical College