

Hugely Recurrent Papillary Thyroid Carcinoma

P Floros, R Grigg

Citation

P Floros, R Grigg. *Hugely Recurrent Papillary Thyroid Carcinoma*. The Internet Journal of Otorhinolaryngology. 2010 Volume 13 Number 1.

Abstract

Recurrent papillary carcinoma of the thyroid either locoregional or distant metastasis is not uncommon with some studies reporting rates of up to 8.3% after average follow up of 8 years. Although not uncommon, there have been few reported cases on hugely recurrent thyroid carcinoma. Tomisawa et al., reports one case of a giant recurrent papillary carcinoma measuring 10cm in size and discusses the role of Mohs chemosurgery on local control. There have been reports however describing surgical resection/debulking for local control of hugely recurrent papillary carcinoma. Furthermore although studies have somewhat elicited risk factors for recurrence after resection of papillary carcinoma, there are limited studies on predictive factors for hugely recurrent thyroid disease. We present here a case of hugely recurrent papillary carcinoma in a Fijian lady who underwent initial subtotal thyroidectomy and subsequent near total thyroidectomy 10 years following initial surgery and tumour debulking 15 years from the initial surgery.

CASE REPORT

A 55 year old Fijian lady was referred to an ENT specialist in Toowoomba, Australia for advice and management of locally advanced recurrent thyroid papillary carcinoma. She was first seen in a small Fijian hospital in 1995 for some neck swelling and subsequently underwent a subtotal thyroidectomy. Histology at that time is unavailable. In 2005 she represented to Lautoka hospital, Fiji with recurrent neck swelling which had been present for 2 years. FNA of the lesion showed pathology consistent with a papillary lesion. She was subsequently admitted to Lautoka hospital (Lautoka, Fiji) from 31st January 2005 to the 14th of February 2005 and underwent a near total thyroidectomy.

Intraoperative findings indicated tumour invasion of the trachea and outer layer of oesophagus, enlarged bilateral cervical lymph nodes, invasion of tumour involving the carotid sheath and internal jugular vein near the sternal notch and a small tumour emboli in the internal jugular notch. Histopathology confirmed papillary carcinoma with lymphovascular invasion. She was reported to have hypertension during this admission and postoperatively commenced on thyroxine. She received follow up in the surgical clinic.

In 2009, the patient represented to the surgical clinic at the Colonial War Memorial hospital (Suva, Fiji) for recurrent

local disease. She failed to return for prompt review when recurrent neck swellings were first noticed in 2007, two years following her second operation. Clinically in addition to a change in the quality of her voice from prior surgery, she reported regular forceful clearing of her larynx. She denied any shortness of breath and Pemberton's sign was negative. She reported no difficulty in swallowing. The neck masses at this time measured 19 X 12cm on the right and 17 X 9cm on the left (Figure 1). CT with contrast reported multiple nodular masses of soft tissue density and septated in nature along with encapsulated cystic masses bilaterally in the neck region. The superior extent of these was noted at C1/C2 on the right while inferiorly extension to the right sterno-clavicular joint was noted. The trachea was compressed and displaced to the left (Figure 2). A serum TSH was measured at 2.28µIU/mL and in conjunction with CT radiological findings, recurrence of Thyroid Papillary Carcinoma was suggested. She was subsequently referred to an ENT surgeon in Toowoomba (Queensland, Australia) for debulking of the tumour mass.

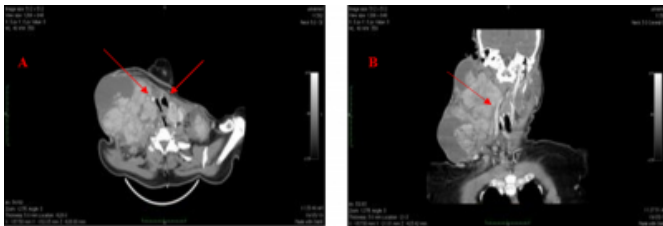
Figure 1

Figure 1: Front on view of patient showing significant bilateral neck swelling (A). Right lateral view of largest neck lump, notice skin discolouration as indicated by arrow (B).

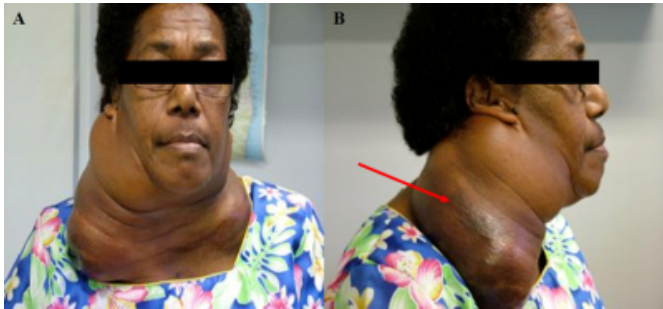

Figure 2

Figure 2: An axial CT showing large heterogenous (cystic/solid) mass of the right thyroid with compression of the trachea medially and shifting of the carotid artery anteromedially as indicated by the arrows (A). Coronal section of the same thyroid tissue showing large mass in the right lobe and smaller mass of the left lobe. Notice the obliteration of the fat plane between carotid artery and thyroid tissue superiorly on the right as indicated by arrow, suggesting invasion of the carotid sheath (B).



On the 23rd of March, 2010 she proceeded to surgery and underwent debulking of recurrent tumour. The operation was a two stage procedure with debulking of the right neck initially. Intraoperatively a mass measuring 1352 grams with tumour measuring 205 X 175 X 170mm multinodular with cystic areas and areas of haemorrhage was removed from the right neck. The tumour also appeared slightly pigmented. Histology confirmed metastatic papillary carcinoma. Left neck debulking was performed subsequently on the 31st of March with tumour size measuring 110 X 80 X 65 millimetres and histology confirming massive papillary carcinoma with a malignant sinus to skin and areas of haemorrhage and necrosis within the mass.

Following surgical debulking she was referred to Royal Brisbane and Women's Hospital (Brisbane, Queensland) on the 28th of June 2010 where she received I131 ablation therapy for residual disease. She was recommenced on thyroxine and discharged on the 1st of July 2010 with

residual disease as evidenced by CT and a thyroglobulin of 3710µg/L.

DISCUSSION

Papillary carcinoma of the thyroid is by far and away the most common form of thyroid cancer with 80% of patients with thyroid cancer having papillary carcinoma and a staggering 90% of new cases of thyroid cancer within the differentiated thyroid cancer family being attributable to this type^{4,5,6}. The remaining 10% of differentiated thyroid cancer is of the follicular type⁵. Although prevalence is high, papillary thyroid cancer is associated with good outcomes and generally the tumour is indolent with low distal metastatic potential with a high rate of cure^{3,7}. If appropriate treatment is implemented from the outset, long-term survival exceeds 90%⁷ and mortality rates reported in two studies as 2% and 7% respectively according to 10-year relative survival³.

Although favourable prognostically, recurrence of papillary carcinoma is not uncommon. In one study by Toniato et al., a recurrence rate of 8.3% was found at average follow up of 7.8 years either through clinical or radiological detection¹. This was detected either clinically or radiologically. This recurrence rate implies the existence of potentially more aggressive variants of the cancer and there have been cases reported with unusually aggressive behaviour. Saverio et al., reported a case of a 22 year old woman who underwent thyroid lobectomy for papillary carcinoma (follicular variant) who displayed local recurrences at 4 and 7 months post surgery with vascular invasion and extrathyroid spread. Thus although patients can expect good outcomes there is a subset of patients who don't do as well prognostically. There have been a number of factors reported which influence prognosis which likely play a role in potential recurrence. Lymph node metastasis at initial diagnosis is quite common with rates reported as high as 78% and 73% in some studies³. Although common, it appears the presence of positive lymph nodes has little influence on overall survival but likely influences recurrence. The factors which seem to play an important role in prognosis at time of diagnosis include male sex, large tumour size, age over 45 years, local invasion, incomplete resection, distant metastasis, histopathological features and postoperative administration of 131-I^{1,3}. Furthermore there have been multiple prognostic scoring systems developed in order to elicit the relative importance of each prognostic factor. Toniato et al., compared their prognostic indicators against three of the more favourable scoring systems. They concluded that age at first treatment,

T4 grading and positive metastasis were independent prognostic factors in agreement with the three scoring systems. More importantly they emphasised the importance of the extent of thyroid surgery and the 131-I therapy as a significant and independent prognostic factor. A further study by Lin et al., emphasised the importance of multicentric papillary thyroid carcinoma, which in itself is not unusual. They concluded that multicentric papillary carcinoma warrants postoperative adjuvant therapy and close surveillance within the first year as individuals diagnosed with this subtype need to be considered as high risk⁹.

Clearly there is some consensus regarding risk factors for recurrence and overall survival for papillary carcinoma, however what is uncertain is the role these factors play in predicting hugely recurrent disease as reported in this case. One reason for this is the lack of adequate definitions of recurrence based on size or extent. Here we use the term hugely recurrent as a means to justify the enormity of recurrence in this lady. However, there is no current guideline or definition in place to adequately stratify the size of recurrence. Furthermore there have been few reported cases of hugely recurrent papillary thyroid disease. Tomisawa et al., reported a case of giant recurrent papillary thyroid cancer in a female diagnosed at age 67. At age 92 the tumour had recurred in the cervical lymph node and reached a size of 10cm. The case we have presented here is the largest documented recurrence of papillary carcinoma to date.

Given the inadequacy of studies predicting factors for hugely recurrent papillary disease we can only hypothesise in this case as to reasons for such extensive recurrence. The currently accepted American Thyroid Association (ATA) guidelines for the initial treatment of differentiated thyroid cancer is the removal of all evidence of gross disease in the neck while minimising treatment and disease related morbidity¹⁰. Furthermore if any remnant disease exists the standard of care is the use of radioactive iodine (RAI) ablation therapy for residual disease. Intraoperative findings, histopathology description, RAI scan results and postoperative thyroglobulin are important elements of information during initial therapy which helps to stage disease and subsequently facilitates risk stratification and dictates further management and follow up. This information was unavailable regarding our case and whether she had received RAI is also uncertain after her first and second operations. Inadequate follow up appears to have played a significant role in the development of hugely recurrent

disease as presented in this case. The second recurrence was not assessed until 2009, some two years since the patient first detected recurrent lumps. This was due to a perceived failure of surgery. This highlights the importance of appropriate patient education regarding the extent and nature of disease, particularly in patients who have had previous recurrent disease.

Access to health care is an issue which plaques a number of developing nations. The ministry of health in Fiji underwent some major health care reforms between 1999 – 2003. Although changes to the health care structure have been made, the public health care system in Fiji is heavily dependent on general taxation. There is also a growing demand for and cost of health care and unfortunately limitations to resources¹¹. As a result for many individuals, particularly those living in smaller peripheral communities, access to health care is still an issue. Inadequate follow up coupled with issues surrounding access to healthcare may have played a role in the extent of recurrence reported in this patient.

References

1. Toniato A, Boschin I, Casara D, Mazzarotto R, Rubello D, Pelizzo M: Papillary thyroid carcinoma: factors influencing recurrence and survival. *Annals of Surgical Oncology*; 2008 May; 15(5): 1518-1522.
2. Tomisawa Y, Ogasawara S, Kashiwaba M, Inaba T, Takeda Y, Sugimura Y, Hatakeyama G, Asahi H, and Wakabayashi G: Mohs Chemosurgery for Local Control of Giant Recurrent Papillary Thyroid Cancer. *Thyroid*; 2009 19(6).
3. Tanaka K, Sonoo H, Hirono M, Ohkubo S, Nomura T, Ikeda M, Nakajima K, and Kurebayashi J: Retrospective Analysis of Predictive Factors for Recurrence After Curatively Resected Papillary Thyroid Carcinoma. *Surgery Today*; 2005; 35: 714 – 719.
4. Scurry W, Lamarre E, Stack B: Radioguided neck dissection in recurrent metastatic papillary thyroid carcinoma. *American Journal of Otolaryngology*; 2006; 27: 61-63.
5. Tuttle M, Leboeuf R, Martorella A: Papillary Thyroid Cancer: Monitoring and Therapy. *Endocrinology and Metabolism Clinics of North America*; 2007; 36: 753-778.
6. Kloos, R: Papillary Thyroid Cancer: Medical Management and Follow-up. *Current Treatment Options in Oncology*; 2005; 6: 323 – 338.
7. Pacini F: Follow-up of differentiated thyroid cancer. *European Journal of Nuclear Medicine*; 2002 29(2): S492 – S496.
8. Saverio G, Bergamaschi R, Manunta A: Papillary Thyroid Cancer with Unusually Aggressive Behaviour. *Acta Chirurgica Scandinavica*; 1989; 155: 57 – 58.
9. Lin JD, Chao TC, Hsueh C, Kuo SF: High Recurrent Rate of Multicentric Papillary Thyroid Carcinoma. *Annals of Surgical Oncology*; 2009; 16: 2609 – 2616.
10. Cooper DS, Doherty GM, Haugen BR: Management guidelines for patients with thyroid nodules and differentiated thyroid cancer. *Thyroid* 2006; 16(2): 109 – 142.

11. Health System Fiji: World Health Organisation website, western pacific region, Fiji, health system. 2010.

http://www.wpro.who.int/countries/2008/fij/national_health_priorities.htm.

Author Information

Peter Floros, MBBS

Department of General Surgery, The Toowoomba Hospital

Roger Grigg, FRACS

Department of Ear, Nose and Throat, The Toowoomba Hospital