

Asymptomatic foreign body aspiration in a child

H Deepak, S Vaidiyanathan, A Ranganath, A Patel, R Gupta

Citation

H Deepak, S Vaidiyanathan, A Ranganath, A Patel, R Gupta. *Asymptomatic foreign body aspiration in a child*. The Internet Journal of Anesthesiology. 2007 Volume 17 Number 1.

Abstract

Prevention and early recognition remain critical factors in the treatment of foreign body inhalation and ingestion in children. Accidental inhalation or ingestion of both organic and non organic foreign body material continues to be a cause of childhood morbidity and mortality. The diagnosis of foreign body aspiration may easily be missed. An unusual case of foreign body ingestion in a child is presented

CASE REPORT

A 2 year old female patient was brought in by her parents to the A & E. She had a history of feeling unwell with cough and fever for the past 2 weeks. She was recovering when in the morning the mother noticed popcorn being swallowed by the child and then the child had a choking episode. The child was then brought to the emergency department by the concerned mother who reported that she had removed most of the popcorn from the mouth of the child. The child was wheezy but did not have any major breathing problems. On examinations, there was a slight in drawing of the thoracic cage with inspiration. The child was administered nebulization with B agonists. X ray of the chest and neck in A-P view did not show any foreign body and lungs appeared normal. The child recovered well but still had intermittent wheezing episodes where she had cyanosis, sternal retraction and wheeze, she recovered every time after a few minutes. The symptoms were attributed to coryza as the child was unwell for 2 weeks. The child was playing with no symptoms or signs of hypoxia. 36 hours later the child went into respiratory arrest. CPR was done for 15 minutes and she was intubated. ABG showed type 1 respiratory failure. There was gross in drawing of the sternum and intercostals spaces. Ventilation after muscle paralysis was difficult and the child was sedated with spontaneous breathing. Chest X ray showed collapse of her right lung. She also had an episode of seizures 30 minutes later. A fibro optic bronchoscopy showed a popcorn kernel in her right main bronchus. The patient still continued to have seizures. The patient was electively ventilated for a day. On extubation, there was evidence of hypoxic brain damage with seizures still persisting.

Figure 1

X-ray when the child first came into the A&E

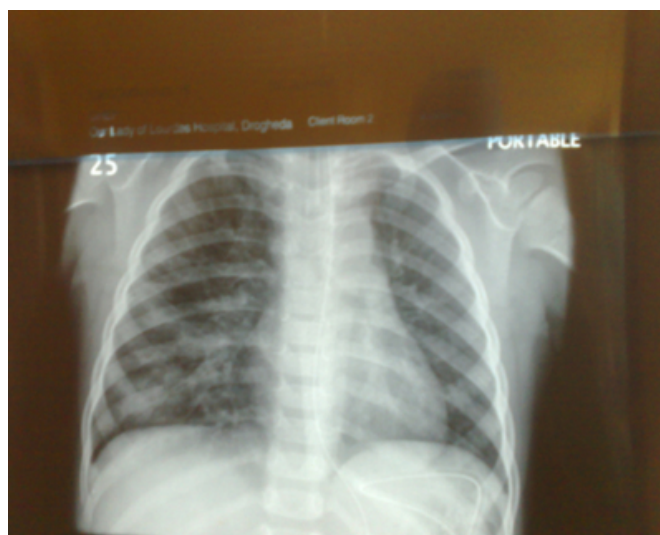
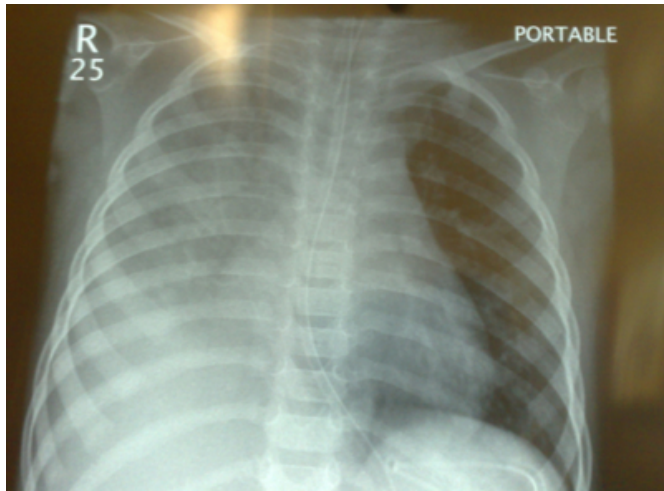


Figure 2

X-ray 36 hours after she came into the A&E (The right lung is collapsed)



DISCUSSION

The first known fatality attributed to aspiration is said to be the Greek poet Anacreon who died in 475 BC after aspirating a grape seed. Sir James Y. Simpson attributed the first well documented anesthesia related death in 1848. A significant advancement in bronchoscopy was achieved by introduction of Hopkins telescope in 1976 ¹.

Aspiration in a healthy individual is prevented by involuntary muscular mechanisms. As food is voluntarily moved from mouth to pharynx by the tongue, the involuntary mechanisms of swallowing are initiated. The soft palate is pulled upward and posteriorly to close the posterior nares preventing reflex of food into nasal cavities. The palatopharyngeal folds move medially to form a sagittal slit, which allows only well, chewed food to pass through easily. The epiglottis moves downwards to close the glottis. ²

The initial symptoms of aspiration of solid material vary depending on the size of the particles. Large objects, such as poorly chewed meat may lodge in upper end of oesophagus, but if they become impacted in larynx or trachea it will result in abrupt respiratory distress. Apnoea, cyanosis, loss of consciousness and death ensues unless the foreign body is dislodged ². However, aspiration of small foreign bodies is less dramatic. Cough is the initial manifestation. Dyspnoea, chest pain, wheezing, fever, nausea or vomiting may follow this.

Figure 3

Lemberg et al reported the following symptoms

Symptom	Age < 5yrs	Age >5 yrs
Witnessed event	75	83
Cough	65	58
Wheezing	49	33
Recurrent	9	4
Pneumonia Fever	25	8
Stridor	12	4

Figure 4

Mc Guirt et al reported the following physical findings

Physical finding	%
Decreased breath sounds	47
Wheezing	39
No helpful findings	39
Others	5

Wheezing in children is a common problem encountered by family physicians. Approximately 25 to 30 percent of infants will have at least one wheezing episode, and nearly one half of children have a history of wheezing by six years of age. The most common causes of wheezing in children include asthma, allergies, infections, gastroesophageal reflux disease, and obstructive sleep apnea. Less common causes include congenital abnormalities, foreign body aspiration, and cystic fibrosis. Children with recurrent wheezing or a single episode of unexplained wheezing that does not respond to bronchodilators should undergo chest radiography ^{5,6}. The principal complaint was sudden-onset cough (75.4%), auscultation was abnormal in 74%, and dyspnea was observed in 29%. Radiological abnormalities were seen in 88% of the cases. Aspirations were primarily into the right lung (54.8%), and 30.7% of the foreign bodies were of vegetal origin (principally beans and peanuts). ⁷

Inhalation and ingestion of foreign bodies is most common in pre-school children ⁸

CT scans may be used in airway FB management of pediatric patients, especially with diagnostic dilemmas, and further prospective evaluations should be considered to assess its overall efficacy. ⁹

In a study conducted, one thousand four hundred twenty-eight patient records with FB were retrospectively reviewed. This study mainly reported location and type of foreign body, complications, anesthesia methods, and outcome. The results showed that among the 1428 patients, 1424 (99.72%)

underwent successful removal of a foreign body by bronchoscopy. Foreign bodies were located in the trachea in 75 cases (5.25%), right bronchial tree in 780 patients (54.62%), left bronchial tree in 567 cases (39.71%), and bilateral bronchial tree in 6 cases (0.42%). Types of foreign body included peanuts (1244 cases, 87.12%), beans (93 cases, 6.51%), and others (91 cases, 6.37%). Tracheotomy was performed in 4 patients. Three patients (0.21%) died in this study. ¹⁰

In a study conducted in British Columbia Between July 1997 and July 2001, 51 children under 3 years of age underwent rigid bronchoscopy for suspected foreign body aspiration. Of these patients, 27 (53%) were 18 months of age or younger. Of these 27 infants and toddlers, 24 (89%) had a witnessed choking event and 22 (81%) had an airway foreign body. Nuts, raw carrots, and popcorn kernels accounted for 14 (64%) of the foreign bodies aspirated by these infants and toddlers. Before 2 years of age, children are poorly equipped to grind and swallow hard, crunchy food because they lack second molars and are still adjusting to the descent of the larynx. ¹¹

In this case, the child had swallowed a popcorn kernel which is radiolucent. She was feeling unwell for the past 2 weeks with symptoms suggestive of coryza. So when the X ray was normal and the wheeze persisted it was contributed to the preexisting corzya. There have been reports where radiolucent foreign bodies were not detected by X ray and there have been discussion for the use of CT in such cases. Our case was unusual as the child was well with no respiratory problems and so making a diagnosis of foreign body aspiration was difficult. This case highlights the different manifestations of a radiolucent foreign body. The main difference here was that the child had intermittent episodes of wheezing, cyanosis and sternal retractions which is not seen in croup or coryza and went more in favour of foreign body aspiration. This was the most important differentiating point which was missed. If there is a degree of suspicion of foreign body aspiration ,CT scan would have been a better option compared to X ray. CT scan if done on this case might have picked up the diagnosis early as

radiolucent materials are not seen in X rays.. The foreign body was of ball valve type, so when paralysed there was loss of the laryngeal muscle tone making ventilation difficult. So the patient was spontaneously ventilating with only minimal sedation. Seizures were due to the hypoxic damage. There needs to be a great degree of suspicion in any case of suspected foreign body aspiration even if the X ray is initially normal, this was seen in our case where the popcorn kernel was radiolucent. The popcorn kernel increased in size by absorption of water vapor and secretions after a few hours leading to respiratory distress and arrest.

We conclude that in any case of suspected FB aspiration, CT should be a mandatory investigation to rule out any radiolucent FB.

References

1. Patricia AT, Robert JK, Campion EQ. Aspiration emergencies. Clinics in chest medicine March 1994; vol 15(No 1): 117-135
2. Fredrick WM, Keith DH, Robert F, Dale JB. Tracheobronchial foreign bodies. Laryngoscope June 1988; 98: 615-618
3. Paul SL, David H, Lauren D. Aerodigestive tract foreign bodies in the older child and adolescent. Annals of Othorhinolaryngology 1996; 105: 267-271
4. Fredrick WM, Keith DH, Robert F, Dale JB. Tracheobronchial foreign bodies. Laryngoscope June 1988; 98: 615-618
5. Weiss LN. The diagnosis of wheezing in children Am Fam Physician. 2008 Apr 15;77(8):1109-14.
6. Daines CL, Wood RE, Boesch RP. Foreign body aspiration: an important etiology of respiratory symptoms in children J Allergy Clin Immunol. 2008 May; 121(5):1297-8.
7. .Fraga Ade M, Reis MC, Zambon MP, Toro IC, Ribeiro JD, Baracat EC Foreign body aspiration in children: clinical aspects, radiological aspects and bronchoscopic treatment. J Bras Pneumol. 2008 Feb;34(2):74
8. Elloy MD, Worley GA, Bailey CM.. Foreign Body Inhalation: A Case of Mistaken Identity? J Emerg Med. 2008 Apr 23
9. Hong SJ, Goo HW, Roh JL. Utility of spiral and cine CT scans in pediatric patients suspected of aspirating radiolucent foreign bodies. Otolaryngol Head Neck Surg. 2008 May;138(5):576-80
10. Hui H, Na L, Zhijun CJ, Fugao ZG, Yan S, Niankai ZK, Jingjing CJ. Therapeutic experience from 1428 patients with pediatric tracheobronchial foreign body. J Pediatr Surg. 2008 Apr;43(4):718-2
11. Morley RE, Ludemann JP, Moxham JP, Kozak FK, Riding KH. Foreign body aspiration in infants and toddlers: recent trends in British Columbia J Otolaryngol. 2004 Feb;33(1):37-41.

Author Information

HRH Deepak, MD

Senior House officer, Department of Anaesthesia and Intensive Care, Our Lady of Lourdes Hospital

Sabanayagam Vaidyanathan, DA

Senior House officer, Department of Anaesthesia and Intensive Care, Our Lady of Lourdes Hospital

Anil Kumar Ranganath, DA

Senior House officer, Department of Anaesthesia and Intensive Care, Our Lady of Lourdes Hospital

Anil Kumar Patel

Senior House officer, Department of Anaesthesia and Intensive Care, Our Lady of Lourdes Hospital

Rekha Gupta, MD FRACSI