An Iatrogenic esophageal perforation with dentures: How Does It Happen?

R Singh, S Varshney, S Bist, N Gupta

Citation

R Singh, S Varshney, S Bist, N Gupta. *An Iatrogenic esophageal perforation with dentures: How Does It Happen?*. The Internet Journal of Head and Neck Surgery. 2007 Volume 2 Number 2.

Abstract

We present a rare case of esophageal perforation in an attempt of removing an ingested denture with a flexible esophagoscope by a general practitioner. The Computerized Tomography (CT) scan of neck and thorax confirmed the diagnosis and denture was successfully removed through rigid esophagoscopy and perforation was surgically repaired by thoracotomy approach. The presentation of this case could be a revelation for the general practitioners. The various aspects of denture as an esophageal foreign body and the esophageal perforation have been discussed.

INTRODUCTION

Dentures are one of the most notorious foreign bodies of its own kind. They contain serrated edge and metal wire that can easily damage the strongest mucosal layer of esophagus causing esophageal perforation [1,2]. Thus, it is mandatory to keep the sharp and metallic end of the denture away from the esophageal mucosa. It can be done by placing it inside the lumen of wider rigid esophagoscope before its withdrawal. Such maneuver cannot be done by using flexible esophagoscope. Hence, all precaution should be taken during dental removal otherwise; it may result in catastrophic esophageal perforation [2,3,4]. The esophageal perforation always possess high rate of mortality due to its relation with vitals structure of thorax. Boerhaave correctly stated it: “When it occurs it can be recognized but it cannot be remedied by the medical profession” [5].

CASE REPORT

A 57-years old otherwise healthy female was referred to us for the management of an iatrogenic esophageal perforation and a denture inside the esophagus. She accidentally ingested her denture 12 days back. However, the patient was virtually comfortable with esophageal foreign body except mild pain during swallowing. In due course, the pain gradually increased in its intensity and compelled the female to get medical attention after 12 days of ingestion. She consulted with a general surgeon who was practicing gastro-intestinal endoscopy in a private clinic. Perhaps, the practitioner diagnosed this case as an uncomplicated foreign body in esophagus based on plain X-ray of neck and chest. Hence, she was advised removal of the ingested denture under general anesthesia. During the procedure, the surgeon used a “flexible esophagoscope” and he noticed an impacted denture at the lower end of esophagus. He began to drag the denture out from the esophagus. At the same time, he noticed bleeding while he was in the mid way with the denture in mid esophagus. He wisely left away the procedure and called a qualified ENT practitioner for assistance. When the ENT surgeon was performing rigid esophagoscopy, he noticed surgical emphysema in the neck. Both the surgeons decided to stop the maneuver and refer the patient to us for further management.

On admission, the patient conscious, her temperature was 99.6 °F, pulse rate of 76 beats/min and arterial blood pressure of 140/90mm of mercury. Physical examination revealed the patient in moderate distress with mild shortness of breath. Her oral cavity examination revealed loss of right upper incisor. No abnormalities were noted on examination of the oropharynx. Neck examination revealed lateral tenderness and crepitus extending up to the upper chest and face. On pulmonary auscultation, sparse added sounds were heard over the right hemithorax. Cardiac auscultation revealed a regular rate and rhythm without murmurs. An abdominal examination was normal.

Keeping the esophageal perforation in mind, the patient was kept in observation with the advice of nil orally, broad-spectrum intravenous antibiotics, proper balance of fluid input and output charting and half an hourly vital sign recording. The CT scan of neck and thorax was advised that

revealed air in the subcutaneous plan of neck, right sided hydropneumothrox, left sided pneumothrox and hydropneumomediastinum (Fig 1).

Figure 1

Figure 1: Photograph of denture after removal.

A linear hyperdense foreign body was noticed in food passage at the level of D4 with suspected perforation of esophagus in mid esophagus (Fig 2).

Figure 2

Figure 2: CT scan of thorax shows a foreign body in esophagus with multiple air pockets in different tissue plan.

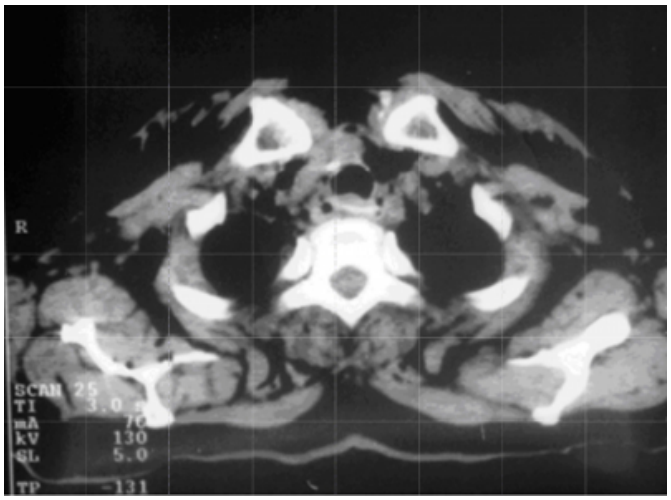

The esophagogram was unsuccessful because patient was unable to swallow the dye. Based on these finding the diagnosis of foreign body in esophagus, esophageal perforation with pulmonary and mediastinal complication was made. However, the other vitals of the patient were quite stable in continuous recording. The patient was immediately shifted to the cardiothoracic operation theater and the denture was successfully removed through rigid esophagoscopy without doing any further injury to the esophagus (Fig 3).

Figure 3

Figure 3: CT scan of thorax shows right side hydropneumothorax, pneumomdiastinum and multiple air shadow in subcutaneous tissue.

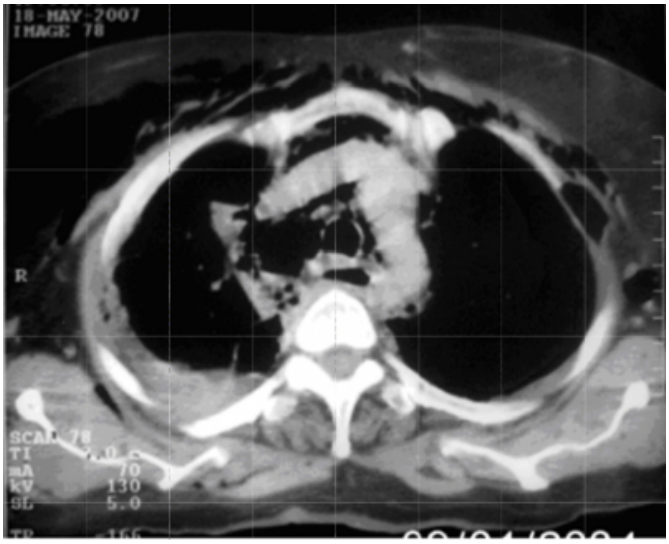

The foreign body was noticed at the 27cm level of upper central incisor. An esophageal tear of near 1.5cm size was noticed at the same level in right side tugging the denture. The right thoracotomy was performed, the rupture was identified (Fig 4) and repaired in layer. Bilateral water sealed chest drain was kept in place, the wound was closed and feeding gastric tube was inserted through right nostril. On the subsequent days, the patient has got very speedy recovery. The chest tube was removed on fifth postoperative days while the feeding tube was taken out on 14 th postoperative day. She was given on normal diet on the 14th day. She was discharged from the hospital on 17 th postoperative day. She is now leading healthy life.

Figure 4

Figure 4: Photograph shows perforation in mid esophagus.

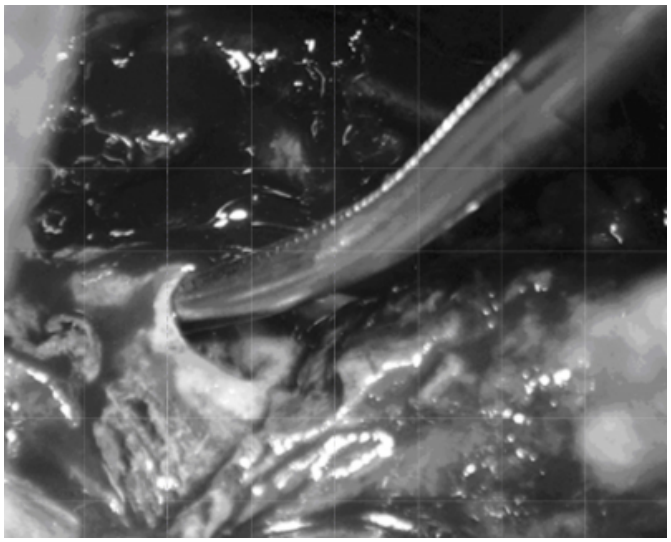

DISCUSSION

The sword-swallowers in Greece were the first people in 300BC to think about the technique of esophagoscopy. However, Adolph Kussmaul was the first physician to perform an esophagoscopy on a professional sword swallower in 1868 using a rigid 47-cm straight tube with lighting, a Frenchman designed tube named Desmormeaux. Wallenburg later used an elastic tube with a laryngeal mirror [5,6]. McKenzie developed a skeleton esophageal tube and with this tube he was really only able to see into the cervical esophagus. Neitsliter then developed a rigid straight tube, which was lighted with a heated platinum wire distally [6]. The today's “rigid esophagoscope” was actually designed by Chevalier Jackson, who breached new ground in aerodigestive foreign body management. He used Edison invented the light bulb projected light distally instead of the having the light source in the proximal region. He generally used this scope for foreign bodies and dilation of lye ingestions, known as “father of esophagoscopy”[5,6,7].

Information concerning esophageal perforations and its management is plentiful. The first report of esophageal perforation came in 1724 when Dr. Hermann Boerhaave examined a Dutch grand admiral Baron Jan van Wessenaer. He developed the post emetic rupture of lower esophagus and subsequent rapid death. Dr. Hermann Boerhaave truly said on esophageal perforation “When it occurs it can be recognized but it cannot be remedied by the medical profession.” This statement bore some truth until 1947 when Barrett performed the first successful repair of a perforated esophagus [5, 7].

The esophagus is a very thin-walled organ connecting hypopharynx to stomach. Contrary to the rest of the alimentary canal, it is a delicate tube of digestive system lacking strong elastin and collagen containing outermost serous layer. Hence, the inner mucosal layer being the strongest layer supported outwardly with submucosal layer, circular and longitudinal muscular fibers [5, 8]. Moreover, it contains three areas of narrowing: the first area is the cricopharyngeus (15cm), which is the narrowest region, about 1.5cm. The next area of narrowing of the esophagus is where the left main stem bronchus and the aorta cross it (24cm), and then the third is the gastroesophageal sphincter (40cm) [9]. These areas of narrowing provides maximum resistant during negotiation of esophagoscope and withdrawing a foreign body. Thus, it is important for a surgeon to maintain the integrity of the strongest mucosal layer and to take special care at the level of esophageal constrictions [8, 9].

Several mechanism including shearing along the longitudinal axis, direct piercing, thinning from necrosis of esophageal wall and bursting from the radial force may play in producing esophageal perforation. However, shearing and piercing is the main means to produce perforation during instrumentation being the commonest cause comprising of nearly 50 to 75% of all perforations. The only rigid endoscopy carries a perforation rate 0.1-0.4%, while that of flexible endoscopy varies from 0.01-0.06%. However, chances of esophageal perforation would be much higher if the flexible endoscope is used for the removal of voluminous or sharp foreign body like denture. Foreign bodies can also cause esophageal perforation (5-15%), as well as trauma (2-9%) [8,9,10,11,12].

The sharp edged foreign bodies such as denture are the most notorious of all ingested foreign bodies. Any hasty and over enthusiastic maneuver could be disastrous. It can increase the chance of perforation for several times at the natural constriction level. The pharyngoesophagial junction being the commonest site as it is weakest and narrowest of the entire length of esophagus. The perforated wall can provide the extra space for the denture to stick the site of lodgment. The further forceful maneuver may further increase the length of perforation and some time damage the extra esophageal structure including great vessels. The denture contains serrated edge that can incise the esophageal wall. The situation could be more worst if it is having wires [1, 2, 13]. However, the presence of wire can give an opportunity to localize the foreign body easily through radiological

investigation such as plain x-ray. The dentures are radiolucent objects can only be picked up by negative shadow during barium X-ray study. A contrast-enhanced CT scan of the chest should be obtained if it is not possible to perform a contrast esophagogram, if the esophagogram was negative despite a high clinical suspicion, or if seeking to evaluate for a more likely alternative diagnosis. Mediastinal air, extravasated luminal contrast, periesophageal fluid collections, pleural effusions, or actual communication of an air-filed esophagus with an adjacent mediastinal air-fluid collection may suggest perforation [2,8,9,13].

Every precaution should be taken in the way to withdrawing the denture from esophagus. A risk evaluation including proper estimation of the shape and size of the denture, its location in esophagus and the duration of lodgment is required before endoscopic removal. In case of unsuccessful endoscopic extraction of denture, it is possible to use fragmentation. The further care should be taken not to advance it more distally in to esophagus even it is closer to the esophagogastric junction [1,2,14].

In our view, it is essential to incorporate the serrated end or the end containing wire should be taken inside the esophagoscope before its withdrawal. Hence, widest size esaphagoscope could be ideal for the removal of denture. The presence of classic “Mackler triad” consisting of vomiting, chest pain, and subcutaneous emphysema and radiological evidence can confirm the esophageal perforation. Once perforation occurs, the surrounding loose stromal connective tissue, the infectious and inflammatory response can disseminate easily to nearby vital organs. Thus, results in complications including pneumonia, mediastinitis, sepsis, empyema, and adult respiratory distress syndrome, multi organ failure and death [8,9].

CORRESPONDENCE TO

Dr. Rakesh Kumar Singh, Assistant Professor, Department of Otolaryngology Head and Neck Surgery, Himalayan Institute of Health Sciences, Jollygrant, Doiwala, Dehradun, Phone No: +91 135 2410940 Fax No +91 135 2471122 E-mail: rksent5@gmail.com

References

1. Nimmo S S, Nimmo A, Chin G A. Ingestion of a unilateral removable partial denture causing serious complications. Oral Surg 1988; 66: 24-26.
2. Stiles B M, Wilson W H, Bridges M A, et. al. Denture esophageal impaction refractory to endoscopic removal in a psychiatric patient. J Emergency Med 2000; 18: 323-326.
3. Coman W B. The partial denture - a dangerous foreign body. Med J Aust 1972; 2:1126-1128.
4. Treska T P, Smith C C. Swallowed partial denture. Oral Surg Oral Med Oral Pathol 1991; 72: 756-757.
5. Scheinin S A, Wells P R. Esophageal Perforation in a Sword Swallower. Tex Heart Inst J. 2001; 28: 65-68.
6. Huizinga E. On esophagoscopy and sword swallowing. Ann Otol Rhinol Laryngol 1969; 78:32-39.
7. Barrett NR. Report of a case of spontaneous perforation of the oesophagus successfully treated by operation. Br J Surg 1947; 35:216-8.
8. Flynn AE, Verrier ED, Way LW, Thomas AN, Pellegrini CA. Esophageal perforation. Arch Surg 1989; 124: 1211-1215.
9. Lowell M, Barsan WG. Esophageal Perforation. Marx JA (Ed.). Rosen's Emergency Medicine: Concepts and Clinical Practice 2002; 5th; C. V. Mosby: 1237-8.
10. Ku P K M, Tong M C F, Ho K M, Kwan A, van Hasselt C A. Traumatic esophageal perforation resulting from endotracheal intubation. Anesth Analg 1998; 87:730-31.
11. Chung C S. Subtle perforation of the oesophagus by a foreign body. Hong Kong Med J 2003; 9: 290-292.
12. Glaws WR, Etzkorn KP, Wenig BL et. al. Comparison of rigid and flexible esophagoscopy in the diagnosis of esophageal disease: diagnostic accuracy, complications, and cost. Ann Otol Rhinol Laryngol 1996; 105:262-266.
13. von Rahden B H A, Feith M, Dittler H-J, Stein H J. Cervical esophageal perforation with severe mediastinitis due to an impacted dental prosthesis. Dis Esophagus 2002; 15: 340-344.
14. Costa H D, Bailey F, McGavigan, George G, Todd B. Perforation of the oesophagus and aorta after eating fish: an unusual cause of chest pain. Emerg Med J 2003; 20:385-386.

Author Information

Rakesh K. Singh, MS
Assistant Professor, Department of Otolaryngology Head and Neck Surgery, Himalayan Institute of Medical Sciences

Saurabh Varshney, MS
Professor and Head, Department of Otolaryngology Head and Neck Surgery, Himalayan Institute of Medical Sciences

Sampat S. Bist, MS
Assistant Professor, Department of Otolaryngology Head and Neck Surgery, Himalayan Institute of Medical Sciences

Nitin Gupta, MS
Senior Resident, Department of Otolaryngology Head and Neck Surgery, Himalayan Institute of Medical Sciences