

Mediastinal Seminoma: A Case Report

F Gândara, A Leitão, M Bernardo, S Ramos, I João, F Ceia

Citation

F Gândara, A Leitão, M Bernardo, S Ramos, I João, F Ceia. *Mediastinal Seminoma: A Case Report*. The Internet Journal of Internal Medicine. 2009 Volume 9 Number 1.

Abstract

Seminoma is a rare, malignant germ cell tumor (GCT) that usually develops in the third or fourth decade of life in males. Although the most common location for a malignant GCT is the gonads, it can also arise in extragonadal regions, such as the mediastinum. The authors describe a case of a 37-year-old caucasian man, with smoking habits, arterial hypertension and dyslipidemia, who was admitted for posterior cervical pain with anterior chest irradiation. The physical examination revealed hypertension (158/112mmHg), reduced breath sounds over the superior left lung field, and no palpable peripheral lymph nodes. A chest X-ray film showed an abnormal left shadow in the superior mediastinum. Thorax computerized tomography revealed a volumous anterior superior mediastinal mass. The histological and immunohistochemical evaluation led to the diagnosis of mediastinal seminoma. Specific laboratory studies revealed increased levels of LDH and beta-HCG, and normal AFP. Careful clinical and ultrasound examinations showed normal testis. Abdominal, pelvic and cerebral CT was normal. The patient was treated with four cycles of bleomycin, ectoposide and cisplatin with complete tumor imaging remission. Although this case is rare, seminoma should be considered in the differential diagnosis of a mediastinal mass, even in the absence of testicular lesions. When treated, the prognosis is good, with a mean survival of 90% at five years.

INTRODUCTION

Although seminomas occur preferentially in the gonads, they can also arise in extragonadal regions, the most common primary localization being the anterior mediastinum^{1,2}. Primary malignant tumors of the mediastinum affect mainly young males, are usually asymptomatic at the time of diagnosis and the clinical picture may present as an emergency^{3,4}. In some recently published reports of malignant mediastinal tumors, the most common symptoms are cough (83.5%), dyspnea (75.8%) and chest pain (56%)³. The highest rate of 5-year survival is in patients with seminomas³.

The aim of this article is to report a case of a primary mediastinal seminoma in a young male who presented initially with posterior cervical pain with retrosternal chest irradiation.

CASE REPORT

A 37-year-old male presented to the emergency department with a 3-day history of an acute posterior cervical pain followed by continuous chest pain across the anterior precordium. The last one described as pressure that worse with deep inspiration. He denied having any cough, dyspnea, weight loss, palpitations, syncope, dizziness, nausea, fever,

trauma or recent vigorous exercise.

His medical history included arterial hypertension, dyslipidemia, smoking habits and obesity. There was no personal history of previous chest pain and familiar history of ischemic heart disease.

Upon examination his blood pressure was 158/112 mmHg, pulse regular with a rate of 74 bpm, normal temperature (36.6°C), respiratory rate (16 breaths/min) and had an oxygen saturation of 97% while breathing room air. There was no peripheral lymphadenopathy and examination of cervical region was normal. Pertinent findings on chest examination included decreased vocal fremitus and on auscultation reduced breath sounds over the superior left lung field. His heart sounds were normal and without murmur, rub, or gallop. The rest of his examination revealed no other findings.

Initial investigation with a chest X-ray film showed an abnormal left shadow in the anterior mediastinum (Figure 1). His electrocardiogram was consistent with normality. Routine laboratory analysis, including a complete blood cell count, a basic metabolic panel, cardiac enzymes and arterial blood gas was normal.

A thorax computed tomography (CT) was ordered, which

reported the presence of a polilobulated homogeneous mass, 10cm by 15cm, in the anterior superior mediastinum. The mass extended thoracic operculum to the origin of great vessels (in contact with supra aortic trunk and aortic arch, ascending aorta and pulmonary trunk) and anterior wall of the right ventricle outflow tract, with no signs of invasion (Figure 2).

Figure 1

Figure 1- Chest X-ray film: abnormal left shadow in the anterior mediastinum.

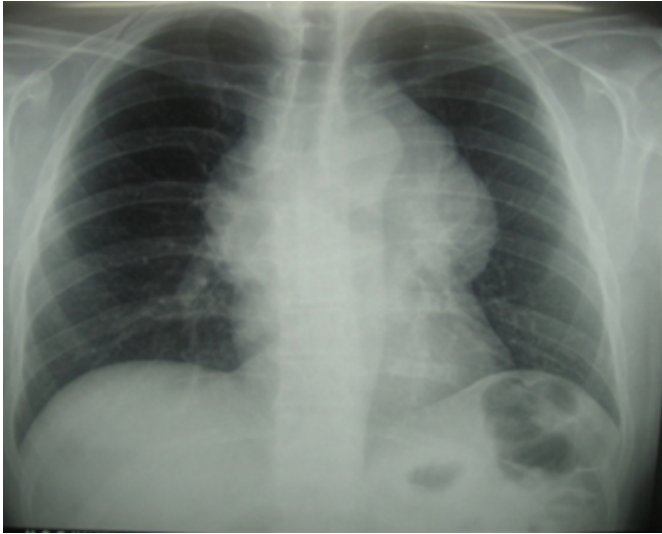
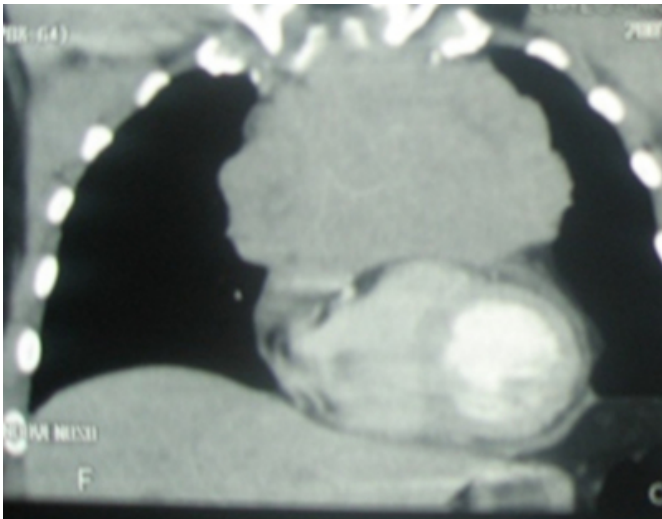


Figure 2

Figure 2- Thorax CT: large anterior superior mediastinal mass, extended from thoracic operculum to the great vessels and anterior wall of right ventricle.



A cardiothoracic surgeon was called, based on the patient's clinical presentation. For the diagnosis and attendant to the localization of the mass the surgeon decided to perform an open biopsy through an anterior mediastinotomy.

Macroscopic findings showed a large and hard mass. Inside, the tumor had a soft consistency (described as encephaloid) and was well vascularised. Several biopsies were performed and sent to the pathology department.

Histological evaluation of the specimen revealed pleomorphic cells with an abundant clear cytoplasm, prominent nucleoli and central nuclei, admixed with small lymphocytes (Figure 3). On immunohistochemical staining the tumor cells were positive for CD117 and CD10 (Figure 4), but negative for different cytokeratins and epithelial membrane antigen (AE1/AE3- carcinoma marker), alpha fetoprotein (AFP), beta -HCG, PSA, Vimentin (sarcoma marker), CEA, S-100 protein and HMB45 (melanoma marker), CD30 and CD15 (Hodgkin disease markers) and CD-20 (B-cell marker). Specific laboratory tests showed an LDH of 1016 U/L (N: 313-618), beta-HCG of 26.7 U/L (N < 3,0), AFP of 1.80ng/mL (N: < 9,0) and beta2-microglobulina of 1.7mg/L (N: 0,67-1,31).

The testicular ultrasound and abdominal, pelvic and cerebral CT scans revealed no other lesions.

Figure 3

Figure 3- Biopsy specimen of mediastinal mass (Hematoxylin and Eosin x100): Pleomorphic cells with abundant clear cytoplasm, prominent nucleoli and central nuclei, admixed with small lymphocytes.

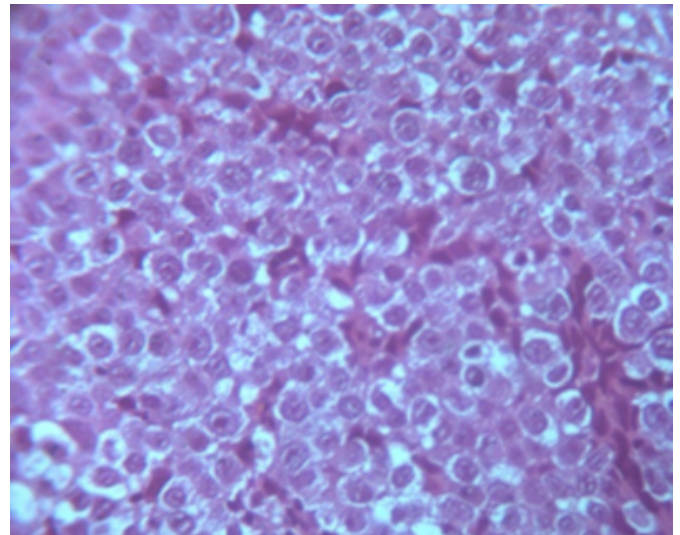
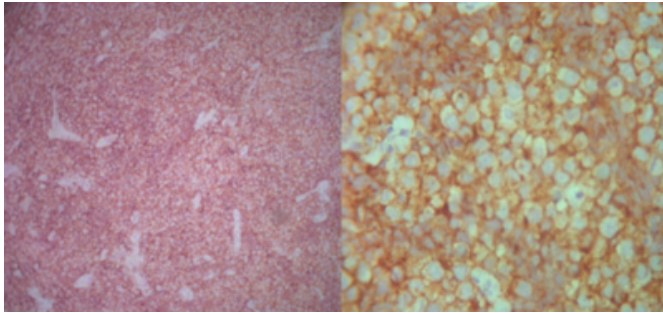


Figure 4

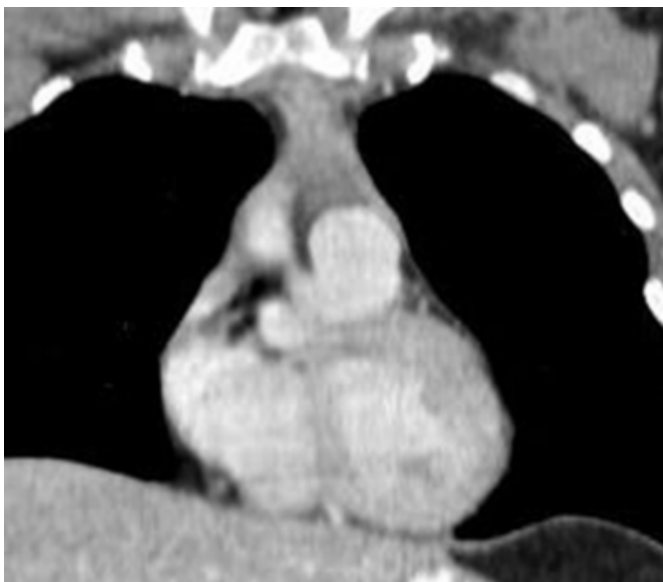
Figure 4- Immunohistochemical stains positive for CD10+ (a) and CD117+ (b).



The final diagnosis based on a combination of clinical, histology and immunohistochemical features was primary mediastinal seminoma, stage I. The patient began chemotherapy treatment with four cycles of Bleomycin, Etoposide and Cisplatin (BEP). The treatment was well tolerated with a complete imaging remission of the mediastinal tumor. The patient wasn't submitted to radiotherapy. After 24 months of follow-up beta-HCG levels were normal (<1.2U/L) and there were no signs of disease (confirmed by thorax CT – Figure 5).

Figure 5

Figure 5- Thorax CT performed 24 months after chemotherapy.



DISCUSSION

Germ cell tumors (GCT) can be benign (teratomas) or malignant, including seminoma and non-seminomatous germ cell tumors (embryonal carcinomas, immature teratoma, yolk sac carcinoma, choriocarcinomas and mixed

germ cell tumors)^{1,3,4}. Although GCT commonly occurs in the gonads, 2-5% of them arise in extragonadal regions, preferentially in midline structures such as the mediastinum, retroperitoneum, pineal gland and sacral area. The anterior mediastinum is the most common site of primary extragonadal GCT^{1,3,5}. Primary mediastinal seminoma has an estimated incidence of 25% of all primary mediastinal GCT^{1,2}. Although the exact histogenesis of mediastinal seminomas has not been determined, extragonadal locations are attributed to the abnormal migration of germ cells during embryogenesis^{1,6,7}.

The most common symptoms are chest pain, dyspnea and cough, secondary to compression of adjacent structures. Superior vena cava syndrome has been documented in 10-20% of cases. Some of them are asymptomatic and found incidentally on routine radiographic examinations^{5,6}.

In this case, the differential diagnosis includes a variety of metastatic as well as primary mediastinal neoplasms. Thus, histologic findings and immunohistochemical analysis are necessary to establish the diagnosis of mediastinal seminoma.

Among primary mediastinal tumors, the most common are thymoma, thymic carcinoma, and Hodgkin's disease. The possibility of a mediastinal metastasis from a testicular seminoma should always be considered, but these are extremely rare⁶. In our patient, testicular ultrasound and abdominal, pelvic and cerebral CT scan rules out this hypothesis.

Mediastinal seminoma tumor markers AFP and beta-HCG are important for patient management and follow-up⁵. AFP is usually normal and beta-HCG is elevated in 5-10% of these tumors⁸, which justifies a biopsy to established diagnosis.

The current treatment of primary mediastinal seminoma is with three or four cycles of Bleomycin, Etoposide and Cisplatin (BEP). These tumors have a good prognosis with a 5-year survival rate of 90%^{1-3,5}. Our patient was treated with four cycles of the recommended protocol and after 24 months of follow-up maintains complete remission of the mediastinal tumor (based on imaging) and beta -HCG level normalization. However, this follow-up time is not enough to determine long-term prognosis.

Seminoma should be considered in the differential diagnosis of a mediastinal mass in young males, even in the absence of

testicular lesions.

References

1. Khan FY, Al Ani A, Allaithy MS, Al-Bozom IA: A young male with shortness of breath. *Ann Thorac Med*; 2008;3(1):28-30.
2. Nakamura H, Hashimoto T, Kusama H, Sudoh A, Adachi H, Yagyu H, et al: Primary seminoma in the middle mediastinum. *Intern Med*; 2004; 43(12):1191-3.
3. Dubashi B, Cyriac S, Tenali SG: Clinicopathological analysis and outcome of primary mediastinal malignancies - A report of 91 cases from a single institute. *Ann Thorac Med*; 2009; 4(3):140-2.
4. Davis RD, Oldham HN, DC S. *The Mediastinum*. 5th ed Philadelphia. WB Saunders; 1989.
5. Díaz Muñoz de la Espada VM, Khosravi Shahi P, Hernández Marín B, Encinas García S, Arranz Arija JA, G. P-M: Tumores germinales mediastínicos. *Anales Medicina Interna (Madrid)*; 2008; 25 (5):241-243.
6. Moran CA, Suster S, Przygodzki RM, Koss MN: Primary germ cell tumors of the mediastinum: II. Mediastinal seminomas--a clinicopathologic and immunohistochemical study of 120 cases. *Cancer*; 1997; 80(4):691-8.
7. Debe M. et al: Extragonadal yolk sac tumor in pelvic localization. *Gynecol Oncol*; 2004; 92(3):989-991.
8. J. Bernardes Correia, A. Cristina Rodrigues, Amândio Cardoso, Pedro Ribeiro, M. J. Julião, Paulo Tavares, et al: Seminoma primário do Mediastino. *Medicina Interna (Revista da SPMI)*; 1996; 3(3):163-165.

Author Information

Filipa Gândara, P.A

Medicine Ward (III), Hospital de São Francisco Xavier

Ana Leitão, M.D.

Medicine Ward (III), Hospital de São Francisco Xavier

Manuela Bernardo, M.D.

Department of Oncology of Hospital, Hospital de São Francisco Xavier

Sância Ramos, M.D.

Department of Anatomopathology, Hospital de Santa Cruz

Isabel João, M.D.

Medicine Ward (III), Hospital de São Francisco Xavier

Fátima Ceia, Ph.D.

Medicine Ward (III), Hospital de São Francisco Xavier