

Adrenal Ganglioneuroma Presenting With Adrenal Insufficiency After Unilateral Adrenalectomy

S Bontha, N Sanalkumar, M Istarabadi, G Lepsien, G Abdul Aal .

Citation

S Bontha, N Sanalkumar, M Istarabadi, G Lepsien, G Abdul Aal .. *Adrenal Ganglioneuroma Presenting With Adrenal Insufficiency After Unilateral Adrenalectomy*. The Internet Journal of Urology. 2010 Volume 9 Number 1.

Abstract

Objective: To present a case of Adrenal Ganglioneuroma presenting with adrenal insufficiency after unilateral adrenalectomy. **Methods:** Adrenal insufficiency is rare after unilateral adrenalectomy for non-functioning adrenal tumours (1). Subclinical Cushing's syndrome, which is defined as mild and subtle elevations of cortisol level in the absence of clinical signs of Cushing's syndrome with adrenal incidentalomas, is more frequent than previously thought (2). If unrecognized prior to adrenal surgery this could lead to adrenocortical insufficiency due to hypothalamic-pituitary-adrenal axis suppression from the subtle cortisol elevations with life threatening implications (2). **Results:** A case of apparent subclinical Cushing's syndrome in a patient with adrenal ganglioneuroma manifesting as adrenocortical insufficiency in the immediate post operative period needing treatment with corticosteroids. **Conclusion:** Adrenal ganglioneuroma is a rare cause of subclinical Cushing's syndrome. If subclinical Cushing's syndrome is unrecognized prior to adrenalectomy it may lead to adrenal insufficiency in the immediate post operative period. Dynamic testing for subtle cortisol excess should be done in all patients before adrenalectomy.

INTRODUCTION

Adrenal insufficiency is rare after unilateral adrenalectomy for non-functioning adrenal tumours (1). Incidental adrenal neoplasms, called incidentalomas mostly tend to be benign and

asymptomatic (2). Subclinical Cushing's syndrome (SCS) with subtle cortisol elevations

and abnormalities of the hypothalamic-pituitary-adrenal (HPA) axis without clinical signs

is more frequent than previously thought (2). The incidence of SCS is approximately 5-

10 % of the adrenal incidentalomas (2). Dynamic testing is recommended for evaluating

autonomous cortisol

production by an adrenal incidentaloma (3). The overnight 1 Mg dexamethasone

suppression test (ODST) is recommended as the initial

screening test (3). In those

patients where surgery is done for adrenal incidentalomas based on size considerations

(>4Cms) or suspicion of malignancy then subclinical Cushing's syndrome should be

considered and evaluated due to the risk of adrenal insufficiency perioperatively (3).

Glucocorticoid therapy in the perioperative period and post operative assessment of HPA

axis recovery are indicated in patients with SCS (3). We would like to present one such

case where the pre-operative cortisol levels were normal, but post operatively the

Cortisol levels were low with a subnormal Synacthen test confirming adrenal

insufficiency.

CASE PRESENTATION

A 43 years old female patient was referred to the Endocrinology department at

Al Zahra Hospital, Sharjah for a low cortisol level after she had the removal of a left

adrenal adenoma laparoscopically. On post-op day 2 the patient had an AM cortisol in the

hospital which was found to be low at 1.9 micrograms per dl (mcg/dl). She was

asymptomatic. Her serum sodium was found to be slightly low at 133 mmol/l (Normal

range 135-153), potassium was normal at 3.8 mmol/l (Normal range 3.5-5.3). She was in

no acute distress and her vital signs were normal. A Synacthen (Cosyntropin,

Tetracosactrin) test was ordered which confirmed a low baseline cortisol of 1.8 mcg/dl

half an hour after injecting Synacthen it was 10.2 mcg/dl and

1 hour post Synacthen was 15.8 mcg/dl, a subnormal response to

Synacthen.

An ACTH (intact) level done prior to giving Synacthen was low at 1.3

picograms/ml(pg/ml) (Normal

range 10-60 pg/ml). The patient denied receiving any steroids of any kind either

orally or parenterally or intranasally prior to surgery.

She did not have any stigmata of Cushing's syndrome. The patient is known to have type

1 diabetes as well as primary hypothyroidism over several years with reasonable though

slightly suboptimal glycemic control (Hba1C of 7.3). She has not noticed any increase in

insulin requirements over the past several years. She did not have any stigmata of

Cushing's syndrome. She has no history of hypertension. She did not receive any

Etomidate by the anesthesiologist as well. Pre operative hormonal workup done by the

urologist showed a 11 AM cortisol level of 14.4 mcg/dl and plasma

catecholamines were normal. Serum electrolytes prior to surgery were normal.

Pre-operatively she had a CT scan of the abdomen which showed a well defined mass

lesion of the left adrenal gland 6.5 X 4.0 Cms without significant enhancement with

contrast.

A diagnosis of secondary/tertiary adrenal insufficiency due to subclinical Cushing's

syndrome from the left adrenal tumor was made and she was started on hydrocortisone

25 mgs intravenously every 8 hours which was reduced over the next 48 hours and she

was switched to Hydrocortisone 10 mgs BID and she was discharged home in a stable

condition with proper instructions regarding stress dosing of hydrocortisone and was also

given hydrocortisone 100 mgs/ml vial to be taken intramuscularly in case of an

emergency.

Histopathology of the large adrenal mass (Figures 1,2,3,4&5) on the left side of 6.5 X 3.0

X 4.0 cms, showed a smooth encapsulated mass firm in consistency. Cut surface was

fleshy pale grayish in color. Microscopic examination showed a benign tumor lesion

made up of bundles of schwann cells including very few scattered and mature ganglion

cells. The pathological diagnosis was Ganglioneuroma.

Two weeks post discharge the patient came back for follow up feeling good without any

complaints. An 8 AM cortisol was done after holding the previous day's evening dose as

well as the morning dose of hydrocortisone and it came back at 12.4

mcg/dl. Presuming that the HPA axis is beginning to recover a repeat Synacthen test was

done which showed a baseline cortisol of 10.7 mcg/dl and ACTH level of

33.3 pg/ml. Half an hour post Synacthen serum cortisol was 19.1 mcg/dl

and 1 hour post was 22.3 mcg/dl indicating a normal response to

Synacthen. The hydrocortisone dose was reduced to 10 Mgs OD. Two weeks later an 8

AM cortisol level was done after holding the AM dose of hydrocortisone and it was

normal 12.3 mcg/dl and her electrolytes were normal. She was advised to

completely discontinue the hydrocortisone and recommended stress doses of

hydrocortisone for any major procedures in the next 6 months.

MACROSCOPIC EXAMINATION

Figure 1

Figure 1: Left adrenalectomy specimen made up of a large tumor mass measuring 6.5 x 3 x 4 Cms, potato like, having smooth capsulated surface.

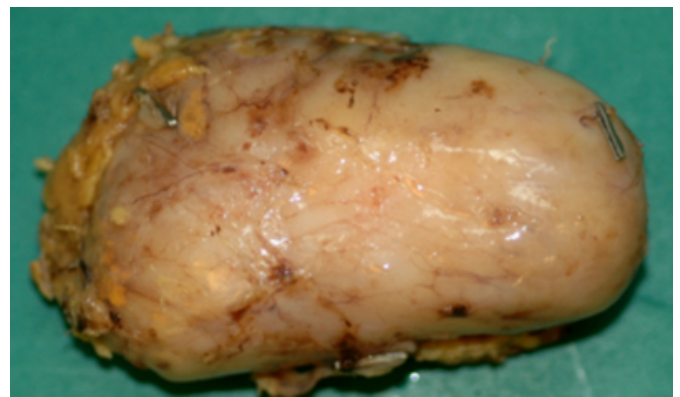
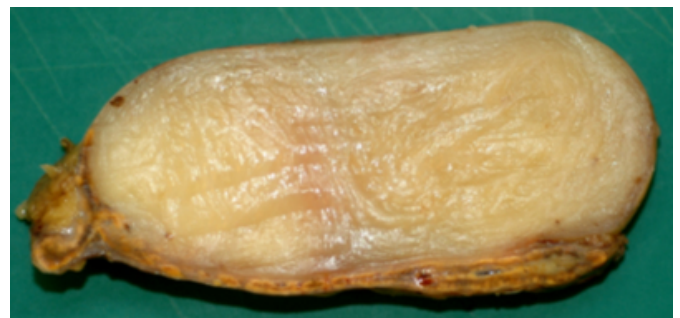


Figure 2

Figure 2: Cut surface is fleshy, pale grayish in color



MICROSCOPIC EXAMINATION

Figure 3

Figure 3: Benign tumor lesion made up of bundles of Schwann cells. Haematoxylin & Eosin stain (H&E). Magnification X 10 times.

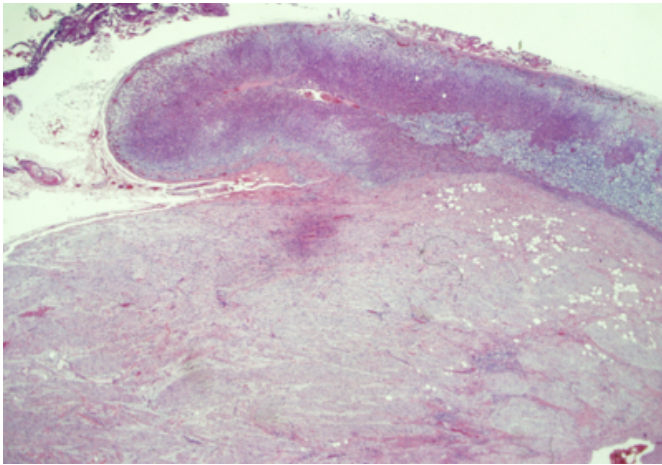


Figure 4

Figure 4: Bundles of schwann cells. H&E stain. Magnification X 20 times.

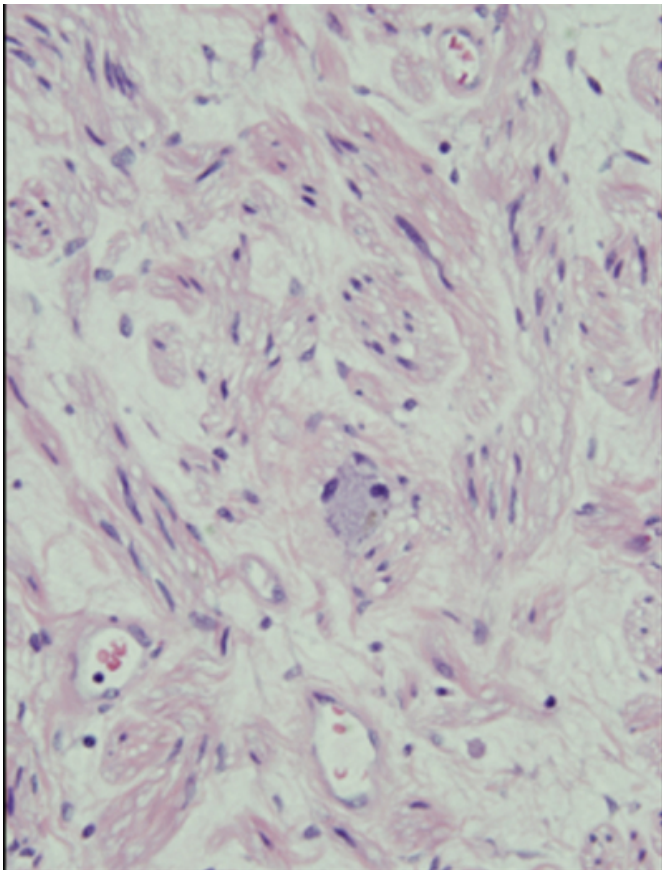
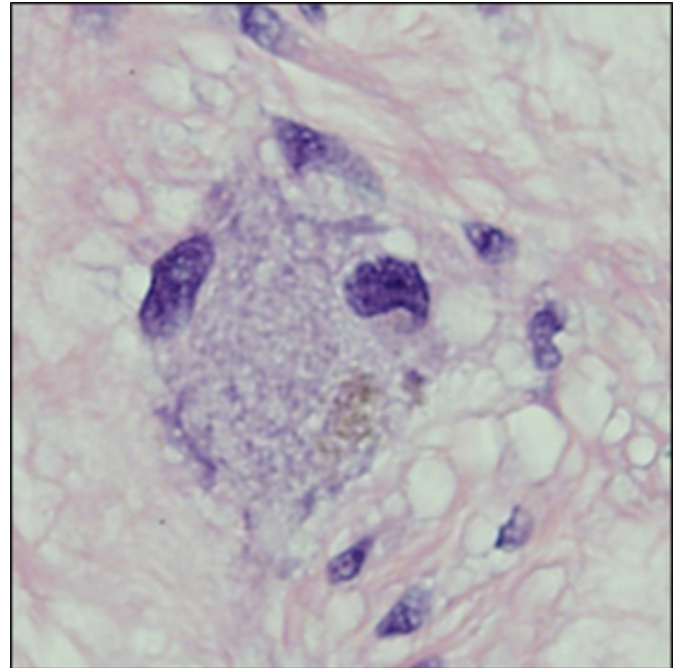


Figure 5

Figure 5: Few scattered mature ganglion cells. H&E stain. Magnification X 40 times.



CASE DISCUSSION

This interesting patient was found to have an incidental left adrenal mass when she was

worked up for left loin pains. Her pre-op hormonal workup for the adrenal mass revealed

normal cortisol levels as well as plasma catecholamine levels. On day 2 of the post

operative period she was found to have an AM cortisol level which was very low. A

subsequent Synacthen test showed a subnormal response to tetracosactrin as well as a

very low baseline ACTH (intact) level. She was asymptomatic. The only other laboratory

abnormality was a slightly low serum sodium level which goes in favor of secondary

adrenal insufficiency. She was treated with intravenous hydrocortisone without any

mineralocorticoids. She was stable on the treatment. Within several weeks her

Hypothalamic pituitary adrenal axis improved and she was withdrawn from the steroid

treatment.

In retrospect the explanation for the adrenal insufficiency was that she had

subclinical Cushing's syndrome from the left adrenal mass which caused HPA axis

suppression. It is to be noted that her cortisol

level prior to surgery was normal, emphasizing the need for dynamic testing for

subclinical Cushing's syndrome prior to surgery.

A literature review of reports of adrenal ganglioneuroma causing either pre-clinical or

overt Cushing's syndrome was made. There was one report of virilizing adrenal

ganglioneuroma in a woman with subclinical Cushing's syndrome by Diab et al(6) from

the Cleveland clinic. There were reports of Cushing's syndrome with adrenal

neuroblastoma in an infant (Kenny et al)(7), Adrenocortical adenoma and

ganglioneuroblastoma in a child(Dahms et al)(8) and ectopic Cushing's syndrome due to

an adrenal ganglioneuroma(Corcuff et al)(9). Adrenal ganglioneuroma is a rare cause of

subclinical Cushing's syndrome.

CONCLUSION

Adrenal insufficiency is rare after unilateral adrenalectomy for non-functioning adrenal tumors. Subclinical Cushing's syndrome although rare could have enormous clinical implications

to the patient if the diagnosis is missed as this could lead to catastrophic adrenal

insufficiency in the immediate post op period. Dynamic testing of autonomous cortisol

production for all adrenal masses is currently recommended pre-operatively. The current

recommendations from AACE include perioperative glucocorticoid therapy and post

operative assessment of HPA axis recovery in patients with SCS. Adrenal

ganglioneuroma is a rare cause of subclinical Cushing's syndrome.

References

1. Shen WT, Lee J et al. Selective use of steroid replacement after adrenalectomy.

Archives of Surgery 2006. 141: 771-776.

2. Rossi. R, Tauchmanova. L, Luciano. A, et al. Subclinical Cushing's Syndrome in

patients with Adrenal Incidentaloma: Clinical and Biochemical features. The Journal

of Clinical Endocrinology and Metabolism (JCE&M) 2000. Vol 85. No. 4.

3. Zeiger MA, Thompson GB, Duh Q, et al. American Association Of Clinical

Endocrinologists and American Association of Endocrine Surgeons Medical

Guidelines for the Management of Adrenal Incidentalomas. Endocrine

Practice 2009; Volume 15(Supplement 1).

4. Management of Clinically Inapparent Adrenal Mass ("Incidentaloma"). National

Institutes of Health – State-of-the-Science Conference statement, February 4-6, 2002.

Available at: http://consensus.nih.gov/ta/021/021_intro.htm.

5. Moreira SG and Pow-Sang JM. Evaluation and Management of Adrenal

Masses. Cancer Control. 2002; 9(4). H. Lee Moffitt Cancer

Center and Research

Institute. Inc.

6. Diab DL, Faiman C, Siperstein AE et al. Virilizing adrenal ganglioneuroma in a

woman with subclinical Cushing's syndrome. Endocrine Practice. 2008 Jul-Aug:

14(5): 584-7.

7. Kenny FM, Stavrides A, Voorhess ML et al. Cushing's syndrome associated with

an adrenal neuroblastoma. A case in an infant with clinical, pathological and adrenal

cortical and medullary hormone excretion studies. Am J Dis Child. 1967 May;113(5):

611-5.

8. Dahms WT, Gray G, Vrana M et al. Adrenocortical adenoma and

ganglioneuroblastoma in a child. A case presenting as Cushing's syndrome with

virilization. Am J Dis Child. 1973 Apr; 125(4): 608-11.

9. Corcuff JB, Deminiere C, Trouillas J et al. Ectopic Cushing's syndrome due to an

adrenal ganglioneuroma. Horm Res Paediatr. 2010; 73(5): 405-8. Epub 2010 Apr 14.

Author Information

S. Bontha, MBBS, MRCP (UK). MD

N. Sanalkumar, MBBS, MD

Department of Diabetes and Endocrinology, Al Zahra Pvt. Hospital

M. Istarabadi, MD, FRCS (IRL)

Department of Urology, Al Zahra Pvt. Hospital

Gerd Lepsien, MD

Department of Surgery, Al Zahra Pvt. Hospital

G.M. Abdul Aal ., MBBCh, MD (Path), MSc (Path)

Department of Pathology, Al Zahra Pvt. Hospital