

Pulmonary Arteriovenous Malformations And Osler Weber Rendu Syndrome: An Unusual Cause Of Dyspnea

H Amin, A Friere, C Lal, M Pugazhenth

Citation

H Amin, A Friere, C Lal, M Pugazhenth. *Pulmonary Arteriovenous Malformations And Osler Weber Rendu Syndrome: An Unusual Cause Of Dyspnea*. The Internet Journal of Pulmonary Medicine. 2004 Volume 5 Number 2.

Abstract

Approximately 70% of all PAVMs occur in association with Hereditary Hemorrhagic Telangiectasia (HHT) and more than 20% of patients with HHT develop pulmonary arteriovenous malformations. Pulmonary arteriovenous malformations, usually asymptomatic, however, could present in the fourth to sixth decade of life with the development of congestive heart failure, respiratory failure with cyanosis, life threatening cerebrovascular complications including stroke and cerebral abscesses as their first manifestations. Patients with HHT are at 35% or more risk of developing these arteriovenous malformations especially if at least one of the family member have already been diagnosed with these lesions. Screening for PAVMs in asymptomatic patients with HHT is warranted and remains crucial for early detection and prevention of complications especially when a family member has already been diagnosed with these malformations. We present here a case report of a patient with pulmonary arteriovenous malformations secondary to Hereditary Hemorrhagic Telangiectasia, who was treated successfully with coil embolization.

ABBREVIATIONS

PAVM; Pulmonary ArterioVenous Malformations.

HHT; Hereditary Hemorrhagic Telangiectasia.

TCET; Transcatheter Coil Embolization Treatment,

NYHA; New York Heart Association

INTRODUCTION

Pulmonary arteriovenous malformations (PAVM), also known as lung hemangiomas or pulmonary arteriovenous aneurysms are an uncommon clinical problem, which can be congenital or acquired. Approximately 70% of all PAVMs occur in association with Hereditary Hemorrhagic Telangiectasia (HHT) and more than 20% of patients with HHT develop pulmonary arteriovenous malformations. We present here a case of a 39 years old female patient with HHT and multiple pulmonary PAVMs, who was successfully treated with coil embolization.

CASE REPORT

A 39 year old Caucasian female patient with a history of HHT presented with dysnea on exertion for one and a half years. She did not have any breathing difficulty in the past but her symptoms had now progressed to the point that she was short of breath even on speaking. She denied orthopnea or paroxysmal nocturnal dysnea and stated that lying supine made her feel much better as opposed to sitting up or

standing. Her dysnea was classified as NYHA class III at the time of presentation. She had been diagnosed with HHT several years ago, following repeated nosebleeds.

Her physical examination revealed multiple telangiectasias on her abdomen, medial aspect of her right arm and anterior thighs. Her cardiovascular and respiratory system examinations were within normal limits. However, she was found to have significant orthodeoxia as her oxygen saturation dropped from 89% in supine position to 83% on sitting up after 2-3 minutes. Her chest radiograph revealed enlargement of the pulmonary artery trunk and the right main pulmonary artery along with a 1-1/2 X 1-1/2 cm nodule in the right lower lobe. A comparison of her most recent arterial blood gas to the one she had had 12 years ago showed worsening of the PO₂ from 67 mm Hg to 61 mmHg on room air. Likewise, during the same time period, her Dlco dropped from 89% to 70 % predicted. Spirometry revealed normal lung volumes.

In view of the platypnea-orthodeoxia and family history of PAVMs associated with HHT, a provisional diagnosis of PAVMs associated with HHT was made.

Further evaluation with a CT angiogram revealed multiple PAVMs with feeding arteries and draining veins identified for each lesion. In the left lung, three peripheral AVMs and one central AVM were identified. In the right lower lobe,

two peripheral AVMs and one large central AVM were identified.

Figure 1

Figure 1: CT Angiogram Showing PAVMs in the middle and lower lobes of the right lung

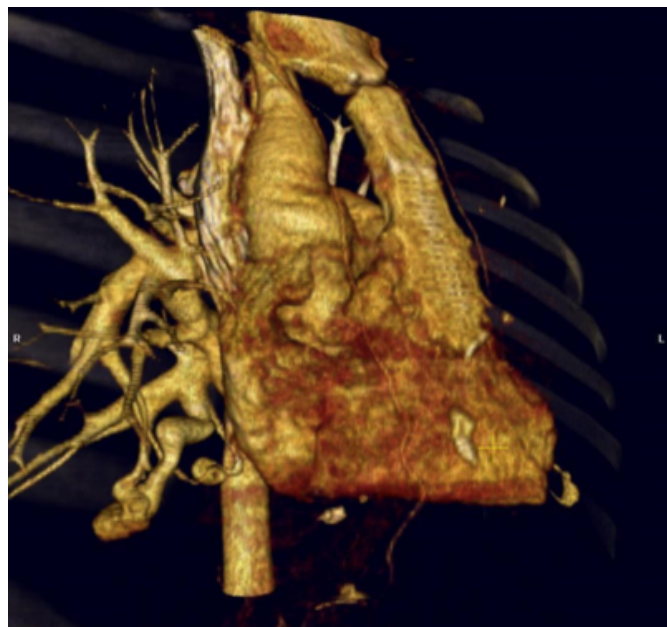
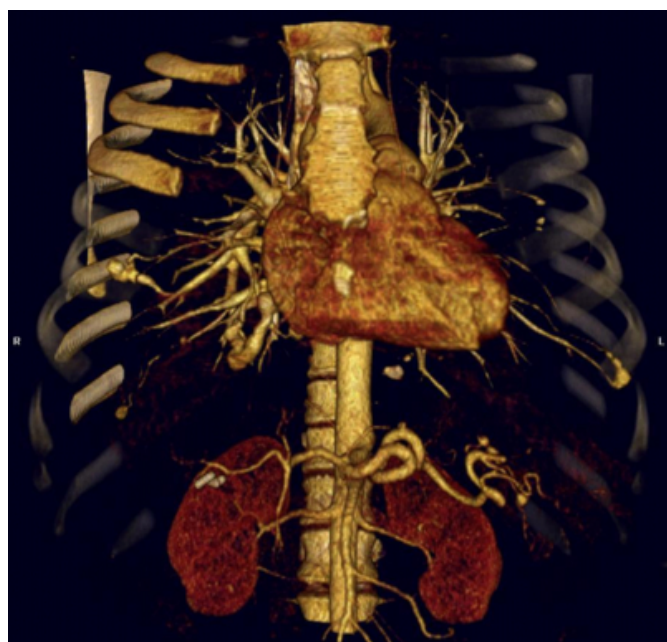

Figure 2

Figure 2: CT Angiogram Showing PAVMs in the middle and lower lobes of right lung, and PAVM in the lower lobe of left lung.



Coil Embolization of each identifiable PAVM was done by an interventional radiologist with no periprocedural

complications. Her subsequent hospital course was uncomplicated. A repeat arterial blood gas done one hour post procedure showed improvement in PO₂ from 61 mm Hg to 85 mm Hg on room air. On subsequent follow-up visits she showed significant subjective improvement, maintenance of PO₂ and correction of orthodeoxia.

Figure 3

Figure 3: Insertion of Catheter tip into the right pulmonary artery.

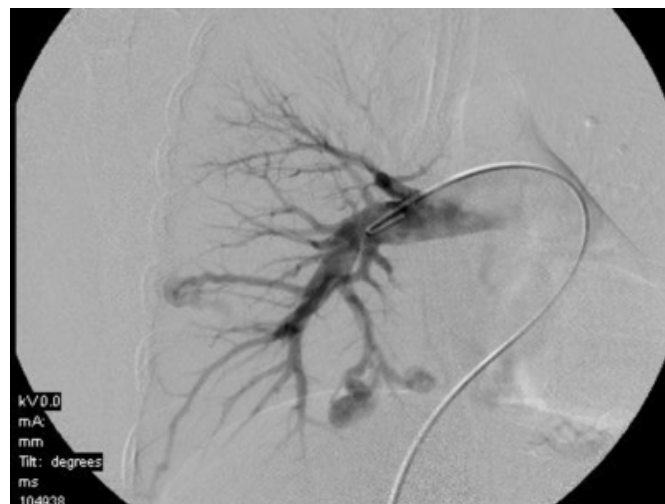


Figure 4

Figure 4: Transcatheter Coil Embolization of PAVMs in the right lung

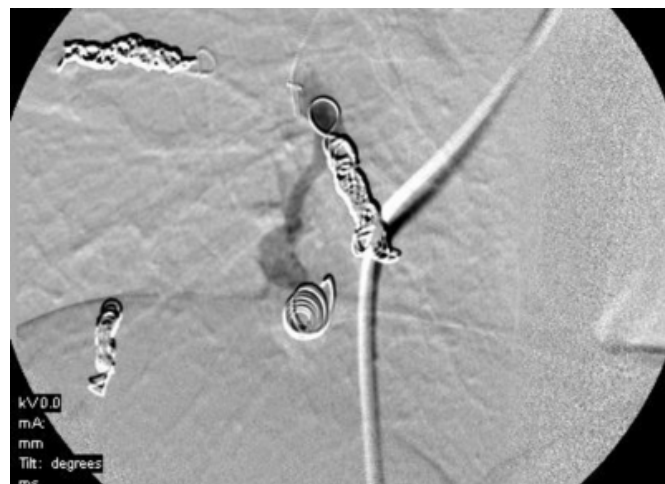
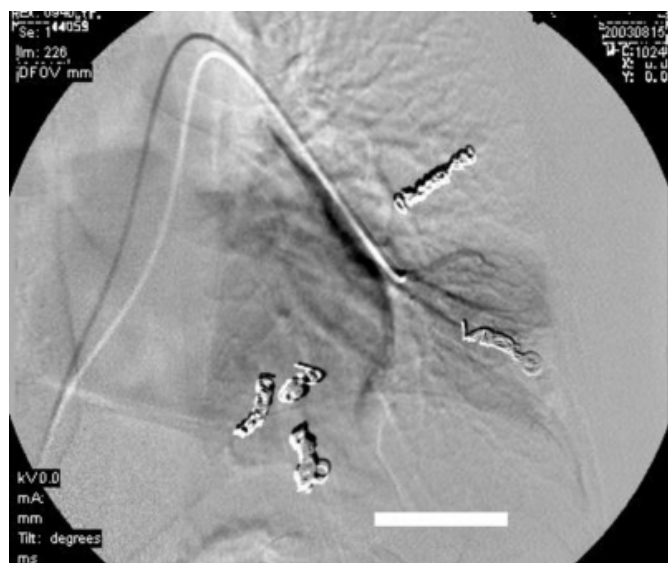

Figure 5

Figure 5: Transcatheter Coil Embolization of PAVMs in the left lung



DISCUSSION

The incidence of PAVMs has been variably reported as 3.2 cases/year (Mayo Clinic, 1972)⁽¹⁾ to 4.5 cases/year (Mayo clinic, 1981)⁽²⁾. PAVMs occur twice as often in females as in males. Approximately 15%-35% patients with HHT have PAVMs⁽³⁾. HHT, also called Osler-Weber-Rendu syndrome, is an autosomal dominant disorder, which presents with arterio venous malformations in skin, mucous membranes and visceral organs⁽⁴⁾. Mutations in the gene for Endoglin⁽⁵⁾ and activin receptor- like kinase1 are believed to cause HHT1 and HHT2 respectively⁽⁶⁾. HHT families with endoglin mutations appear to have a higher incidence of PAVMs⁽⁷⁾.

53%-70% of PAVMs occur in the lower lobes⁽⁸⁾. Most patients are symptomatic between the fourth to sixth decades of life, however, in their early life, patients could present with severe cyanosis, congestive heart failure or respiratory failure⁽⁹⁾. In patients with large or multiple PAVMs, dyspnea is found to be a very common symptom with finding of platypnea in some patients as well⁽⁹⁾. Stroke or massive fatal hemoptysis could be the initial presentation of PAVMs⁽¹⁰⁾. Not uncommonly they are associated with cerebrovascular accidents and brain abscesses with an incidence of approximately 10-15%^(9,11). Therefore, cryptogenic stroke in a young adult necessitates evaluation for the possibility of PAVMs in a previously undiagnosed patient⁽¹²⁾.

Screening for HHT and PAVMs is recommended for all the family members of patients with HHT⁽⁹⁾ and remains critical, as asymptomatic patients do not exclude clinically significant PAVMs and should have prophylactic antibiotics prior to dental and other surgical procedures to minimize risk of cerebral embolic abscesses.^(9,11, 13).

A practical approach would be to screen patients initially with chest radiograph⁽¹¹⁾, followed by Shunt measurement by 100% oxygen method. A PaO₂ of > 90 mm Hg and a SO₂ > 96.5% rule out any significant shunt, while a PaO₂ < 85 mm Hg or a SO₂ < 96% indicate a potential shunt fraction of > 5%.⁽⁹⁾ Significant shunt fraction measurement of >5% necessitate workup by Contrast Echocardiography (sensitivity 92% with negative predictive value 97%^(9,11)). Further evaluation can be done by either pulmonary angiography or CT scan, prior to coil embolization or surgical resection⁽⁹⁾.

All symptomatic PAVMs with a size greater than 2 cm and with feeding arteries greater than 3mm in diameter should be treated, either by surgery or embolotherapy^(9,14)

Transcatheter coil embolization (TCET) has become the treatment of choice replacing surgical intervention^(11,14) and has shown significant reduction in right-to-left anatomic shunt fraction with a low complication rate⁽¹⁵⁾. Better exercise capacity and improvement in hypoxemia has been shown in patients undergoing TCET^(11,14). Contrast echocardiography remains positive even after successful coil embolization treatment,^(9,16) therefore, in patients undergoing TCET and post procedural persistence of right to left shunts with high risk of embolic events, surgery might be indicated⁽¹⁴⁾. Post procedure longitudinal monitoring of arterial blood gases in patients with HHT associated PAVMs is warranted to look for recurrence of PAVMs in these patients⁽¹⁷⁾.

CONCLUSION

Embolotherapy for PAVMs avoids major surgery, general anesthesia and loss of lung parenchyma. It is the procedure of choice in patients with multiple or bilateral PAVMs and in patients who are poor surgical candidates. The benefits of embolotherapy are immediate and impressive with excellent long-term prognosis.

References

1. Dines, D.E., R.A.Arms, P.E.Bernatz and M.R. Gomes, 1974.Pulmonary AV fistula. Mayo Clin Proc.49: 460-465
2. Dines, D.E., J.B. Seward, P.E.Bernatz.1983.Pulmonary AV fistula. Mayo Clin Proc.58: 176-181.

3. Vase P., M.Holm., H.Arendrup.1985.Pulmonary AV fistulas in HHT.Acta Med Scand.218: 105-109.
4. H. Plauchu, J. -P. de Chadarevian, A. Bideau and J. -M. Robert.1989.Age related clinical profile of HHT in an epidemiologically recruited population. Am J. Med Genet.32: 291-297
5. McAllister., K.A.et al 1994.Endoglin, a TGF-beta binding protein of endothelial cells, is the gene for HHT1.Nat Genet 8:345-351.
6. Johnson D.W.et al.1996.Mutations in the activin receptor-like kinase 1 gene in HHT2.Nat Genet. 13: 189-195.
7. Berg, J.N.et al.1996.Clinical heterogeneity in HHT: are PAVMs more common in families linked to endoglin? J.Med Genet.33: 256-257.
8. Bosher, L.H.Jr., D.A. Blake and B.R. Byrd.1959.An analysis of the pathologic anatomy of PAVM's with particular reference to the applicability of local excision. Surgery 45:91-104.
9. James R. Gossage and GHassan Kanj, Pulmonary Arteriovenous Malformations A State of the Art Review. Am J Respir Crit Care Med Vol 158.pp 643-661, 1998.
10. Anette Drophse Kjeldsen, MD, PhD; H. Oxhoj, MD, MSc; P.E Andersen, MD; B. Elle, MD; J.P.Jacobsen, MD and P.vase, MD, MSc. Screening Procedures and Pulmonary Angiography in patients with Hereditary Hemorrhagic Telangiectasia. Chest. 1999; 116:432-439.
11. Nicholas W. Morrell, M.D. Screening for Pulmonary Arteriovenous Malformations. American Journal of respiratory and critical care medicine vol 169. pp.978-979, (2004)
12. Retnakaran RR, Faughnan ME, Chan RP, Pugash RA, O'Connor PW, Chow CM. Pulmonary Arteriovenous Malformations: A rare treatable cause of Stroke in young adults. Int J Clin Pract.2003 Oct; 57(8): 731-3
13. Vincent Cottin, Henri Plauchu, Jean-Yves Bayle, Martine Barthelet, Didier Revel, and Jean-Francois Cordier. Pulmonary Arteriovenous Malformations in patients with Hereditary Hemorrhagic Telangiectasia. AM J Respir Crit Care Med Vol169. pp994-1000, 2004
14. Claire L Shovlin, Michelle Letarte, Hereditary Heamorrhagic Telangiectasia and pulmonary arteriovenous malformations: issues in clinical management and review of pathogenic mechanisms. Thorax 1999; 54:714-729(August)
15. P. Gupta, C. Mordin, J. Curtis, J.M.B.Hughes, C.L.Shovlin and J.E.Jackson, Pulmonary Artertiovenous Malformations: Effect of Embolization on Right-to-Left shunt, Hypoxemia and exercise tolerance in 66 patients. AJR 2002; 179:347-355
16. Lee WL, Graham AF, Pugash RA, Hutchison SJ, Grande P, Hyland RH, Faughnan ME. Contrast echocardiography remains positive after treatment of pulmonary arteriovenous malformations. Chest .2003 Feb; 123(2): 320-2
17. ChaoHS, Chern MS, Chen YC, Chang SC. Recurrence of Pulmonary arteriovenous malformations in a female with hereditary hemorrhagic telangiectasia. Am J Med Sci. 2004 May; 327(5): 294-8

Author Information

Hassan Amin, M.D.

Resident Physician, Department of Medicine, University Of Tennessee Health Science Center

Amado X. Friere, M.D.

Division Chief, Department of Pulmonary and critical care medicine, University Of Tennessee Health Science Center.

Chitra Lal, M.D.

Fellow, Pulmonary and Critical Care, University Of Tennessee Health Science Center

Muthiah Pugazhenti, M.D.

Assistant Professor of Medicine, Division of Pulmonary and Critical Care, University Of Tennessee Health Science Center