

Sensitivity Of Fluorescent Microscopy In Detecting Mycobacterium Leprae In Tissue Sections

A N., A Nagarajappa, D Prabhu

Citation

A N., A Nagarajappa, D Prabhu. *Sensitivity Of Fluorescent Microscopy In Detecting Mycobacterium Leprae In Tissue Sections*. The Internet Journal of Pathology. 2010 Volume 11 Number 2.

Abstract

Detection of Mycobacterium leprae in tissue sections by Modified Fite- faraco method was compared with the sensitivity of fluorescence microscopy in tissue sections .Auramine- Rhodamine fluorescent stain as recommended by Kuper & May's was used with minor alterations in deparaffinization to obtain optimal fluorescence. Out of 70 biopsies studied, 63 showed organisms by fluorescent method and 16 showed organisms by modified Fite -faraco method. We found that fluorescent stain was superior to modified Fite- faraco in detecting leprae bacilli in tissue sections particularly in paucibacillary cases where bacillary load is much low. The speed of observation and rapidity of finding the bacilli by fluorescent microscopy also reduced observer's fatigue. Hence fluorescent microscopy can be used as a main tool to detect the bacilli in paucibacillary cases.

INTRODUCTION

Leprosy is a chronic infectious disease caused by mycobacterium leprae which express itself in different clinico pathological forms & morphological patterns depending on immune status of the host. As leprosy causes permanent and progressive physical deformity in the patients, early and accurate diagnosis is important for effective treatment and control. The clinical diagnosis of leprosy has been confirmed by diagnostic procedures like slit skin smears and skin biopsy.

Modified Fite- faraco technique is the routinely used method to demonstrate mycobacterium leprae bacilli in tissue sections. This method is tedious, time consuming and lead to observer's fatigue. Fluorescent microscopy has been used for rapid screening, to reduce observer's fatigue and also to increase sensitivity. Hence fluorescence microscopy has been used by some to ensure easy detection and treatment of leprosy to prevent deformity.

Nayak et al⁽⁴⁾ found that fluorescent staining method was more sensitive than modified Fite- faraco in accordance with Jariwala & Kelkar⁽³⁾ particularly in paucibacillary cases. Conversely, Lacordaire⁽⁵⁾ found that the modified Fite- faraco method to be superior, compared with fluorescent staining. However views differ about the sensitivity of fluorescent microscopy in detecting mycobacterium leprae in tissue sections.

This study was carried out on skin biopsies of patients clinically suspected of having leprosy and sensitivity of fluorescent microscopy was compared with modified Fite- faraco method to detect mycobacterium leprae bacilli in tissue sections.

MATERIALS AND METHODS

Seventy patients clinically suspected of leprosy were studied for a period of two years duration. The disease was classified based on clinical features, histopathological findings, slit skin smears and modified Fite- faraco method into indeterminate leprosy, tuberculoid leprosy, borderline tuberculoid leprosy, mid -borderline leprosy, borderline lepromatous leprosy and lepromatous leprosy.

After detailed general local examination, the site of biopsy was selected. The entire skin biopsy was submitted for routine processing and embedded in paraffin wax. From each block, ribbons containing 12 serial sections each 5 microns were taken.

Two sections were taken for routine haematoxylin and eosin staining and 5 each for fluorescent and Fite- faraco stain. For fluorescent staining, sections were taken on clean scratch free glass slides with out egg albumin or any other adhesive. These tissue sections were stained with fluorescent dye (Auramine – Rhodamine) as recommended by Kuper and May's⁽²⁾ with minor alterations in deparaffinization as modified by Nayak et al.⁽⁴⁾

The following staining procedure was followed:

1. Deparaffinization was performed with 1 part peanut oil and 3 parts xylene mixture; two changes of 10 minutes each and then blotted carefully.
2. The slide was stained with filtered rhodamine-auramine mixture at 650C for 15 minutes.
3. The slide was washed under running water for 2 minutes.
4. Decolourization was performed in 0.5 % hydrochloric acid in 70 % ethanol for 2 minutes.
5. The slide was washed under running water for 2 minutes.
6. Counterstaining was performed with 0.5 % aqueous potassium permanganate for 2 minutes.
7. The slide was washed under running water for 2 minutes.
8. Dehydration was performed in absolute alcohol by dipping the slide just once and blot dried immediately.
9. The slide was mounted with glycerol using a scratch- free cover slip.

Tissue sections were screened immediately with a Carl zeiss Microscope, with HBO 50 high pressure mercury short – arc discharge. Excitation was with blue violet rays obtained with BG 12 primary filters; an Abbe condenser was also used. Skin biopsy from a normal individuals were used as controls. All sections were screened with 10 x, 40 x and 100 x objectives. Only solid fluorescing organisms were considered for a definitive diagnosis, excluding bacillary fragments.

The typical morphology of the bacilli showing bright yellow fluorescence emitted by bacilli when interspersed with the artifact was considered the diagnostic criteria for labelling the biopsy positive for Mycobacterium leprae (Fig 1, 2, 3,4).

Figure 1

Fig 1: Fluorescent Stain: scattered bacilli in Borderline tuberculoid leprosy X400

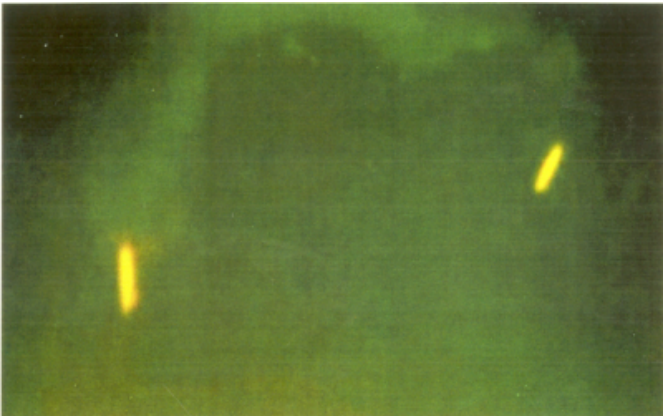


Figure 5

Table 1: Comparison of positivity rates of modified Fite – faraco stain with fluorescent stain on histological diagnosis

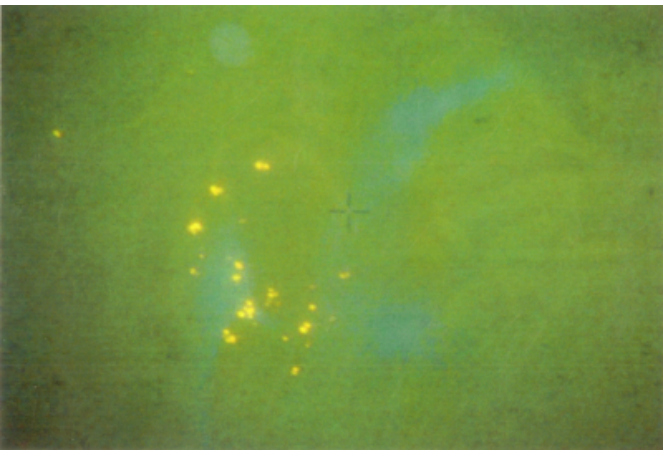


Figure 3

Fig 3: Fluorescent Stain: scattered bacilli in Tuberculoid leprosy X400

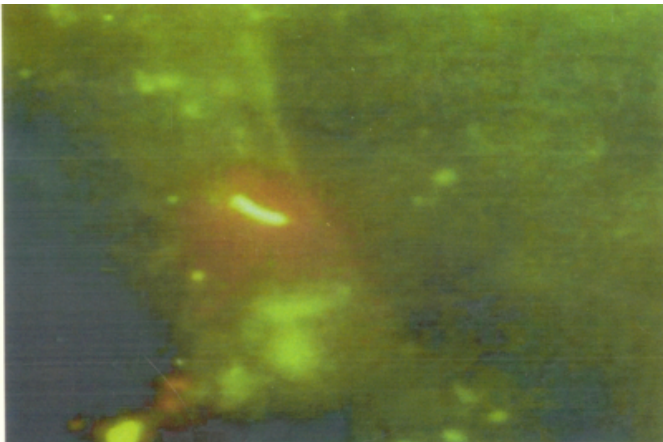
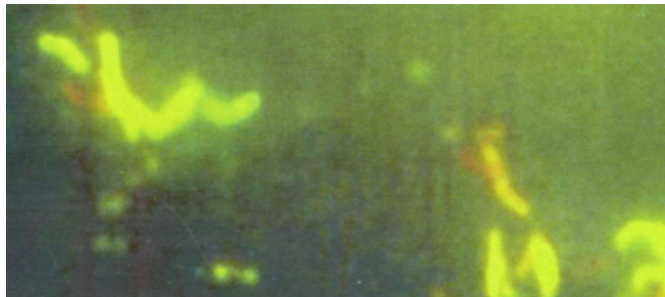


Figure 4

Fig 4: Fluorescent Stain: Bacilli arranged in clusters in Borderline lepromatous leprosy X400



Modified Fite -faraco stain was performed on serial sections and observed under 100 x objective and the findings were noted.

The Excel and SPSS software packages were used for data entry and analysis. The usefulness of fluorescent stain and modified Fite- faraco stain for identifying mycobacterium leprae in tissue sections in different histological patterns of leprosy was evaluated using Bayesian method in terms of True Positive (TP), False Positive (FP), True Negative(TN) and False Negative(FN) . The sensitivity, specificity, Positive predictive value (PPV) and Negative predictive value (NPV) were calculated.

RESULTS AND ANALYSIS

Comparative analysis of positivity rates of modified Fite - faraco stain and fluorescent stain on histological diagnosis shows that positivity rate of fluorescent stain was superior to modified Fite- faraco (Table 1) . The sensitivity and specificity of the fluorescent stain is shown in (Table2). Sensitivity of fluorescent stain in indeterminate leprosy, tuberculoid leprosy, borderline tuberculoid leprosy and borderline borderline leprosy was 100%. Where as in borderline lepromatous leprosy and lepromatous leprosy sensitivity could not be assessed as all the cases were positive in both the staining methods used.

Figure 6

Table 2: Histopathological findings and correlation of modified Fite – Faraco stain with fluorescent stain – An evaluation

Histopathological diagnosis	Sensitivity	Specificity	PPV	NPV
Indeterminate leprosy	100.0	15.38	8.3	100.0
Tuberculoid leprosy	100.0	0.00	16.7	50.0
Borderline Tuberculoid leprosy	100.0	0.00	7.1	50.0
Borderline Borderline leprosy	100.0	22.2	30.0	100.0
Borderline Lepromatous leprosy	--	100.0	--	--
Lepromatous leprosy	--	100.0	--	--
Total	100.0	25.4	12.9	100.0

{image:6}

DISCUSSION

Leprosy continues to be a major public health problem in India with annual new case detection rate of 1.43 per 1,00,000 population⁽¹⁾. Since leprosy presents with varied clinical features diagnosis is difficult and even slit skin smears yield poor results. Thus for accurate diagnosis and typing histopathology is inevitable.

We found that the sensitivity of fluorescent stain was 100% when compared to modified Fite-faraco in detecting M.leprae in tissue sections. These results were similar to the finding of Nayak⁽⁴⁾, Jariwala⁽³⁾, Bhatia⁽¹⁰⁾ and Mansfield et al.⁽⁶⁾

Bhatia et al⁽¹⁰⁾ in his study on 65 skin biopsies taken from treated leprosy patients were negative by modified Fite-faraco. Fluorescent microscopy detected M.leprae in 64 cases. They described the presence of granular forms of the bacilli in paucibacillary cases. It was possible that these granular forms were old decrepit, which increased the sensitivity in their study. We considered only solid fluorescing forms of M. leprae bacilli for diagnosis in accordance with Nayak et al⁽⁴⁾. We did find out that even single few scattered leprae bacilli in paucibacillary cases was made out by fluorescent method which otherwise would be missed by modified Fite-faraco.

Lacordaire⁽⁵⁾ observed that modified Fite- faraco method to be superior compared with fluorescent staining method. Presence of artifacts from albumin and phenol was found to be a major problem. This problem was not faced in the present study as no adhesive material was used but artifacts from phenol could not be eliminated. The typical morphology of the bacilli showing bright yellow fluorescence emitted by bacilli was easily differentiated

from artifacts that had pale yellow fluorescence.

Nayak et al⁽⁴⁾ carried out their study on 56 skin biopsies with minor alterations in Kuper and Mayo's⁽²⁾ staining method. They modified staining method using mixture of 1 part peanut oil and 3 parts xylene (2 changes of 10 minutes each) instead of 1 part peanut oil and 2 parts xylene mixture for complete deparaffinization. The staining period for the Auramine-Rhodamine stain at 65°C for 15 minutes which gave a better fluorescence than that obtained by staining at 60°C for 10 minutes. For better differentiation decolourization was done with 0.5% hydrochloric acid in 70% ethanol instead of 0.5% aqueous hydrochloric acid. Similar staining technique was employed in our study. We noticed that the positivity rate was much more with fluorescent stain when compared to modified Fite-faraco stain in paucibacillary leprosy.

We agree with the view of Nayak⁽⁴⁾, Jariwala and Kelkar⁽³⁾ that fluorescent method is superior to the modified Fite-faraco in detecting *M. leprae* in tissue sections particularly in paucibacillary cases.

We thought it is necessary to screen all five sections because all slides did not show *M. Leprae* bacilli and was detected in few cases, particularly true for paucibacillary cases. This explains the high sensitivity of our study and the study conducted by Nayak et al.⁽⁴⁾ The problems that we faced during the study were the detachments of tissue sections from the slide since no adhesive material was used and degradation of fluorescence after 24 hours. It could be emphasized that photograph to be taken within 24 hours for proper imaging

The speed of observation and the rapidity of finding the bacilli by fluorescent microscopy reduced observer's fatigue because the bright bacilli stand out in dark background. Tissue sections when failed to detect *M. leprae* bacilli by modified Fite – faraco stain were detected by fluorescent method in paucibacillary cases. We conclude that fluorescent method has advantage over modified Fite- faraco method in detecting *M. leprae* in tissue sections and can be used as a gold standard tool particularly in paucibacillary cases.

References

1. Abulafia J, Viguale RA. Leprosy: Pathogenesis updated. *International Journal of Dermatology* 1999; 38: 321-334
2. Kuper SWA and Mayo, JR. Detection of acid fast organisms in tissue sections by fluorescence microscopy. *Journal of pathology and bacteriology* 1960; 79: 59-68
3. Jariwala HJ and Kelkar SS. Fluorescence Microscopy for detection of *Mycobacterium leprae* in tissue sections. *Internal Journal of leprosy*. 1979; 47: 33-36
4. Sunil V Nayak, AS Shivrudrappa, Mukkamil AS: Role of Fluorescence Microscopy in detecting *Mycobacterium leprae* in tissue sections. *Annals of Diagnostic pathology* 2003; 7: 78
5. Locardaire Lopes de Faria. Fluorescent staining of *mycobacterium leprae* in tissue sections comparison with Fite- Faraco internal procedure. *Internal Journal of leprosy*. 1974; 42: 52-54
6. Mansfield RE; An improved method for the Fluorochrome staining of *Mycobacterium* in tissues and smears. *Am J Clin Path* 1970; 53: 394-406
7. Hagemann P.K.H. Fluorescence of *Mycobacterium tuberculosis* and *Mycobacterium Leprae* with borderline sulphate solution. *Dtsch Med. Wochenschr.* 1973; 63: 514- 518
8. Gohar.M.A. A note on fluorescence microscopy in the diagnosis of leprosy. *Journal of tropical medicine and hygiene*. 1952; 55: 156-157
9. Nerurkar, R.V. and Khanolkar, V.R. Use of fluorescence microscopy in diagnosis of leprosy. In; *leprosy in theory and practice*, 1ST edition. R.G. Cochrane ed., Bristol: Jhon Wright and sons Ltd. 1959: 373
10. Bhatia VN, Rao S, Saraswathi G; Auramine staining in histopathology sections. *Indian J Lepr* 1987; 59: 386-388

Author Information

Ashalatha. N., MBBS, MD (PATHOLOGY)

Assistant Professor, Department of Pathology, Bangalore Medical College and Research Institute (BMC&RI)

A.H. Nagarajappa, M.B.B.S, M.D

Professor and Head of the Department, Department of Pathology, Bangalore Medical College and Research Institute (BMC&RI)

D C Prabhu, M.B.B.S, M.D

Professor, Department of Pathology, Bangalore Medical College and Research Institute (BMC&RI)