

# Congenital Cystic Adenomatoid Malformation: A Case Study

H Fulghum, E Vasquez

## Citation

H Fulghum, E Vasquez. *Congenital Cystic Adenomatoid Malformation: A Case Study*. The Internet Journal of Advanced Nursing Practice. 2002 Volume 5 Number 2.

## Abstract

This paper examines a short case history of an infant born with a Congenital Cystic Adenomatoid Malformation (CCAM). CCAM is a rare congenital lung malformation representing 25% of congenital malformations and 95% of congenital lung lesions.<sup>1,2</sup> CCAM may be diagnosed in utero by ultrasound examination, or after birth with the presentation of respiratory distress like symptoms. Differential diagnosis includes diaphragmatic hernia, pulmonary sequestration, bronchogenic cysts, and congenital lobar emphysema. Because most CCAM lesions are manageable with the proper assessment, diagnosis, and interventions, it is vital that members of the neonatal health care team be knowledgeable about this malformation. The natural history, differential diagnosis, pathophysiology and treatment of CCAM are discussed.

## INTRODUCTION

Congenital Cystic Adenomatoid Malformation (CCAM) first identified in 1949 by Ch'in and Tang, is a rare congenital malformation of the lung representing 25% of congenital lung malformations and 95% of congenital lung lesions.<sup>1,2</sup> This lesion occurs more often in males (1.8:1), and is primarily unilateral, but may occur bilaterally.<sup>3</sup> Associated anomalies are rare. Since the technological advancement of ultrasound examination, CCAM has been increasingly diagnosed on routine prenatal examinations. Some CCAM lesions present only at birth with respiratory distress symptoms but are confirmed by an abnormal chest radiograph or a more definitive computed tomography scan. However, there are CCAM lesions that are not identified on routine ultrasound examination, and present without symptoms at birth. These lesions may not be identified until later in life.

Whether diagnosed prenatally or postnatally, and with or without symptoms, most CCAM lesions are manageable with the proper assessment, diagnosis, and interventions. Moreover, with the advent of fetal therapy, infants with the more severe cases of CCAM are now surviving.

## CASE HISTORY

Baby boy C was born to a para 2 gravida 1 mother. The mother's prenatal history was unremarkable. On a routine prenatal ultrasound, a cystic lung lesion was noted in the left

lower lobe of the lung. From ultrasound examination, the cyst appeared to measure 3cm by 4cm. The fetus and cyst were followed in utero by serial ultrasound examination until the time of delivery. No complications were documented throughout the pregnancy.

Infant C was delivered vaginally at 38 2/7 weeks gestation, the amniotic fluid was clear and odorless. The Apgar scores were 8 and 9 at 1 and 5 minutes respectively. The birth weight was 3260 grams. The neonatology team was available at the delivery, but no resuscitation measures were needed. Infant C was admitted to the Neonatal Intensive Care Unit (NICU) for further evaluation, but stayed less than 24 hours. A computed tomography scan identified a lesion occupying half of the left lower lobe of the lung. Infant C showed no signs of respiratory distress and began nipping feeds without difficulty. The infant was evaluated by the pediatric surgery team, and transferred to the newborn nursery at approximately 24 hours of life, and then discharged to home.

At 3 months of age, Infant C was admitted back into the hospital for intrathoracic surgery to resect the congenital cystic lung lesion. Infant C had no documented issues during these 3 months at home. Infant C underwent general anesthesia, and an epidural catheter was placed. A thoracotomy and lobectomy were performed with subsequent placement of a chest tube. The infant was extubated in the operating room, sent to the post-anesthesia

care unit, and admitted to the level II nursery. Infant C's hospital course was uneventful. The infant received pain control per the epidural catheter with ibuprofen supplementation every 6 hours when necessary. The chest tube was removed on day 3 post-op; the epidural catheter was removed 3 hours after the chest tube. Tylenol with codeine was administered every 4 hours as needed after the epidural catheter was removed. On post-op day 4, infant C had minimal pain, was nippleing well, and was discharged home with a follow-up appointment scheduled in 2 weeks. Histologic examination of the tissue removed from the lung confirmed a clinical diagnosis of CCAM.

### **PATHOPHYSIOLOGY**

Congenital cystic adenomatoid malformation is an uncommon developmental lung anomaly that is thought to occur early in fetal lung development, around the fifth to the eighth weeks of gestation. It is suspected that there is an arrest in normal fetal pulmonary maturation caused by primary bronchial atresia or failure of normal bronchial segmentation.<sup>4</sup> This leads to the subsequent development of dysplastic bronchopulmonary tissue distal to the affected segment. This dysplastic bronchopulmonary tissue consists of numerous, intercommunicating, bronchioluslike structures of variable size with many immature cells surrounded by a rim of lung tissue.<sup>3</sup> The abnormal morphology of the dysplastic lung tissue allows for the differentiation between the healthy lung tissue that is seen on a fetal ultrasonography.

The formation of the dysplastic lung tissue can result in pulmonary hypoplasia or pulmonary agenesis in the fetus. A large cyst can cause a mediastinal shift which can exert pressure on the heart and inferior vena cava impeding venous return. If the pressure is prolonged and severe, nonimmune fetal hydrops may occur in the fetus. Polyhydramnios may also be present due to compression of the fetal esophagus. At birth, respiratory distress develops not only from the lung hypoplasia or agenesis, but also because the abnormally present cysts can fill with air and compress the surrounding healthy lung tissue after an infant takes his first breaths.<sup>3</sup>

Histologic classification of CCAM was first described in 1977.<sup>5</sup> The Stocker classification system divides the lesions into three groups. The most commonly seen CCAM lesion is the Stocker type I, which accounts for 50%-70% of diagnosed cases.<sup>3,5</sup> This defect is composed of single or multiple large cysts (3 to 10 cm), that are confined to one

lobe, and are filled with air or fluid. It is not unusual for these lesions to communicate with the bronchi. Only 11% of these lesions are complicated with associated anomalies.<sup>3</sup> It has been estimated that 90% of these patients survive.<sup>3,5</sup>

CCAM Stocker type II lesions are found in 18%-40% of diagnosed cases, and are composed of multiple evenly distributed, medium sized cysts (<2.0 cm) that resemble terminal bronchioles.<sup>3,5</sup> CCAM type II lesions have been associated with a higher incidence (50%) of other congenital anomalies.<sup>3</sup> These anomalies include renal agenesis, bilateral renal dysgenesis, pulmonary sequestration, and congenital heart disease.<sup>3,5</sup>

CCAM Stocker type III lesions represent 10% of diagnosed cases, and are usually a large, bulky lesion with evenly distributed small cysts. These cysts may occupy an individual lobe, or the entire lung. Mediastinal displacement is extremely common.<sup>3,5</sup>

### **DIFFERENTIAL DIAGNOSIS**

The differential diagnosis for fetal lung space occupying lesions include diaphragmatic hernia, pulmonary sequestration, bronchogenic cysts, and congenital lobar emphysema.<sup>2,10</sup> The majority of CCAM lesions are diagnosed at 16-22 weeks gestation on routine prenatal ultrasound examinations. The fetal lung tissues striking echogenicity easily allows for the diagnosis of a cystic lung lesions. Cystic lung lesions can be easy to identify but sometimes difficult to definitively diagnose. Invasive studies may be required to identify the malformation, and in some cases, the definitive diagnosis may not be made until surgery.

The differentiation of CCAM from the more common diaphragmatic hernia (CHD) may be challenging in an infant with respiratory distress and an abnormal chest radiograph. Diagnosing CHD can be done with careful ultrasound examination, noting the presence of abdominal contents in the chest cavity, or noting that a segment of the liver is past the diaphragm, as would occur in the presence of a right sided CDH.<sup>2</sup>

Pulmonary sequestration closely resembles CCAM and is defined as an immature lung tissue mass that does not communicate with the bronchial tree via an anatomically normal bronchus.<sup>2</sup> Like CCAM, pulmonary sequestration usually appears as a well-circumscribed, uniformly solid appearing mass in the fetal thorax. In some instances, the use of color flow Doppler ultrasonography can be very useful

since CCAM is usually supplied by the pulmonary artery, whereas a pulmonary sequestration receives its blood flow from an accessory artery via the aorta.<sup>2</sup>

Bronchogenic cysts are the most common cause of a cyst in the lung, and rarely presents in the neonate.<sup>3</sup> These cysts are found predominately on the mediastinum near the carina, are usually small in size, and appear as smooth, round, or oval masses on a chest radiograph. The cysts produce symptoms by airway compression with the tissue distal to the compression being atelectatic or emphysematous.

Congenital lobar emphysema (CLE), the most common neonatal cause of cystic malformation of the lung, is frequently associated with congenital heart disease (30%) such as tetralogy of Fallot, ventral septal defect, total anomalous venous return and patent ductus arteriosus.<sup>3</sup> CLE results with distal overinflation of otherwise normal tissue caused by partial airway obstruction. Most affected infants present with respiratory distress and symptoms of airway obstruction without cyanosis.<sup>3</sup> CLE can be distinguished from other cysts and malformations by the presence of bronchovascular markings extending to the periphery of the involved lobe and by atelectasis of adjacent tissues.<sup>3</sup>

### **TREATMENT**

Overall prognosis depends greatly upon the size of the lung mass and the pathophysiologic involvement.<sup>6</sup> When symptoms progress rapidly, mortality is high. Early identification of patients with CCAM is extremely important as it allows for prenatal counseling, potential fetal interventions, and birth planning at a tertiary care facility with access to a NICU.

Prenatal treatment of CCAM depends on the presentation of the symptoms. Fetal intervention is indicated when fetal hydrops is present. The mortality in patients who present with fetal hydrops is much higher (up to 68%) as compared to those without (30%).<sup>7,8</sup> Those infants with fluid filled cysts may benefit from the placement of a thoracoamniotic shunt under ultrasound guidance. This shunt allows the cysts to be drained with a resultant relief of pressure on the surrounding structures. Serial aspirations of large cysts may be beneficial, however, it has been documented that this method is less successful because of the rapid re-accumulation of fluid.<sup>2,9</sup> Fetal shunt placement has been associated with a mortality rate of 12.5% and with obstructions and dislocations in 29% of the cases.<sup>2</sup> Additional risks to these procedures include premature rupture of membranes, premature birth, hemorrhage,

infection, and injury to the fetus.<sup>2,6</sup>

In a fetus less than 32 weeks gestation that has predominately solid cystic lesions, a prenatal resection of the mass may be attempted.<sup>2</sup> However, the potential complications of preterm labor that can be induced by this surgical procedure must be considered.<sup>2</sup> One must weigh the risks and benefits of the presence of fetal hydrops versus the attempt at fetal surgical resection.

The literature recommends that a fetus less than 32 weeks gestation, without fetal hydrops, should be followed by serial ultrasound examination. It has been documented that a percentage (15%-60%) of these lesions may regress spontaneously in utero.<sup>6,9,10</sup> For those greater than 32 weeks without fetal hydrops, early delivery may be considered depending on the stability of the mother and fetus.

Congenital cystic adenomatoid malformation has a varied postnatal clinical presentation. The most common clinical presentation is progressive respiratory distress including tachypnea, grunting, retractions and cyanosis.<sup>2</sup> Upon physical examination, there may be prominence of the affected side of the chest, ipsilateral hyperresonance and decreased breath sounds, distant and shifted heart sounds, and hepatosplenomegaly from hyperexpansion of the thorax.<sup>2</sup> A chest radiograph may show a displacement of the mediastinum away from the affected side with loculated translucencies in the affected side which represent the CCAM (see figure 1).<sup>11</sup> If possible, a computed tomography scan is a more definitive diagnostic tool. Severe respiratory distress may warrant an emergent surgical resection. When symptoms are present at birth, surgical resection is almost always required.<sup>2</sup>

For those patients that have a CCAM diagnosed in utero on ultrasound examination, but have no symptoms at birth, the treatment modality is less clear. There is much controversy in the literature as to when is the best time and what is the best intervention for these patients. The classic regimen has been to remove all CCAM lesions due to the potential risk of secondary infection, and the possible progression to malignancy.<sup>6,10</sup> However, a few cases have been documented where the lesions have been monitored past the neonatal period without major sequelae.<sup>10</sup> Currently, the time of resection is left to the discretion of the pediatric surgeon involved in the case.

For those patients who have no symptoms at birth and have

no prenatal diagnosis of CCAM, diagnosis usually occurs later in life. Diagnosis may result as a part of a general work-up for recurrent pneumonia, as an incidental finding on the chest radiograph as part of a fever work-up, or for some other reason.<sup>7</sup> The treatment for these CCAM patients will most likely be dictated by the present clinical symptoms.

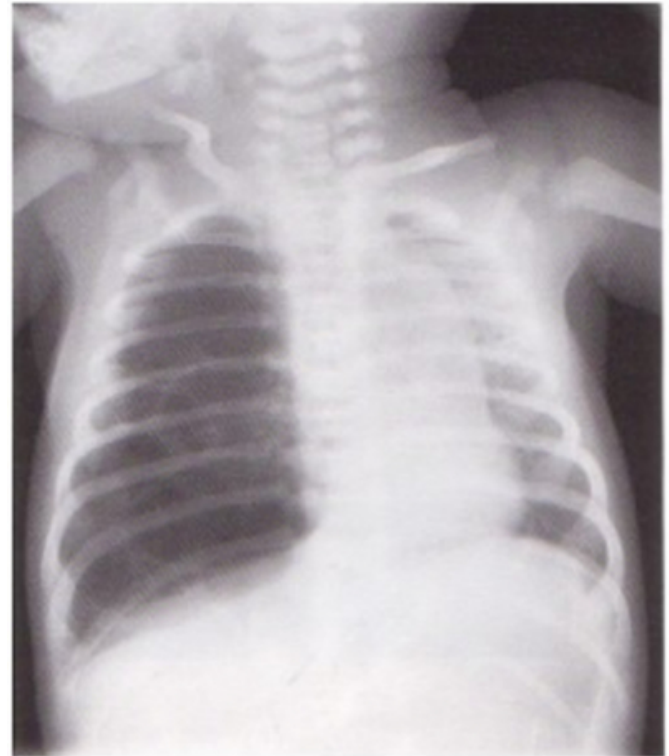
### **CLINICAL IMPLICATIONS**

With a prenatal diagnosis of CCAM, a healthcare team must be present that is skilled in neonatal stabilization and resuscitation, as respiratory distress is the first feature noted during the infant's assessment. As mentioned earlier, most CCAM lesions can be managed by the proper prenatal planning, assessment, diagnosis, and timely interventions. If mechanical ventilation is necessary, frequent assessment of breath sounds and serial chest radiographs are essential because the CCAM can become over distended by positive pressure ventilation.<sup>2</sup> These infants are also at risk and must be assessed for the development of pneumothorax, pneumopericardium, and pneumomediastinum.<sup>2</sup> Therefore, high frequency ventilation may be a consideration, and the patient should be closely monitored for signs of developing persistent pulmonary hypertension of the newborn.<sup>2</sup>

The reason for respiratory distress in an infant is obvious when a prenatal ultrasound has revealed a CCAM lesion. However, the diagnosis is not as clear when an infant presents with respiratory distress of an unknown origin. Being prepared with the knowledge for assessment, differential diagnosis and treatment of a CCAM may make a difference in the outcome of the infant involved. Vigilant assessment skills and interventions by the neonatal health care team in the NICU is critical in the proper management of a patient presenting with respiratory distress secondary to a congenital lung lesion.

### **Figure 1**

Figure 1: Displacement of mediastinum and heart to the left. Loculated translucencies in right middle and lower lung fields with flattened right diaphragm. (reprinted by permission from W. B. Saunders Company Ltd. Manual of Neonatal Emergency X-Ray Interpretation, 1994.)



### **References**

1. Chi'in KY, Tang MY. Congenital adenomatoid malformation of one lobe of the lung with general anasarca. *Archives of Pathology* 1949; 48:221-229.
2. Sittig SE, Asay GF. Congenital Cystic adenomatoid malformation in the newborn: two case studies and review of the literature. *Respiratory Care* 2000; 45(10):1188-1195.
3. Hansen T, Cooper T, Weisman L. Congenital Diseases Affecting the Lung Parenchyma. In *Contemporary Diagnosis and Management of Neonatal Respiratory Diseases*. Newton, PA: Handbooks in Health Care Co; 1995:164-179.
4. Moerman P, Fryns JP, Vandenberghe K, Devlieger H, Lauweryns JM. Pathogenesis of congenital cystic adenomatoid malformation of the lung. *Histopathology* 1992; 21:315-321.
5. Stocker JT, Madewell JE, Drake RM. Congenital cystic adenomatoid malformation of the lung: classification and morphologic spectrum. In *Human Pathology* 1977; 8:155-171.
6. Adzick NS, Harrison MR, Crombleholme TM, Flake AW, Howell LJ. Fetal lung lesions: management and outcome. *American Journal of Obstetrics and Gynecology* 1998; 179:884-889.
7. Sapin E, Lejeune V, Barbet JP, Carricaburu E, Lewin F, Baron JM, et
8. Congenital adenomatoid disease of the lung: prenatal diagnosis and perinatal management. *Pediatric Surgery International* 1997; 12:126-129.
9. dell' Agnola C, Tadini B, Mosca F, Colnaghi M, Wesley J. Advantages of prenatal diagnosis and early surgery for

congenital cystic disease of the lung. *Journal of Perinatal Medicine* 1996; 24:621-631.

10. Roggin KK, Breuer CK, Carr SR, Hansen K, Kurkchubasche AG, Wesselhoeft CW, Tracy TF, Luks FI. The unpredictable character of congenital cystic lung lesions. *Journal of Pediatric Surgery* 2000; 35:801-805.

11. Van Leeuwen K, Teitelbaum DH, Hirschl RB, Austin E, Adelman SH, Polley TZ, Marshall KW, Coran AG, Nugent

C. Prenatal diagnosis of congenital cystic adenomatoid malformation and its postnatal presentation, surgical indication, and natural history. *Journal of Pediatric Surgery* 1999; 34:794-8.

12. Meerstadt P, Gyll C. *Manual of Neonatal Emergency X-Ray Interpretation*. Philadelphia, PA: WB Saunders Company Ltd, 1994:147.

**Author Information**

**Hollie W. Fulghum, MSN, RN.**

School of Nursing, The University of Texas- Houston Health Science Center

**Elias Provencio Vasquez, PhD, RN, NNP.**

School of Nursing, University of Baltimore