

# Vaginal fibrolipoleiomyoma in a Great Pyrenees dog

M Woldemeskel

## Citation

M Woldemeskel. *Vaginal fibrolipoleiomyoma in a Great Pyrenees dog*. The Internet Journal of Veterinary Medicine. 2008 Volume 7 Number 1.

## Abstract

A submucosal vaginal mass was surgically removed from a 10 year old spayed Great Pyrenees dog, fixed in 10% buffered formalin and processed for routine histopathology. Microscopically, the mass contained bundles of smooth muscle cells interspersed by similar proportion of dense collagen fibers and islands of mature adipocytes. The smooth muscle cells stained strongly positive for smooth muscle actin and mildly to moderately for vimentin and desmin. Masson's trichrome stain demonstrated bundles of dense collagen fibers. The adipocytes stained uniformly positive for vimentin, variably for desmin and did not stain for S-100. Based on the histological and immunohistochemical findings the neoplasm is diagnosed as fibrolipoleiomyoma, a benign mixed mesenchymal tumor. To the author's knowledge, this report for the first time documents vaginal fibrolipoleiomyoma in dogs. The finding is discussed and compared with similar uterine neoplasm in humans.

## INTRODUCTION

Leiomyoma is a common tumor of vagina in bitches, and may be confused with fibroma, a less common neoplasm. Lipoma may sporadically occur in the wall of canine vagina<sup>8</sup>. Variants of these vaginal neoplasms with one or more combination (lipoleiomyoma, fibrolipoleiomyoma), however, are rare to absent in veterinary literature. Recently, cases of vulvar lipoleiomyoma in a 5 year old female Siberian husky<sup>9</sup> and uterine angiolipoleiomyoma in 11 years old cross bred Pomeranian bitch<sup>4</sup> were reported. Uterine lipoleiomyomas, fibrolipoleiomyomas and myolipomas have been reported in humans<sup>7</sup>. However, there is no report on human and canine vaginal fibrolipoleiomyomas. This report, for the first time, documents histopathological and immunohistochemical findings of a case of vaginal fibrolipoleiomyoma in a 10 year old spayed Great Pyrenees dog.

## CASE REPORT

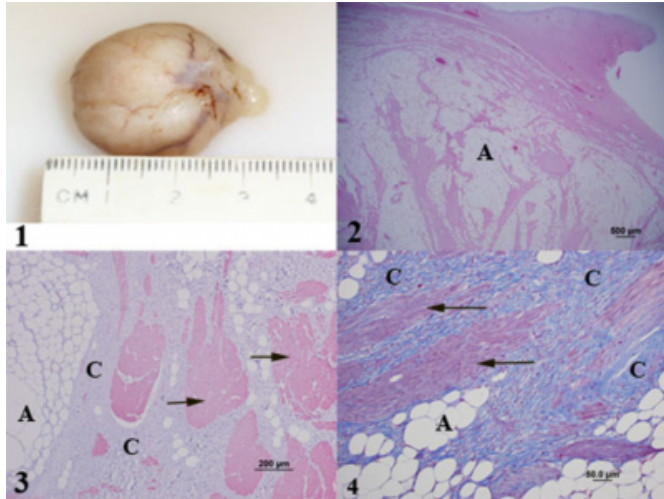
A 1.5 X 2.5 X 3.0 cm vaginal mass (Figure 1) was surgically removed from a 10 year old spayed Great Pyrenees dog, fixed in 10% buffered formalin, processed for routine histopathology, sectioned at 5µm, stained with Hematoxylin-Eosin and examined under light microscopy. Immunohistochemical staining for smooth muscle actin<sup>a</sup>, S-100<sup>a</sup>, vimentin<sup>a</sup> and desmin<sup>a</sup> were made. The immune reactions were detected using commercially available staining kit<sup>a</sup>. Masson's trichrome was employed to visualize collagen fibers.

The section contained a circumscribed poorly encapsulated submucosal mass, (Figure 2), composed of islands and lobules of mature adipocytes interspersed by interlacing bundles of smooth muscle and dense collagen fibers. The smooth muscle cells had indistinct cell borders, ample to abundant eosinophilic cytoplasm, oval to elongate finely stippled nuclei and variably distinct nucleoli. The adipocytes were histologically well differentiated. Lipoblasts, mitotic cells, necrosis and cellular atypia were not seen in the mass. The bundles of smooth muscle stained markedly positive for smooth muscle actin (Figure 3) and mildly to moderately for vimentin and desmin. Masson's trichrome staining demonstrated dense collagen fibers (Figure 4) among bundles of smooth muscle cells and lobules of adipocytes.

Fig.1-4: Vaginal Fibrolipoleiomyoma in a Great Pyrenees dog

**Figure 1**

Fig. 1: Gross view of the mass. : Lobules of adipocytes interspersed by collagen fibers and bundles of smooth muscle cells (H&E-Stain). : Bundles of smooth muscle cells (arrows) positive for antibody against smooth muscle actin. : Abundant blue stained collagen fibers, (C) separated lobules of adipocytes and bundles of smooth muscle (Trichrome stain). A = Adipocytes; Arrows = Smooth muscle cells; C = Collagen fibers



The adipocytes uniformly stained positive for vimentin, variably for desmin and did not stain for S-100. The neoplasm is composed of similar proportion of three mesenchymal tissues (adipose tissue, dense collagen fiber and smooth muscle cells). Based on histological and immunohistochemical findings the neoplasm is diagnosed as fibrolipoleiomyoma, a benign mixed mesenchymal tumor.

Reports on variants of canine reproductive tract leiomyomas with adipose and fibrous tissue components are very rare. Recently, cases of canine vulvar lipoleiomyoma<sup>9</sup> and canine uterine angiolipoleiomyoma<sup>4</sup> were reported. There is paucity of information on canine fibrolipoleiomyomas and lipoleiomyomas to determine the prevalence and associated conditions such as age and breed affected.

There also is no report on human vaginal fibrolipoleiomyoma. In humans, fibrolipoleiomyoma is usually reported from uterus of post-menopausal women between 50 and 75 years of age anywhere in uterus or uterine cervix<sup>5</sup>. Although the cause is unknown, leiomyomas in humans are hormonally dependent, are diagnosed only after menarche and decline after menopause<sup>3</sup>. Leiomyoma in dogs also is described as hormone dependent and does not occur in spayed dogs<sup>8</sup>.

Fibrolipoleiomyoma in the present case occurred in spayed

bitch. Radi<sup>9</sup> also reported a case of vulvar lipoleiomyoma in a bitch spayed two weeks prior to excision of the mass.

Information on hormonal influence on fibrolipoleiomyoma and lipoleiomyomas in dogs is not available. Because of significant increase in size especially when the bitch was in heat, possible hormonal influence was suggested in previously reported vulvar lipoleiomyoma<sup>9</sup>.

Whether lipid and fibrous components developed within pre-existing leiomyomas or whether all the three components developed simultaneously to form fibrolipoleiomyoma can not be determined. Variable suggestions were given for the origin of lipomatous components of human uterine lipoleiomyomas. These include a direct transformation of smooth muscle cells into adipose cells<sup>5</sup>, lipomatous metaplasia of preexisting leiomyoma<sup>6</sup> and as proliferating neoplastic cells<sup>2</sup>. Furthermore, it was suggested that a number of various lipid metabolism disorders or other conditions associated with estrogen deficiency as occurs in peri- or post-menopausal period, possibly promote abnormal intracellular storage of lipids in lipoleiomyoma<sup>1</sup>. As previously suggested in humans<sup>5</sup>, the immunoreactivity of adipocytes for vimentin and desmin might possibly support the hypothesis of their direct transformation from smooth muscle cells into adipose tissue. However, information on histogenesis of these neoplasms in dogs is not available. Studies are recommended to elucidate the histogenesis and associated factors of the neoplasm in dogs. Fibrolipoleiomyoma should be considered in differential diagnosis of canine vaginal neoplasms.

Acknowledgement: The author wish to thank Lisa Whittington for her technical assistance.

Sources and manufactures of antibodies used: a: DakoCytomation, Carpinteria, CA

**References**

1. Alper M, Aylin Aksoy K, Suna M, Cukurs, S., Belenli, OK. (2005). Lipoleiomyoma of the Uterus. *Malta Medical Journal*, 17, 40-41
2. Aung T, Goto M, Nomoto M, Kitajima, S., Douchi, T., Yoshinaga, M., Yonezawa, S. (2004). Uterine lipoleiomyoma: A histopathological review of 17 cases. *Pathology International*, 54, 751-758
3. Baird DD, Dunson DB, Hill MC, Cousins, D., Schectman, JM. (2003) High cumulative incidence of uterine leiomyoma in black and white women: Ultrasound evidence. *American Journal of Obstetrics and Gynecology*, 188,100-107
4. Boisclair J. and Dore´ M. (2001). Uterine Angiolipoleiomyoma in a Dog. *Veterinary Pathology*, 38,726-728
5. Bolat F, Kayaselcuki F, Canpolat T, Erkanli, S., Tuncer, I.

- (2007). Histogenesis of lipomatous component in uterine lipoleiomyomas. Turkish Journal of Pathology, 23, 82-86
6. Cinel L, Dosmez DD, Nabaei SHM, Taner, D. Pata, O. (2002). Two intraligamentary lipomatous tumors with immunohistochemical features. Acta Obstetricia et Gynecologica Scandinavica, 81, 786–787
7. Holtz DO, Holland G, Benjamin GR, Dunton, CH. (2000). Hysteroscopic resection of uterine lipoleiomyoma: Case study and literature review. Journal of lower genital tract disease, 4, 224-226
8. MacLachlan NJ and Kennedy PC. (2002). Tumors of the genital system. In: Tumors in domestic animals. 4th edition. Meuton, D.J. Eds. Iowa State Press, Ames Iowa, pp 561
9. Radi AZ. (2005). Vulvar lipoleiomyoma in a dog. Journal of Veterinary Diagnostic Investigation, 17, 89–90

**Author Information**

**M. Woldemeskel, DVM, PhD, DACVP**

University of Georgia, College of Veterinary Medicine, Department of Pathology, Tifton Vet. Diagnostic and Investigational Laboratory, 43 Brighton Rd, Tifton, GA, 31793, USA