

# Postural Gastro-Esophageal Reflux With Delayed Gastric Emptying

S Wadhwa

## Citation

S Wadhwa. *Postural Gastro-Esophageal Reflux With Delayed Gastric Emptying*. The Internet Journal of Nuclear Medicine. 2001 Volume 1 Number 1.

## Abstract

## INTRODUCTION

Gastro-esophageal motility and reflux disorders present with a wide variety of symptoms however most patients have one or a combination of dyspepsia, fullness, bloating, chest pain or regurgitation. The symptoms most likely relate to a combination of gastric content reflux and abnormal gastro-esophageal motility. The assessment of gastro-esophageal motility now form an integral part of patient management along with endoscopy in those not responsive to acid reducing therapy. There is a growing body of evidence linking abnormal gastric motility and postural effects in the etiology of gastro-esophageal reflux disorder (GERD)(<sub>1</sub>).

Typically the assessment of GERD relies on 24 hour esophageal pH monitoring, endoscopic findings, esophageal monometry and gastro-esophageal scintigraphy. Scintigraphic assessment of reflux is mainly used in the pediatric and infant population. Gastric emptying and esophageal transit scintigraphy is most often used in the assessment of motor dysfunctions such as gastroparesis, achalasia and diffuse esophageal spasm (<sub>2</sub>). Description of a case of endoscopically confirmed posture dependent gastro-esophageal reflux visualized on esophageal transit scintigraphy in a diabetic patient with gastroparesis is described.

## CASE PRESENTATION

38 Year old male with greater than 10 year history of insulin dependent diabetes presented to our department for investigation of epigastric and chest pain. Cardiac investigations had proved negative. The patient had previously had gastric motility studies performed and had established gastroparesis and other features of diabetic autonomic neuropathy. Given the lack of positive cardiac investigations, esophageal dysmotility was considered a

possible cause for the patient's symptoms.

Figure 1 illustrates the time activity curves for the mouth, esophagus and the stomach along with condensed dynamic images of the esophagus after multiple swallows with the patient in the standing position. There is rapid clearance of tracer from the mouth and the esophagus while tracer activity rises quickly in the stomach and remains relatively constant 15 seconds after ingestion. The findings are typical for normal esophageal transit with no evidence of dysmotility.

## Figure 1

Figure 1

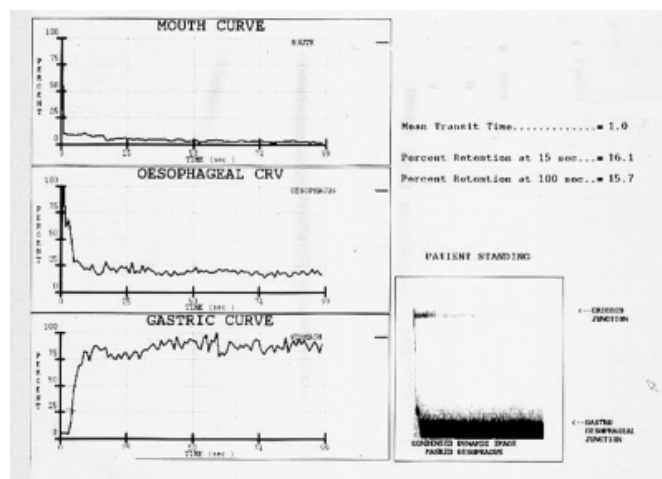
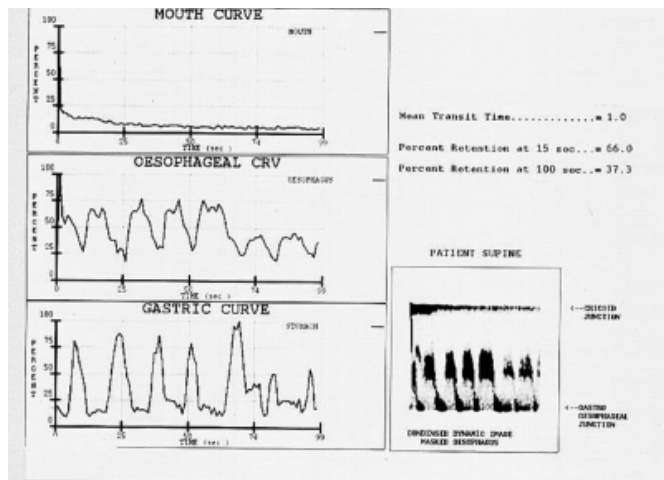


Figure 2 illustrates the time activity and condensed dynamic images in the same patient this time in the supine posture. Again there is rapid clearance from the mouth followed by good clearance from the esophagus. However there is clear reflux of tracer back into the esophagus throughout the study with corresponding reduction in gastric activity. With each swallow esophageal activity drops and gastric activity rises.

**Figure 2**

Figure 2



Subsequent endoscopy performed about 1 week after the esophageal transit study confirmed moderate distal esophagitis with some evidence of columnar epithelial cells suggesting early dysplasia. The case demonstrates the utility of esophageal transit scintigraphy in the investigation of patients with symptoms suggestive of GERD

## DISCUSSION

Endoscopic evaluation with monometry and pH monoterger has been the mainstay of diagnosis for GERD, however scintigraphic evaluation of gastro-esophageal motility is playing an increasing role. Numerous investigators have reported abnormally delayed gastric emptying, in particular of solid meals, in patients with endoscopic evidence of reflux esophagitis (3,4,5). Others have reported the effectiveness of prokinetic in acute and maintenance management of GERD (6). The usefulness of gastro-esophageal motility scintigraphy in diabetics is further exemplified by studies demonstrating that gastric emptying maybe delayed in upto 50% of patients with diabetes while esophageal transit studies have been useful in the detection of asymptomatic autonomic neuropathy (7,8).

Body positioning has been shown to influence post prandial and fasting gastro-esophageal reflux in symptomatic patients and in normal volunteers (9). Gastro-esophageal reflux may occur in the standing position, supine posture or both. In normal volunteers there is no definite pattern however in patients with gastro-esophageal dysmotility there is an increase prevalence of reflux in the supine posture (10,11).

Esophageal transit is used mainly in the assessment of motility disorders. The technique employing multiple swallows, as opposed to a single swallow, is now well established (12). Usual analysis involves a review of both the esophageal time activity curve as well as condensed dynamic images. Our study demonstrates that evaluation of CDI and time activity curves can give an accurate assessment of gastro-esophageal reflux in both postures and represents a non-invasive method in the developing diagnostic algorithm for patients with symptoms of GERD.

## References

1. Keshavarzian A, Iber FL. Gastrointestinal involvement in insulin-requiring diabetes mellitus. *J Clin Gastroenterol* 1987 Dec;9(6):685-92
2. Parkman HP, Miller MA, Fisher RS. Role of nuclear medicine in evaluating patients with suspected gastrointestinal motility disorders. *Semin Nucl Med* 1995 Oct;25(4):289-305
3. Pellegrini CA. Delayed gastric emptying in patients with abnormal gastroesophageal reflux *Ann Surg.* 2001 Aug;234(2):139-46.
4. Esteveao-Costa J, Campos M, Dias JA, Trindade E, Medina AM, Carvalho JL. Delayed gastric emptying and gastroesophageal reflux: a pathophysiologic relationship. *J Pediatr Gastroenterol Nutr* 2001 Apr;32(4):471-4
5. Stacher G, Lenglinger J, Bergmann H, Schneider C, Hoffmann M, Wolfl G, Stacher-Janotta G. Gastric emptying: a contributory factor in gastro-oesophageal reflux activity *Gut* 2000 Nov;47(5):661-6
6. Champion MC. Prokinetic therapy in gastroesophageal reflux disease. *Can J Gastroenterol* 1997 Sep;11 Suppl B:55B-65B
7. Soykan I, Lin Z, Jones S, Chen J, McCallum RW. Gastric myoelectrical activity, gastric emptying and correlations with dyspepsia symptoms in patients with gastroesophageal reflux. *J Investig Med* 1997 Oct;45(8):483-7
8. Benini L, Sembenini C, Castellani G, Caliarì S, Fioretta A, Vantini I. Gastric emptying and dyspeptic symptoms in patients with gastroesophageal reflux. *Am J Gastroenterol* 1996 Jul;91(7):1351-4
9. van Herwaarden MA, Katzka DA, Smout AJ, Samsom M, Gideon M, Castell DO. Effect of different recumbent positions on postprandial gastroesophageal reflux in normal subjects. *Am J Gastroenterol* 2000 Oct;95(10):2731-6
10. Shay SS, Johnson LF. Upright refluxers without esophagitis differentiated from bipositional refluxers with esophagitis by simultaneous manometry and pH monitoring conducted in two postures before and after a meal. *Am J Gastroenterol* 1994 Jul;89(7):992-1002
11. Freidin N, Mittal RK, McCallum RW. Does body posture affect the incidence and mechanism of gastro-oesophageal reflux? *Gut* 1991 Feb;32(2):133-6
12. Tatsch K, Voderholzer WA, Weiss MJ, Schroettle W, Klauser AG, Mueller-Lissner SA, Kirsch CM. Simultaneous assessment of bolus transport and contraction parameters in multiple-swallow investigations. *J Nucl Med* 1992 Jul;33(7):1291-300

**Author Information**

**Surjit S. Wadhwa, FRACP**

St. George Hospital