

Angioma: A Rare Tumor Of Liver

E Yesildag, L Elemen, S Dervisoglu, N Danismend, E Erdogan

Citation

E Yesildag, L Elemen, S Dervisoglu, N Danismend, E Erdogan. *Angioma: A Rare Tumor Of Liver*. The Internet Journal of Pediatrics and Neonatology. 2002 Volume 3 Number 1.

Abstract

INTRODUCTION

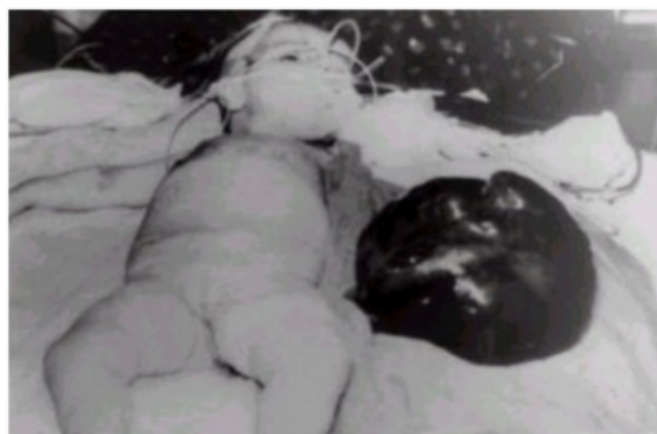Angioma of the liver is rare. It can present as an abdominal mass or acute abdomen (.). In our case, a girl of 4 months of age presented with severe respiratory distress caused by a huge abdominal mass. She was urgently operated on with a presumptive preoperative diagnosis of a duplication cyst. The mass was found to be originating from the left lateral segment of the liver and the histopathologic examination revealed a hepatic angioma.

CASE HISTORY

A previously healthy girl of 4 months of age was referred to the Department of Pediatric Surgery complaining of sudden abdominal distension, respiratory distress, bilious vomiting and failure to pass stool for two days. She was severely dehydrated and physical examination revealed a soft mass occupying most of the abdominal cavity. Plain abdominal X-ray showed a few air-fluid levels in the lower quadrants. After the initial fluid and electrolyte replacement, she was taken urgently to the operating theatre because of severe respiratory distress secondary to the abdominal distention. The preoperative working diagnosis was that of a duplication cyst. No other radiologic investigations could be performed. At laparotomy a huge cystic mass was found. It contained solid components and was originating from the left lateral segment of the liver. It is removed by wedge resection of the thin pedicle (Figure 1). The histopathologic examination was consistent with a hepatic angioma. She was discharged 4 days after the operation and remains well.

Figure 1

Figure 1: A huge mass occupying the whole abdominal cavity is surgically excised.



DISCUSSION

Abdominal masses in childhood include a wide spectrum of pathology. The masses originating from the liver only comprise 5-6% of cases and many of them are malignant.

Figure 2

Table I: An overview of symptoms, diagnostic modalities and differential diagnosis of liver masses in children.

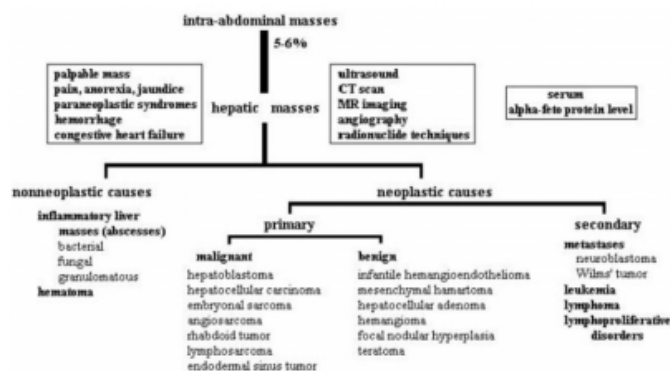


Table I summarizes the symptoms, diagnostic modalities and differential diagnosis of liver masses(2,3). Angioma of the

liver is a rare, benign pathology, which usually presents as an uncomplicated abdominal mass. It may cause coagulopathy and heart failure (^{1,2}). Albano et al. reported hydrops foetalis caused by hepatic hemangioma (₄). Sometimes it can enlarge secondary to hemorrhage and becomes life-threatening. The majority of complications are reported in tumours greater than 5 cm in diameter (^{1,2,4}). In our case the child presents with an acute abdomen, severe abdominal distention and respiratory distress with acidosis. She developed severe respiratory distress due to major hemorrhage of the unknown angioma in her liver. In the evaluation of a child with an abdominal mass, radiologic interventions, such as ultrasonography, computed tomography and angiography, frequently should be performed preoperatively for the diagnosis to be elucidated (^{2,3,5,6}). Though they are not always reliable in differentiating benign from malignant tumors, the typical findings of hepatic hemangioma are clearly documented (^{5,6}). In such an urgent situation as in the presented case, a laparotomy is indicated without performing these investigations.

Different treatment modalities, such as steroids, radiotherapy and interferon alpha-2 therapy have been advocated. However, the approach to an incidentally found, small-diameter lesion should be conservative follow-up, as the rupture of an angioma is extremely rare and it may resolve spontaneously (^{1,4}). On the other hand, the choice of treatment for symptomatic angiomas, either in emergency or elective cases, is hepatic arterial embolization, ligation or surgical resection. This is especially true for giant tumors, owing to their particular tendency for spontaneous growth (^{1,7}). In our case, as the tumor had a thin pedicle, it was removed with a wedge resection but formal hepatic resections may be indicated in tumors with wide pedicles. The recurrences after the operation are generally due to incomplete resections and thus total resection of the tumor is

indicated. The presented case, demonstrates an unknown angioma in the liver, suddenly complicated by hemorrhage and successfully treated by emergency surgical excision. Though not usual, angioma of the liver may present as a surgical emergency. If the general condition of the child permits, it would be better to perform radiologic investigations prior to surgery. If not, surgical exploration and tumor excision with or without liver resection will provide a good prognosis in a majority of these cases.

Acknowledgement: This study was presented in the poster session of Third Congress of Mediterranean Association of Pediatric Surgeons (MAPS), Corfu, Greece 12-15 October 2000

Conflict of interest: None

CORRESPONDENCE TO

Ergun Erdogan MD E mail: dr.ergun@superonline.com
ebruyesildag@hotmail.com

References

1. Iyer CP, Stanley P, Mahour GH. Hepatic hemangiomas in infants and children: a review of 30 cases. *Am Surg* 1996; 62(5): 356-60
2. Donnelly LF, Bisset GS 3rd. Pediatric hepatic imaging. *Radiol Clin North Am* 1998; 36(2): 413-27
3. Stocker JT. Hepatic tumors in children. *Clin Liver Dis* 2001; 5(1): 259-81
4. Albano G, Pugliese A, Stabile M, Sirimarco F, Arsieri R. Hydrops foetalis caused by hepatic hemangioma. *Acta Paediatr* 1998; 87(12): 1307-9
5. Kassarian A, Dubois J, Burrows PE. Angiographic classification of hepatic hemangiomas in infants. *Radiology* 2002; 222(3): 693-8
6. Peterson MS, Baron RL, Rankin SC. Hepatic angiosarcoma: findings on multiphasic contrast-enhanced helical CT do not mimic hepatic hemangioma. *AJR Am J Roentgenol* 2000; 175(1): 165-70
7. Lise M, Feltrin G, Da Pian PP, Miotto D, Pilati PL, Rubaltelli et al. Giant cavernous hemangiomas: diagnosis and surgical strategies. *World J Surg* 1992; 16(3): 516-20

Author Information

E. Yesildag

Departments of Pediatric Surgery and Pathologic Anatomy, Cerrahpasa Medical Faculty, Istanbul University

L. Elemen

Departments of Pediatric Surgery and Pathologic Anatomy, Cerrahpasa Medical Faculty, Istanbul University

S. Dervisoglu

Departments of Pediatric Surgery and Pathologic Anatomy, Cerrahpasa Medical Faculty, Istanbul University

N. Danismend

Departments of Pediatric Surgery and Pathologic Anatomy, Cerrahpasa Medical Faculty, Istanbul University

E. Erdogan

Departments of Pediatric Surgery and Pathologic Anatomy, Cerrahpasa Medical Faculty, Istanbul University