

# Giant Aneurismal Dilatation Of A Brachiocephalic Arterio-Venous Fistula For Hemodialysis Access – A Case Report

A Baskara, T Weber, O Domingo

## Citation

A Baskara, T Weber, O Domingo. *Giant Aneurismal Dilatation Of A Brachiocephalic Arterio-Venous Fistula For Hemodialysis Access – A Case Report*. The Internet Journal of Surgery. 2009 Volume 24 Number 2.

## Abstract

Aneurysmal dilatation of arteriovenous fistula (AVF) created for hemodialysis is one of the frequently known complications we come across in dialysis patients. There are many theories behind the development of aneurysms in these fistulae, which include intrinsic weakness of the vein graft, repeated punctures at clustered sites of the fistula and proximal stenosis which accelerates the process of aneurysm formation due to increase in the venous pressure in the AVF. We report a case of 61-year-old gentleman who presented with giant aneurysmal dilatation of his AVF seven years after its creation. The patient was taken to the operating room electively for excision of the fistula. Not only for cosmetic results should we operate on these patients, but we should also realize that these aneurysms of AVF can rupture anytime causing a life-threatening emergency.

## INTRODUCTION

Arteriovenous fistulae (AVF) are created for hemodialysis for patients who have end-stage renal disease. Though creation of AVF is a common procedure done for patients who require long-term hemodialysis, it has its own complications. An important complication is that of aneurysmal dilatation of the venous end which can rupture and cause hemorrhage which could be fatal.

There are many causes for aneurysm formation which include intrinsic weakness in the venous graft used for the fistula, repeated punctures at clustered sites which weaken the wall and proximal stenosis which accelerates the process of aneurysm formation by raising the pressure in the AVF. The incidence of aneurysm formation in AVF for hemodialysis access is about 5 to 6% (1).

We report a case of a 61-year-old gentleman who presented with a giant aneurysm of a left brachiocephalic arteriovenous fistula which grew over a period of 7 years after its creation.

## CASE REPORT

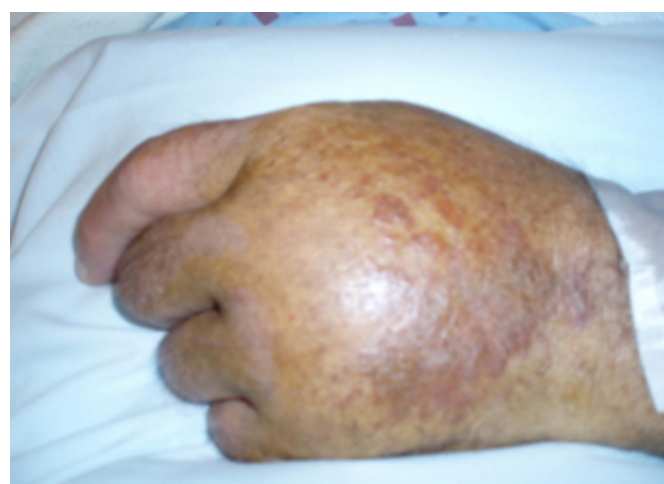A 61-year-old Caucasian gentleman with end-stage renal disease underwent creation of a left antecubital radiocephalic AV fistula (side to end) for hemodialysis access 7 years ago. The patient had a successful renal transplant 1 year after the AVF surgery and then the patient was off dialysis.

The patient eventually noticed swelling in the forearm and

lower third of the arm. During the office visit 5 years ago, it was found that the patient was developing aneurysmal dilatation of the fistula. He also developed swelling of left hand due to venous hypertension (Fig. 1). The patient was advised to undergo surgery but due to personal reasons he postponed surgery for the past 5 years though he was fully aware of the risk of aneurysmal rupture.

## Figure 1

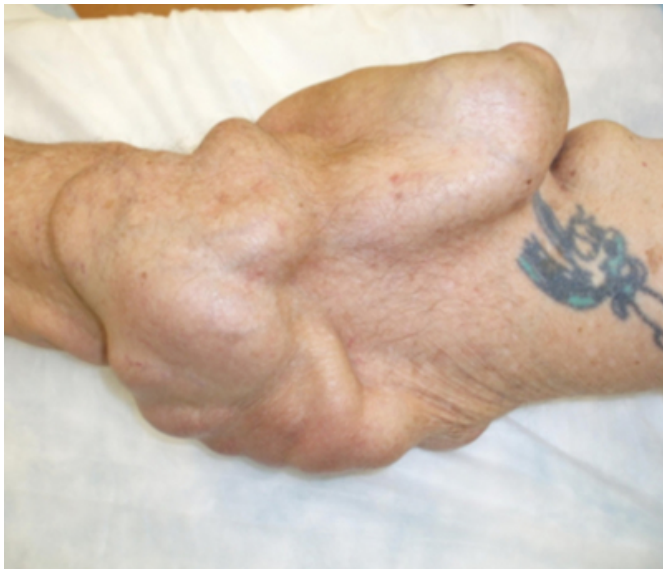Fig. 1: Chronic edema of the left hand due to venous hypertension



The aneurysm grew to enormous size to cover the whole of his forearm (Fig. 2). The patient finally agreed to excision of the aneurysm and stated that he wanted the surgery for cosmetic reasons.

**Figure 2**

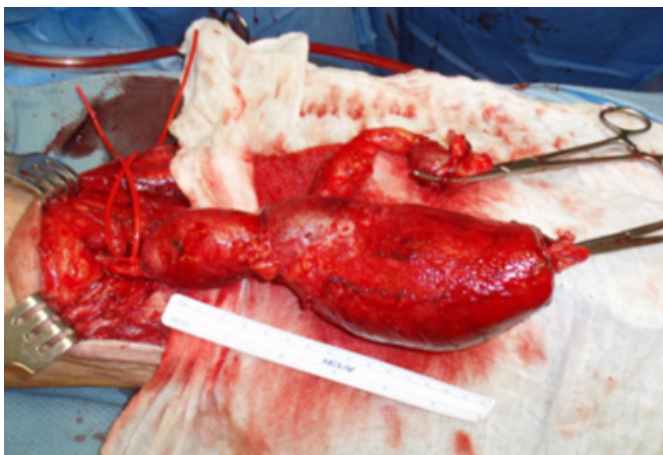
Fig. 2: Giant aneurysmal dilatation of AVF



The patient underwent excision of the giant AVF aneurysm on July 21, 2008. The incision was made at the arterial end and brachial artery control was achieved using a vessel loop. The incision was extended as necessary during the process of excision of the aneurysmal fistula. The aneurysm measured 9cm in its maximum diameter. A stenosis was found at the venous end which is marked by a vessel loop in figure 3.

**Figure 3**

Fig. 3: Intra-operative finding of giant aneurysmal dilatation of AVF with stenosis



After nearly excising two thirds of the AVF aneurysm, further complete excision of the aneurysm was deferred as there was a large skin flap and to avoid flap necrosis. Excessive skin was excised and closed with tension free 3-0 nylon sutures.

The patient was discharged home on the same day and was followed up at the outpatient office. The incision healed well and no flap necrosis was encountered (Fig. 6). The patient is scheduled for a second stage removal of the remaining aneurysmal vein in the following month.

## DISCUSSION

Autogenous arteriovenous fistulae (AVF) are created for hemodialysis in patients with end-stage renal disease. Thrombosis accounts for 90% of the complications of autogenous arteriovenous fistulae (2). True aneurysms are most likely to occur in native AVF and their overall incidence is poorly defined. It is found to be approximately 5% to 6%.

After renal transplantation, the possibility of spontaneous AVF closure caused by thrombosis is not a rare event. The definite indications for AVF closure in well functioning renal transplanted patients are heart failure, high flow fistula, vascular access complications like aneurysm, ischemia, infections and important aesthetic reasons (3). The indications for operating venous aneurysms are progressively increasing size, thrombosis or an overlying skin lesion (4).

Management of AVF aneurysms depends upon their size and extent. Focal aneurysms can be managed either with interposition, replacement with vein or a prosthesis, or, if the wall is fairly thick, resection and imbrication to a size that matches the remainder of the access.

The modalities to treat an aneurysm of AVF which are less invasive include manual ligation and compressing under ultrasonographic guidance, endovascular graft implantation, embolization, and thrombin injection under ultrasonographic guidance (5).

In our patient, the aneurysm was enlarged to an extent that may cause rupture. The patient also had a good-functioning transplanted kidney and hence a decision for excision without a salvage technique was made. We were able to excise the aneurysm only partially for fear of skin flap necrosis. Our patient was satisfied with the outcome of the surgery. His left hand swelling also improved after the procedure. The patient wishes to have a second stage complete resection of the AVF aneurysm which we plan to do in the near future.

## References

1. Winsett OE, Wolma FJ: Complications of vascular access

## ***Giant Aneurismal Dilatation Of A Brachiocephalic Arterio-Venous Fistula For Hemodialysis Access – A Case Report***

---

for hemodialysis. South Med J; 1985; 78: 513-7.

2. Burkhart HM, Cikrit DF: Arteriovenous fistulae for hemodialysis. Semin Vasc Surg; 1997; 10: 162-5.

3. Manca O, Pisano FL, Carta P, Manca EM, Piredda GB, Pili G, Logias F, Lojacono F, Barracca A: The management of hemodialysis arteriovenous fistulas in well functioning renal transplanted patients: Many doubts, few certainties. Journal of Vascular Access; 2005; 6: 182-86.

4. Mackrell PJ, Cull DL, Carsten III CG: Hemodialysis

access: placement and management of complications. In: Hallett Jr JW, Mills JL, Earnshaw JJ, Reekers JA.

Comprehensive vascular and endovascular surgery. 1st ed. New York: Mosby Publishing Co.; 2004; pp. 361-90.

5. Karabay O, Yetkin U, Silistreli E, Uskent H, Onol H, Acikel U: Surgical management of giant aneurysms complicating arteriovenous fistulae. J Int Med Res; 2004;32:214-7.

**Author Information**

**Arunkumar Baskara, MRCS MD**

Mercy Fitzgerald Hospital

**Tory R. Weber, BA MA DO**

Philadelphia College of Osteopathic Medicine

**Orville Domingo, MD**

Vascular Surgeon, Mercy Fitzgerald Hospital