

Detection Of High - Risk Human Papillomavirus Type 16/18 In Cutaneous Warts In Immunocompetent Patients, Using Polymerase Chain Reaction

R Payal, S Gupta, R Aggarwal, S Handa, B Radotra, S Arora

Citation

R Payal, S Gupta, R Aggarwal, S Handa, B Radotra, S Arora. *Detection Of High - Risk Human Papillomavirus Type 16/18 In Cutaneous Warts In Immunocompetent Patients, Using Polymerase Chain Reaction*. The Internet Journal of Dermatology. 2005 Volume 4 Number 1.

Abstract

Cutaneous warts are caused by human papillomavirus (HPV). Prevalence studies of the types of HPV present in cutaneous warts have been carried out more frequently in immunosuppressed patients. The present study was designed to study the association of high-risk HPV in cutaneous warts of immunocompetent patients. A total of 45 cases of cutaneous warts from various sites in immunocompetent subjects were analysed for HPV. Samples included both archival material i.e. paraffin embedded and fresh tissue. Highly sensitive and comprehensive polymerase chain reaction (PCR) methodology for detection of HPV of high oncogenic potential, HPV 16/18 was employed. HPV 16 was detected in 3 (6.6%) patients. None of the lesion demonstrated HPV 18. None of the cutaneous warts demonstrated histopathological features associated with dysplasia or neoplasia. The identification of HPV 16 in cutaneous warts which are benign proliferation of the skin further expands the spectrum of HPV linked lesions. It remains of critical interest to determine whether these types are specifically associated with the development of malignant lesions analogous to those seen in anogenital cancer.

INTRODUCTION

Human papillomavirus (HPV) appears to be the most ubiquitous of the human viruses. Over 100 HPV types have been identified. Majority of HPV infect the skin of normal as well as immunocompromised individuals. In normal people, most of these HPV appear to establish a latent infection of the skin most likely as normal flora residing in hair follicles. A minority of HPV cause cutaneous warts and mucosal condylomata [1]. Warts or verrucae are benign proliferations of the skin, cutaneous warts (verrucae vulgaris), flat warts (verruca plana), plantar warts, mosaic warts and butcher's warts. HPV may have a role in promoting proliferating lesions of the skin, although their site of active infection and mode of transmission to susceptible individuals remains unknown.

HPV is an epitheliotrophic virus and is inoculated into the viable epidermis through defects in the epithelium. Only a few HPV types of low and intermediate oncogenic potential have been recognised in cutaneous warts. The more frequent HPV types found in lesions of cutaneous common warts in general population are HPV types 2, 57, 27, 4 and 1 [2,3]. There is paucity of data on the association of mucosotropic

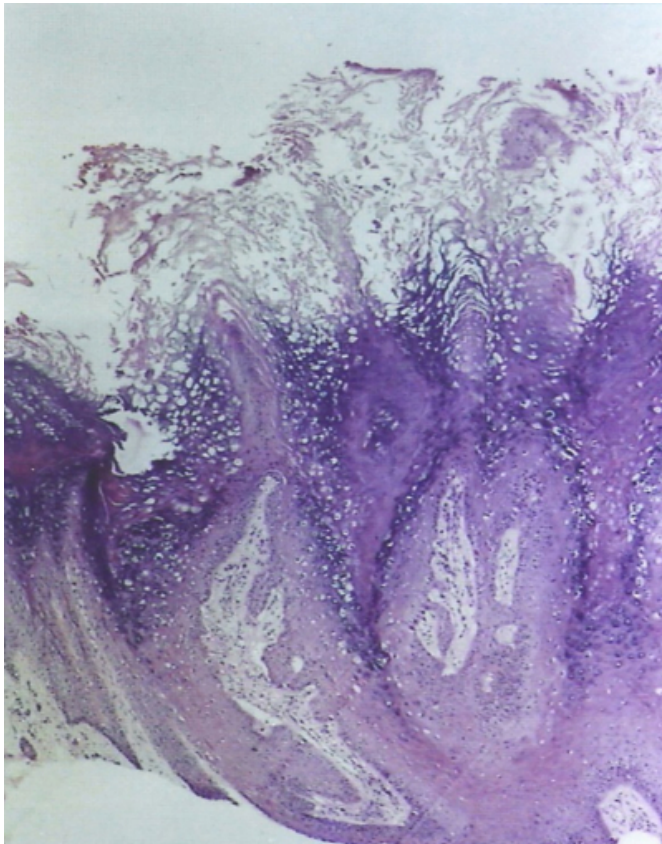
HPV of high oncogenic potential with cutaneous wart. The present study aims to analyse the association of HPV 16/18 in the cutaneous warts in immunocompetent patients.

MATERIAL AND METHODS

Forty five cases of clinically diagnosed cutaneous warts and subsequently histologically proven verrucous lesion were recruited from January to December 2004. Lesions were considered as common warts if the lesions presented with compact hyperkeratosis, acanthosis, papillomatosis, hypergranulosis, elongated and flattened dermal papillae bend inwards towards the centre of the lesion and enlargement of the capillaries (figure 1).

Figure 1

Figure 1: Photomicrograph of Verruca vulgaris shows hyperkeratosis, parakeratosis, acanthosis and papillomatosis. (H & E 55X)



Fresh tissue was available in 10 cases. In the rest 35 cases, DNA was extracted from the paraffin embedded tissue. Cutaneous warts were excised under aseptic conditions and local anaesthesia. A part of the tissue was stored at 4°C in phosphate buffered saline (pH 7.4), rest was preserved in 10% buffered formalin for histopathological examination. Ten cases of non viral dermatological conditions were included as negative controls.

DNA EXTRACTION

The tissue specimen was teased and suspended in 500µl of lysis buffer containing 1% SDS and 0.01% proteinase K in Tris-EDTA (TE) buffer (pH 8.0) and incubated at 55 °C overnight. Extraction was done by phenol-chloroform-isomyl alcohol mixture. DNA was precipitated with ice chilled isopropanol. DNA was pelleted out next day and resuspended in TE buffer. From the paraffin embedded tissue blocks, 5µm sections were cut and deparaffinised with organic solvent and digested with proteinase K solution [4]. All the other steps were same as for the fresh tissue. DNA was quantitated spectrophotometrically. PCR for β -actin

gene was done for each sample as an internal control.

POLYMERASE CHAIN REACTION (PCR) FOR HPV

All samples were subjected to PCR using primers specific for consensus sequence spanning the E6 open reading frame of high risk HPV type 16, 18, 31, 33 [5]. The sequence of forward primer was 5'-TGTCAAAACCGTTGTGTCC-3' and that of reverse primer 5'-GAGCTGTCGCTTAATTGCTC-3'. Positive samples were subjected to PCR using type specific primers for HPV types 16 and 18 [6]. Forward primer for HPV 16 being 5'-ATTAGTGAGTATAGACATTA-3' and that of reverse primer was 5'-GGCTTTTGACAGTTAATACA-3'. The forward and reverse sequence of HPV type 18 specific primers was 5'-ACTATGGCGCGCTTTGAGGA-3' and 5'-GGTTTCTGGCACCGCAGGCA-3', respectively. The amplified gene fragments were of 109 bp and 334 bp for HPV 16 and 18, respectively and were visualized on 2 % agarose gels

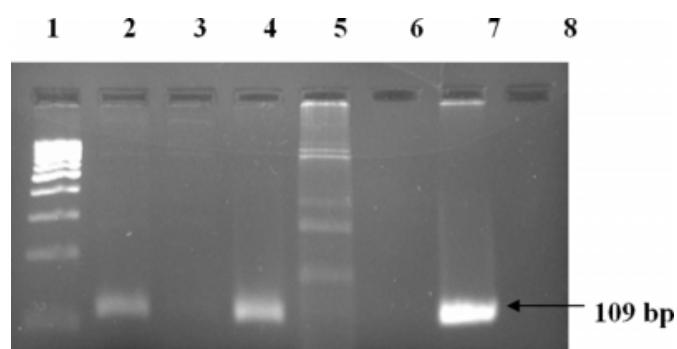
RESULTS

Forty five patients were recruited in the study. Male: female ratio was 4:1. Majority of patients (57%) were in the age group of 21-40 years. Mean age was 35 years (range 14-76). Most of the lesions were present on the exposed parts of the body i.e. hand 17(37.8%), foot 9 (20%), arm 6 (13.3%), scalp 6 (13.3%) and face 5(11%). Lesion was in one case was present on chest and abdominal wall respectively. None of the cutaneous warts showed histopathological features associated with dysplasia or neoplasia. The duration of cutaneous warts among patients varied from 2 months to 2 years but was less than 1 year in 31 (68%) patients.

High risk oncogenic HPV type 16 was detected in 3 (6.6%) patients (figure 2). The lesions were positive with consensus primer for HPV types 16, 18, 31 and 33. These were confirmed using type specific primers for type 16 and 18. None of the lesion demonstrated HPV type 18. All the samples negative for high risk HPV were positive for β -actin primers excluding failure of HPV amplification due to problems such as lack of DNA, inappropriate storage or technical problems. All 3 patients were aged less than 35 years. The lesions were present on the exposed parts of the body i.e. arm, hand and neck. None of the control was positive for HPV.

Figure 2

Figure 2: Agarose gel electrophoresis of PCR products of HPV type 16 (109 bp)



DISCUSSION

Warts are widespread in the worldwide population, although, the exact frequency is unknown. Human papillomavirus of low risk subtypes 2, 27, 57, 4 and 1 are known to be associated with cutaneous warts. Epidemiology as well as morphology of common warts is closely linked to the virus type. Prevalence studies on types of HPV present in cutaneous warts have been carried out more frequently in immunosuppressed patients. Multiple skin disorders like warts, hyperkeratosis, keratoacanthomas and skin malignancies are more commonly seen in immunosuppressed patients, commonly seen in transplant patients. Studies regarding detection of HPV in skin warts using various techniques including PCR have revealed quite heterogeneous results. Many primer pairs either degenerate or specific have been used by several authors with variable results regarding the percentage of HPV detection in cutaneous warts of immunocompetent and immunosuppressed patients. It is possible that diversity of results in published data may be due to variations among the prevalent HPV types in cutaneous warts as well as differences in the population studied.

Rubben et al demonstrated HPV types 2, 27 and 57 induced common warts at non-genital sites. Harvard et al [7] detected mucosotropic HPV DNA by using combination of primers by PCR and found a prevalence of 27.4% in immunosuppressed patients. Soler C [8] et al suggested that HPV lose their specificity for mucosa and cutaneous sites in immunosuppressed patients. Chen et al [9] detected HPV type 16 in 2% and type 18 in 8% respectively by using Southern Blot hybridisation technique. In the index study HPV 16 was detected in 6.6% cases. Our data may be underestimating the true prevalence, since DNA was obtained in majority of the cases from paraffin embedded

tissue, which yields suboptimal results compared with fresh frozen tissue [10]. The reason why we chose to use two primers set ie consensus as well as type specific was to increase the specificity of the test.

Cutaneous HPV types in general population are predominantly associated with benign viral warts but their role in non-melanoma skin cancer has recently been postulated. The association of viral warts and skin cancer has been suspected in renal transplant patients for a long time [11]. Renal transplant patients have a well documented 50 to 100 fold increased risk of cutaneous squamous cell carcinoma [12]. The cumulative incidence of skin cancer is 27-44% after 10-25 years of immunosuppression [13]. With improved PCR technique association of HPV in non melanoma skin cancer has been documented lately, although to a lesser extent. No particular HPV type has yet emerged as predominant.

Although high risk HPV type 16 has been demonstrated in cutaneous warts as in the present study, but all lesions may not progress to develop neoplastic lesion. HPV 16 may remain latent in these lesions for quite a long time. It has also been observed that HPV by themselves may not lead to development of skin cancer in the long run and require other additional factor like sunlight (ultraviolet light) to cause neoplastic diseases. Patients harbouring high risk HPV may progress to invasive squamous cell carcinoma after a long latency period of 20 to 50 years.

It requires large cross sectional studies and long term follow up, to confirm the association of HPV and non melanoma skin cancer in immunocompetent patients. This will establish whether HPV plays an active or purely passenger role in the evolution of non-melanoma skin cancer. The diagnosis of HPV infection is an evolving field. DNA testing has greatly expanded the options available for the detection and study of HPV disease. So it remains of critical interest to determine whether these types are specifically associated with the development of malignant lesions analogous to those seen in anogenital cancers.

CORRESPONDENCE TO

Dr S K Arora Additional Professor Department of Immunopathology, Postgraduate Institute of Medical Education and Research, Chandigarh-160 012, India. E-mail: skarora_in@yahoo.com Tel: +91-172-2755192 Fax: +91-172-2744401,2745078

References

1. Jenson AB, Geyer S, Sundberg JP, Ghim S. Human Papillomavirus and skin cancer. *J Invest Dermatol Symp Proc* 2001; 6:203-6.
2. Rubben A, Krones R, Schwetschenau B, Grussendorf-Conen E-1. Common warts from immunocompetent patients show the same distribution of human papillomavirus types as common warts from immunocompromised patients. *Br J Dermatol* 1993; 128:264-70.
3. Chan SY, Chen SH, Egawa K et al. Phylogenetic analysis of the human papillomavirus type 2 (HPV-2), HPV-27 and HPV-57 group, which is associated with common warts. *Virology* 1997; 239:296-302.
4. Shibata DK, Atheim N, Martin W. Detection of human papillomavirus in paraffin embedded tissue using the polymerase chain reaction. *J Exp Med* 1988; 167:225-230.
5. Oh YL, Shin KJ, Han J, Kim DS. Significance of high-risk human papillomavirus detection by polymerase chain reaction in primary cervical cancer screening. *Cytopathol* 2001; 12:75-83.
6. Miller CS, Zeuss MS, White DK. Detection of HPV DNA in oral carcinoma using polymerase chain reaction together with in situ hybridization. *Oral Surg Oral Med Oral Pathol* 1994; 77:480-6.
7. Harvard CA, Spink PJ, Suretheran T et al. Degenerate and nested PCR: a highly sensitive and specific method for detection of human papillomavirus infection in cutaneous warts. *J Clin Microbiol* 1999; 37:3545-3555.
8. Soler C, Allibert P, Chardounet V et al. Detection of human papillomavirus types 6, 11, 16 and 18 in mucosal and cutaneous lesions by the multiplex polymerase chain reaction. *J Virol Methods* 1995; 350:143-158.
9. Chen SL, Tsao YP, Lee JW et al. Characterisation and analysis of human papilloma viruses of skin wart. *Arch Dermatol Res* 1993; 285: 460-465.
10. Studniberg HM, Weller P. PUVA, UVB, psoriasis and non-melanoma skin cancer. *J Am Acad Dermatol* 1993; 29:1013-22.
11. Walder BK, Robertson MR, Jeremy D. Skin cancer and immunosuppression. *Lancet* 1971; ii: 1282-3.
12. Birkeland SA, Storm HH, Lamm LV et al. Cancer risk after renal transplantation in the Nordic countries, 1964-1986. *Int J Cancer* 1995; 60:183-9.
13. Hardie IR, Strong RW, Hartely LC et al. Skin cancer in Caucasian renal allograft recipients living in a subtropical climate. *Surgery* 1989; 87:177-83.

Author Information

R. Payal, M.D.

Senior Resident, Department of Pathology, Postgraduate Institute of Medical Education and Research

S. Gupta, M.Sc.

Senior Research Fellow, Department of Immunopathology, Postgraduate Institute of Medical Education and Research

R. Aggarwal, M.D., D.N.B.

Assistant Professor, Department of Immunopathology, Postgraduate Institute of Medical Education and Research

S. Handa, M.D.

Assistant Professor, Department of Dermatology, Postgraduate Institute of Medical Education and Research

B. D. Radotra, M.D., Ph.D.

Additional professor, Department of Histopathology, Postgraduate Institute of Medical Education and Research

S. K. Arora, Ph.D, MNAMS

Associate Professor, Department of Immunopathology, Postgraduate Institute of Medical Education and Research