

# Retrobulbar Haemorrhage After Zygoma And Orbital Floor Fracture Repair: Rare Complication And Management.

S Rogers, P Sillifant

## Citation

S Rogers, P Sillifant. *Retrobulbar Haemorrhage After Zygoma And Orbital Floor Fracture Repair: Rare Complication And Management.* The Internet Journal of Head and Neck Surgery. 2009 Volume 4 Number 2.

## Abstract

Retrobulbar Haemorrhage as a complication of zygomatico-orbital floor repair occurs in 0.1%<sup>6</sup> of cases. It can lead to irreversible loss of vision if not accurately identified and rapidly managed. We describe the case of such a patient who underwent urgent lateral canthotomy to decompress the orbit and his subsequent excellent recovery from a potentially sight threatening situation. The clinical diagnosis and management options available are discussed and a short literature review is included.

## INTRODUCTION

Traumatic haemorrhage in to the orbital space may result in sudden loss of sight. If this is not identified and corrected early visual loss may be permanent. So-called retrobulbar haemorrhage usually occurs immediately but may be delayed by a few days post injury<sup>10</sup>. More commonly it occurs as a complication of orbital floor repair or zygomatic fracture reduction and its incidence has been reported to be less than 1%<sup>3,7</sup>. Recently the incidence of retrobulbar haemorrhage following zygomatico-orbital complex fracture reduction by maxillofacial surgeons in Australia has been reported to be as low as 0.1%<sup>6</sup>.

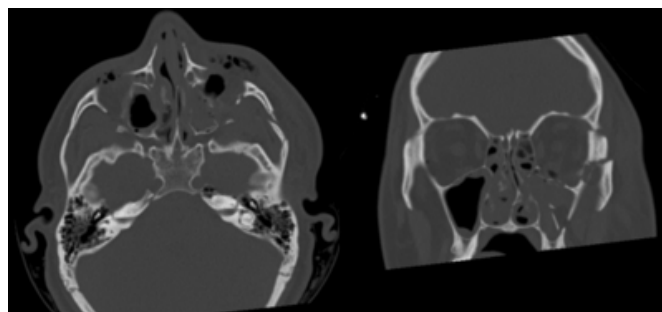
When Haemorrhage does occur, visual acuity is likely to recover provided diagnosis and treatment occurs within 2 hours<sup>3</sup>.

## CASE REPORT

A 26 year old male was assaulted and received a blunt trauma to the left eye. He was reviewed in ED where a plane radiograph of the face suggested the presence of a left zygomatic fracture with arch and rim fragments. At the time he was grossly oedematous and complaining of numbness below the eye. CT views confirmed a depressed comminuted fracture of the left zygoma. A comminuted fracture was also noted in the left lateral orbital wall and anterior and lateral wall of the left maxilla. And there was a depressed fracture of the left orbital floor. No damage to the globes or haemorrhage was noted at the time and it was felt necessary to review again once the swelling had resolved. (Fig.1.)

## Figure 1

Figure .1. Initial injury

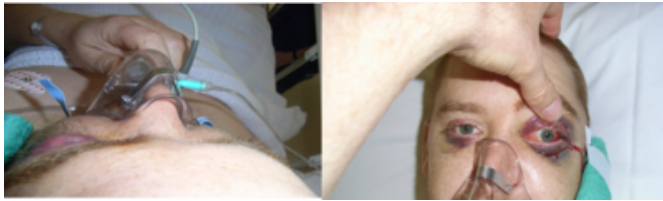

Four days later the patient underwent an open reduction and fixation of the fracture using a trans-conjunctival approach to gain access to the orbital floor, infraorbital rim and the Malar eminence. The maxillary buttress was reached by making a buccal sulcus incision.

Immediately after surgery, the patient described reduced visual acuity, pain and marked ptosis of the left eye. On examination there was increased resistance to retropulsion but formal intraocular pressure testing was not performed. There was marked ophthalmoplegia, pupil dilatation and relative afferent papillary defect (RAPD) (Fig.2.).

**Figure 2**

Figure .2. Proptosis (Left); Ophthalmoplegia and chemosis (Right)

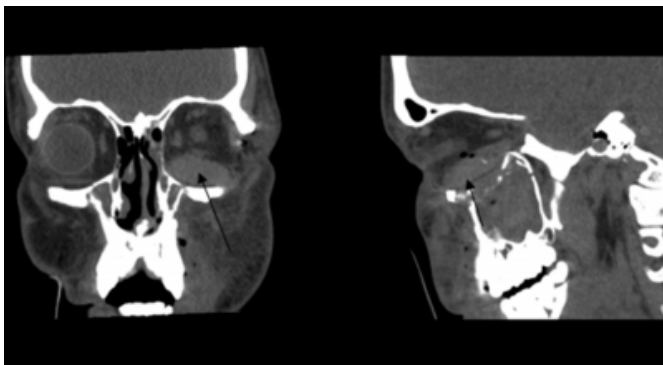


A lateral canthotomy was performed by releasing the sutures and incising inferior limb of lateral canthal tendon. After release the ophthalmoplegia resolved and visual acuity improved within minutes.

A follow-up CT scan was performed and ophthalmology review which showed a left inferior extraconal haematoma which was not felt to be pressing on the optic nerve (Fig.3.). Visual acuity had returned to 6/12 in the right eye. The canthotomy was left open for one week without formal evacuation of haematoma.

**Figure 3**

Figure.3 Inferior extraconal haematoma (Left); Medpore in situ (Right)



The patient went on to make a full recovery. Lateral Canthal Sling repair was considered by ophthalmology but eventually deemed to be unnecessary. At the six week follow-up the patient's vision had returned to 6/6 and he was happy with the result suffering no further complications.

**DISCUSSION**

When observing a patient postoperatively it is important to look out for severe orbital pain, reduced visual acuity, proptosis and ophthalmoplegia. These are the main clinical signs. Other features include subconjunctival oedema/ecchymosis, eyelid swelling, dilated pupils and loss of direct pupillary light reflex.

In order to identify these features early the following scheme has been proposed<sup>2</sup>. For the first two hours patients should be repeatedly monitored at 15minute intervals and at 30minute intervals for the next two hours. The nursing staff should then monitor hourly until given further notice. If noticed, intervention should be immediately implemented to prevent permanent loss of vision<sup>1</sup>.

The orbit consists of superior, lateral, inferior and medial bony walls and anteriorly with the globe and superior and inferior orbital septa. When bleeding occurs within this bony cavity, there is little room to accommodate the increase in volume. The globe and septa are displaced forward (proptosis). Only limited by the eyelids and the length of the optic nerve<sup>4,5</sup>.

Hemorrhage generally originates from the infraorbital artery and one of its branches. Bleeding causes a substantial rise in intraocular pressure unless there is decompression through orbital wall fractures. This rise in pressure compresses structures contained within the orbit including the central retinal vessels and can lead to oedema around the optic nerve head. The exact mechanism of the resultant neuropathy is not fully understood. The optic nerve may be compressed directly, or the vascular supply to the nerve may be compromised. Central retinal artery (CRA) ischemia is another proposed mechanism. Animal models suggest that visual loss secondary to CRA ischemia may be reversible for up to 100 min<sup>8</sup>.

After diagnosis of retrobulbar hemorrhage prompt evacuation is needed as already stated. There are medical methods of treatment for approaching the problem such as intravenous Acetazolamide 500mg or intravenous hydrocortisone 100mg or alternatively rapid infusion of 20% Mannitol can be used<sup>7</sup>. However, if visual acuity does not improve within 10 to 20minutes surgical intervention is deemed mandatory.

The first well-documented surgical approach involved a lateral canthotomy and inferior cantholysis<sup>9</sup>. It should be noted that emergent canthotomy is only indicated when haemorrhage in to the enclosed orbit is present. Alternative techniques have been proposed including access through prior surgical incisions (as in this case), lateral brow or infraorbital and trans-antral inferior approaches.

Extensive cantholysis can lead to problems such as ectropion at a later date due to damage of the suspensory ligaments.

Improper direction of the scissors may lead to ptosis by damaging the levator aponeurosis. Other structures such as the lacrimal gland and lacrimal artery should also be avoided. After the initial stages of surgery the patient needs to be watched closely for signs of abscess formation and infection.

## **CONCLUSION**

Bleeding in to the orbital space may occur due to a variety of reasons. If not identified early (within 2 hours) and acted upon quickly, visual loss may be permanent. Lateral canthotomy has been shown here and previously to be the surgical option of choice to decompress the orbit and, while it has associated risks and complications, if done properly can avoid permanent loss of vision.

## **References**

1. Bailey WK: Diagnosis and treatment of retrobulbar

- hemorrhage. *J Oral Maxillofac Surg* 51:780, 1993
2. Hayter JP, Sugar AW: An orbital observation chart. *Br J oral Maxillofac surg* 29:77, 1991
3. Hislop WS, Dutton GN: Retrobulbar hemorrhage: Can blindness be prevented? *Injury* 25:663, 1994
4. Katz B, Herschler J, Brick DC: Orbital haemorrhage and prolonged blindness: a treatable posterior optic neuropathy. *Br J Ophthalmol* 1983;67:549–53.
5. Linberg JV. Orbital compartment syndromes following trauma. *Adv Ophthal Plastic and Reconstruct Surgery* 1987;6:51–62.
6. Lynham, Mansour and Chapman ANZOMS 2001
7. Ord RA: Post-operative retrobulbar hemorrhage and blindness complicating trauma surgery. *Br J Oral surg* 19:202, 1981
8. Soll DB. Management of complications in ophthalmic plastic surgery. Birmingham, AL: Aesculapius Publishing Co.; 1976:261
9. Vassallo S, Hartstein M, Howard D, Stetz J. Traumatic retrobulbar hemorrhage: emergent decompression by lateral canthotomy and cantholysis. *J Emerg Med.* 2002 Apr;22(3):251-6.
10. Wood CM: The medical management of retrobulbar hemorrhage complicating facial fractures: a case report. *Br J Oral Maxillofac surg* 27: 291,1989

**Author Information**

**S.J Rogers**

Wellington Street Campus, Royal Perth Hospital

**P Sillifant**

Department Of Maxillo-Facial Surgery, Wellington Street Campus, Royal Perth Hospital