

# Iliac Crest Bone Graft Harvesting: Prospective Study Of Various Techniques And Donor Site Morbidity

S Kukreja, H Raza, A Agrawal

## Citation

S Kukreja, H Raza, A Agrawal. *Iliac Crest Bone Graft Harvesting: Prospective Study Of Various Techniques And Donor Site Morbidity*. The Internet Journal of Orthopedic Surgery. 2009 Volume 18 Number 1.

## Abstract

**Background** - Harvesting autograft bone from the ilium is not without complications. When cases are reported in follow-ups, investigators usually concentrate upon treatment outcome of the principle problems and not on the donor site morbidity from harvesting a bone graft. The purpose of our study is to assess the complications related to bone grafting site of iliac crest, simultaneously evaluation and assessment of various techniques used for harvesting the bone graft from the iliac crest. **Material and methods**

- 56 patients were included in our study, which fulfilled the criteria of at least 6 months follow up. Bone graft was harvested from anterior or posterior iliac crest by wolfe-kawamoto's, outer cortex, inner cortex and tricortical graft harvesting and trephine techniques. **Results** – Graft harvested from anterior crest in 49 cases (88%), posterior crest in 6 cases (11%) and bilateral anterior crest in 1 (1.8%). Graft harvesting techniques- wolfe-kaamoto's used in 15(27%), outer cortex in 30 patients (55%), inner cortex in 1(1.8%), and tricortical in 8(14%) and trephine method in 1(1.8%) patient. Average amount of graft harvested from posterior cortex was more compared to anterior crest (13.3/9.6 gm). Donor site complications- infection rate 7.2% (superficial- 3 patients, deep- 1 patient), hematoma 1.8% (n-1), cutaneous nerve injury 14.3% (temporary loss of sensation 3, residual loss in 5 patients), donor site pain 10.6% (temporary- 5, residual- 1) and direct incomplete hernia in 1 patient (1.8%). Total donor site morbidity was (35.6%)[minor complications in 21.4%(n-12) and major complications in 14.2%(n-8)]. **Conclusion**- Harvesting bone graft from iliac crest is not without complications. Injury to the cutaneous nerve around the crest constitutes the major component of morbidity after iliac crest bone graft harvesting.

## INTRODUCTION

The principles, indications and techniques of bone grafting were well established before “ the metallurgic age” of orthopedic surgery. Church literature presented the first mention of bone transplantation in 1682. The first successful autograft was reported by Dr. P. Von Walther in 1820 and Macewen, 58 years later using an aseptic technique performed the first successful autograft bone transplant. Anterior and posterior iliac crest are good sources of large cancellous and cortico-cancellous graft. If the patient is prone, posterior third of ilium is used, if supine, the anterior third is available. There are various methods of graft harvesting from iliac crest- graft from outer cortex, graft from inner cortex, wolfe-kawamoto's method, tricortical graft, “trap-door” technique, “table-splitting” method and trephine technique<sup>1,5</sup>. Many studies reporting on the morbidity of the iliac crest bone graft have reported overall complications ranging from 15% to 49%<sup>3,4</sup>. Complications that have been enlisted are infection, hernia, fracture, pelvic

instability, nerve injury, ureteral injury, chronic pain, hematoma, gait abnormality, superior gluteal artery injury and enterocutaneous fistula<sup>2,4,5,6,7,8,9,10,11</sup>. Complications at donor site can be divided into minor and major, definition, which has been provided, by Younger and Chapman<sup>12</sup>. Minor complications were defined as self-limited events that did not require an additional surgical procedure and responded to non-operative management. Major complications were those that led prolonged hospitalization and required additional surgery. The purpose of our study is to assess the complications related to bone grafting site of iliac crest, simultaneously evaluation and assessment of various techniques used for harvesting the bone graft from the iliac crest.

## MATERIAL AND METHDS

56 patients who had undergone iliac crest bone graft harvesting between September2003-September2004 were studied retrospectively. There were 50 females and 6 males,

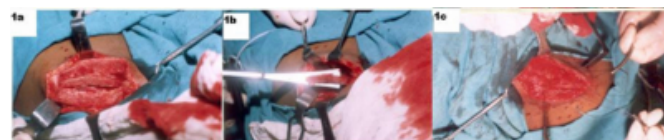most of the patients were between 20-30 age group (n-22). Most common indication for iliac crest bone graft harvesting was fresh trauma which was 54%(n-30) followed by non-union 25%(n-14), tumor reconstruction 7.1%(n-4), mal-union 5.4%(n-3), deformity correction 5.4%(n-3) and in chronic osteomyelitis 3.6%(n-2). Graft from ilium was harvested from either anterior or posterior cortex of the ilium depending upon the position of the patient. Graft from the anterior cortex was procured when patient was in supine or lateral position and from posterior cortex if patient was in prone or lateral position. Incision for anterior cortex was along the crest taken 2cm from ASIS and for the posterior cortex from PSIS along the crest, lateral extension of the incision varied depending upon the amount of the graft required. Methods, which we had used to harvest graft were- wolfe-kawamoto's, outer cortex, inner cortex, tricortical graft harvesting and trephine method.

In wolfe-kawamoto's technique we harvest full thickness graft by splitting off the iliac crest obliquely both medially and laterally so that the edges of the crest may be re-approximated after the bone has been excised[Fig 1a,b,c]. Graft from outer cortex harvested by exposing the outer table by sub-periosteal dissection of gluteal muscles, after outlining the area with an osteotome or power saw and the graft is peeled off by slight prying motions with a broad osteotome [Fig 2a]. To harvest the graft from inner cortex subperiosteal dissection was done to expose the inner table and graft harvested in same manner as in outer cortex method [Fig 2b]. To harvest the tricortical graft muscles were stripped from both sides of ilium and full thickness graft was harvested incorporating the inner, outer and superior cortex of ilium [Fig 2c]. In trephine technique cancellous graft could be harvested by using small curette from the intra-cortical space between inner and outer cortex

iliac crest was 9.6gms and from posterior crest was 13.3gms.

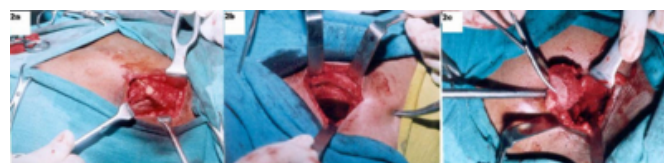**Figure 1**

Fig.1- Wolfe-kawamoto's technique [1a- iliac crest split off obliquely, 1b- full thickness graft harvested incorporating inner and outer table, 1c- reposition of edges of iliac crest after graft harvesting]



**Figure 2**

Fig.2- Methods of bone graft harvesting [2a- Outer table of crest exposed and graft harvested, 2b- graft harvested from inner table, 2c- tricortical full thickness graft harvesting]



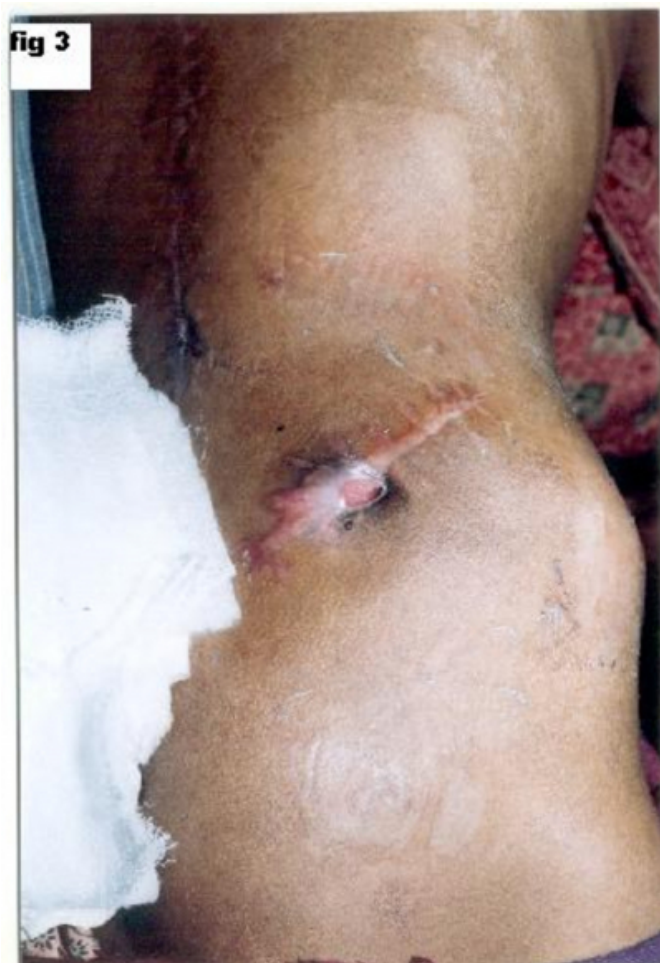Various intra-operative parameters like length of incision, amount of graft, blood loss, type of drain used and use of bone wax were noted down to study the comparison of techniques. Visual analogue scale used to assess the degree of the donor site pain, fine touch was tested to evaluate the extent of the cutaneous nerve injury and ultrasonography (n-1) was done detect the bowel herniation through the full thickness tricortical defect in ilium. Patients were followed up for at least 6 months post operative duration and assessed for donor site morbidities. Complications were described to be major or minor as per the definition given by Younger and Chapman.

## **RESULTS**

Graft from unilateral anterior iliac crest was harvested in 88%(n-49), from posterior iliac crest 11%(n-6), bilateral anterior iliac crest in 1.8%(n-1) patients. Wolfe-kawamoto's technique was used in 27%(n-15), graft from outer cortex was harvested in 55%(n-30), from inner cortex in 1(1.8%), tricortical full thickness graft in 14%(n-8) and by trephine method in 1(1.8%) patients. Corrugated latex drain was put in 77%(n-43), small capacity negative suction drain in 14%(n-8), large capacity negative suction drain in 7.1%(n-4) and no drain in 1.8%(n-1) patients. Bone wax was used in one patient. Average duration of graft harvesting was 20 minutes. Average amount of graft harvested from anterior

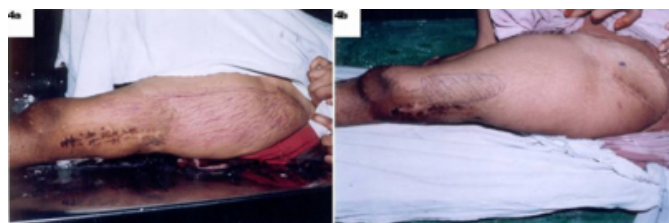
**Figure 3**

Fig.3- Persistent deep infection after bone graft harvesting from posterior



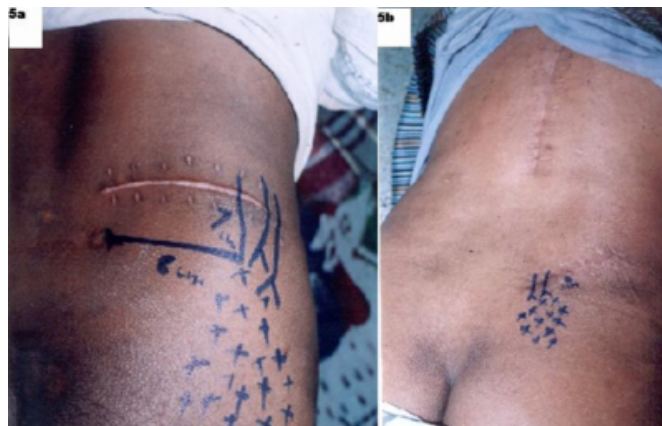**Figure 4**

Fig.4a- lateral cutaneous nerve injury following graft harvesting from anterior iliac crest, Iliac crest 4b- residual sensory loss at 6 months post surgery



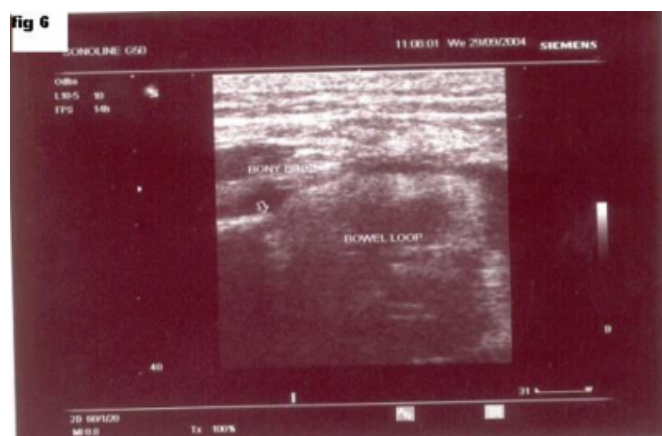
**Figure 5**

Fig.5- cluneal nerve injury [5a-superior cluneal nerve injury with the residual sensory loss



**Figure 6**

Fig.6- Incomplete hernia- ultrasonography of the crest showing the herniation of along its distribution, 5b-medial cluneal nerve injury with residual sensory loss at 6 months] bowel loop through the full thickness iliac defect after tricortical graft harvesting



All patients were evaluated for donor site morbidity during immediate post-operative period and for at least 6 months duration. Complication was labeled to be temporary if it was noted in immediate post-operative period and was absent at 6 months after surgery. If immediate post-operative complication was still present at 6 months, it was labeled residual complication. Donor site infection was present in 7.2%(n-4), out of which 5.4%(n-3) had superficial and 1.8%(n-1) had deep infection. In the patient with deep infection graft was removed from the posterior cortex, had persistent infection with discharging sinus even at 6 months after surgery[Fig 3]. Bone wax (n-1) was used as local hemostatic agent in same patient who had persistent deep infection (p-0.02). Total patients with cutaneous nerve injuries following graft harvesting were 14.3%(n-8), out of

them loss of sensation was temporary in 5.4% (n-3) and residual in 8.9% (n-5) patients. Lateral cutaneous nerve was involved in 6 patients who had undergone graft harvesting from anterior cortex, out of them only 3 patients had residual sensory loss at 6 months[Fig 4a,b]. Of all patients in which posterior iliac crest was approached, one patient had loss of sensation around the distribution superior cluneal nerve and one patient presented with sensory loss along the medial cluneal nerve, and both patients had residual sensory loss at 6 months[Fig 5a,b]. All patients with cutaneous nerve injuries had only hypoesthesia except one patient, who had meralgia paresthetica like symptoms, presented with distressing hyperesthesia and paresthesia along the distribution of lateral cutaneous nerve of thigh. Donor site pain was present in early post-operative period (up to 3 months, included in temporary group) in 5 patients (8.9%). Only one patient (1.8%) had residual donor site pain at 6 months. One patient, who had undergone tricortical graft harvesting from the anterior cortex developed hematoma at 4 weeks of surgery, which resolved with aspiration. One patient who had undergone tricortical full thickness graft harvesting from the anterior cortex, presented with dull ache pain only on straining and coughing over right lower quadrant of abdomen at the site of surgical wound on the anterior iliac crest. Ultrasonography showed the incomplete hernia through the full thickness defect in ilium[Fig 6]. All patients in which tricortical graft was harvested had cosmetic defect at the ilium. Total minor complications were 21.4%(n-12), and total major complications were 14.2%(n-8). Thus total donor site morbidity after iliac crest bone graft harvesting was 35.6%(n-20).

## DISCUSSION

Anterior and posterior iliac crest are good sources of large cancellous and cortico-cancellous graft. Anatomically, ilium is composed of an irregular posterosuperior surface and a concave anterosuperior surface. The ilium is thickest from 2 to 3 cm posterior to the anterior superior iliac spine and the posteroinferior ilium. The thickness of the ilium is 10.6 + 1.8 mm, 11.7 + 1.8 mm and 16.9 + 2.3 mm, at points 2 cm and 3 cm posterior to the ASIS and at the iliac tubercle, respectively and maximum graft could be harvest from the region around iliac tubercle<sup>13</sup>. Important neurovascular structures include the ilioinguinal, iliohypogastric, and lateral femoral cutaneous nerves anteriorly and the superior cluneal and gluteal nerves posteriorly. The lateral femoral cutaneous nerve is a sensory branch of the lumbar plexus and supplies sensation to the anterolateral thigh. It typically courses just under the inguinal ligament into the thigh,

medial to the anterior superior iliac spine<sup>1</sup>. Anatomical variation has been found in 10% of specimens, where lateral femoral cutaneous nerve descends vertically over the anterior pelvic brim approximately 2 cm lateral to the ASIS<sup>14</sup>. Lateral cutaneous branch of subcostal nerve can lie as close as 6 cm posterior to ASIS, therefore it is vulnerable to injury during bone graft harvesting from the iliac crest<sup>15</sup>. There are superior and middle cluneal nerves. The superior cluneal nerves are the cutaneous termination of the dorsal rami of L<sub>1</sub>, L<sub>2</sub>, L<sub>3</sub> and have been described as a group of three nerves, which pierce the lumbodorsal fascia just cephalad to the posterior iliac crest and pass over the crest beginning at a point approximately 7-8 cm lateral to the posterior superior iliac spine. Medial to PSIS lies the middle cluneal nerves, which are the cutaneous termination of the dorsal rami of S<sub>1</sub>, S<sub>2</sub> and S<sub>3</sub><sup>1</sup>.

Various methods of graft harvesting from iliac crest have been described - graft from outer cortex, graft from inner cortex, wolfe-kawamoto's method, tricortical graft, "trap-door" technique, "table-splitting" method and trephine technique<sup>1,5</sup>. Michael Saleh described the percutaneous method of harvesting the graft by using meunier trephine<sup>16</sup>. Percutaneous trephine technique was associated with significantly reduced postoperative pain, less pain on walking, less sensory disturbance and reduced local tenderness<sup>17</sup>. There are some newer techniques, which have been described like graft harvesting by using acetabular reamers, by raising an osteoperiosteal flap, and a modified technique for harvesting full-thickness iliac crest bone graft keeping edge of the iliac crest intact<sup>18,19,20</sup>.

Kurz et al. reported donor site pain persisting for more than 3 months in up to 15% of patients<sup>5</sup>. There was no difference in incidence between anterior and posterior wounds and the amount of pain seemed to be proportional to amount of dissection needed to obtain the bone graft. Summers and Eisenstein reported the incidence of chronic pain at the donor site to be 25% in those patients who had undergone anterior lumbar fusion for low back pain. Donor site pain had characteristic clinical feature, which may be severely disabling and was stubbornly resistant to treatment. The highest prevalence was in patients who had undergone tricortical full thickness graft taken through a separate incision overlying the iliac crest<sup>21</sup>. Fernyhaugh et al. explored the relationship between surgical approach and chronic pain at posterior iliac crest donor site. They found no difference in incidence of chronic donor site pain between harvests performed through lateral oblique incision (28% Vs



31%). The cause of the chronic donor site pain was assumed to be due to injury to superior cluneal nerves<sup>22</sup>. Colter John and Bednar reported that prevalence of donor site pain was greater in those patient where lateral oblique incision was given parallel to posterior cortex than in those patient where incision was taken perpendicular to posterior iliac crest<sup>23</sup>. Hill and Horne reported incidence of donor site pain to be 21.9 %, they termed the bone grafting from iliac crest as benign procedure and pain to be most significant morbidity<sup>24</sup>. Ross and Tacconi described an unusual case of recurrent iliac crest donor site pain secondary to heterotopic bone formations<sup>25</sup>. Robertson and Wray performed a prospective analysis of donor site morbidity. Silber and Anderson reported rate of donor site pain to be 26.1%, they stressed upon the used of alternative sources of graft material<sup>26</sup>.

Infection at donor site has been found to be of same frequency as for other clean orthopaedic procedures. Arrington et al reported incidence of 1.2% superficial and 1.7%, deep infections<sup>4</sup>. Kurz et al. reviewed the various complications of iliac crest donor site and they reported the involvement of lateral femoral cutaneous nerve in 10% of cases and also reviewed injury to superior cluneal nerves and found neuroma formation at the cut end of cluneal nerves requiring the excision<sup>5</sup>. Grossman and Ducey elaborated upon the meralgia paresthetica and explained that due to the varied anatomy of the lateral femoral cutaneous nerve, it is susceptible to get traumatized and non-operative management usually gave satisfactory results<sup>27</sup>. Elke Ahlmann et al reported residual sensory disturbance over the distribution of lateral femoral cutaneous nerve in 5% of cases<sup>2</sup>. Fernyhough et al. noted that the incidence of decreased sensations in area of the donor site with the separate lateral incisions was double that after a midline harvesting approach (43% Vs 19%), without any significant difference in incidence of chronic donor site pain in these two groups. He suggested incision to be more vertical than horizontal and its lateral limit should be within 7-8 cm of posterior superior iliac spine to minimize chances of injury to superior cluneal nerves<sup>22</sup>. Bents reported the case of ilioinguinal neuralgia following anterior iliac crest bone harvesting<sup>28</sup>. Dean chau et al. showed the vulnerability of subcostal nerve to injury during bone graft harvest from the iliac crest and found that the lateral cutaneous branch of the subcostal nerve may lie as close as 6 cm from the anterior superior iliac spine<sup>15</sup>.

Arrington et al. reported four cases of hematoma that

required re-operation<sup>4</sup>. Banwart et al. reported a four layer hemostatic closure that when combined with topical hemostatic agents were effective in decreasing the incidence of postoperative hematoma<sup>3</sup>. Oldfield reported the first case of hernia<sup>6</sup>. Brosworth evolved the method of repair of hernia, which consists of crest resection and closure, rotation of regional fascial flaps, and the use of synthetic mesh graft<sup>29</sup>. Recently Patten et al described novel technique for the repair of lumbar hernia after iliac crest bone harvest, in which they used corkscrew anchor suture device without any recurrence<sup>30</sup>. Porchet et al described the stress fracture of ilium following iliac crest bone harvesting, which occurs more commonly after procedures that harvest anterior portion of the iliac crest. They recommended the use of oscillating saw because osteotomes weakens the iliac crest<sup>7</sup>. Hul et al. showed the determinants of iliac crest strength and recommended, that the anterior vertical cut should be at least 3 cm posterior to the ASIS, based on their biomechanical analysis<sup>31</sup>. Lichtblau reported one of the earliest cases of pelvic instability after iliac crest bone graft harvest<sup>8</sup>. Coventry and Tapper, reported six cases of pelvic instability after harvest of the posterior iliac crest<sup>32</sup>. Chan et al. performed imaging study of nine patients and explored pelvic instability as a potential complication of bone graft harvesting from the posterior aspect of the iliac crest<sup>33</sup>. There have been reports of some rare complication following iliac crest bone graft harvesting. Brumback reported traumatic rupture of superior gluteal artery causing compartment syndrome of the buttock<sup>9</sup>. Escalas and Dewald reported a combined incidence of traumatic arteriovenous fistula and ureteral injury as a complication of iliac crest bone graft harvesting<sup>10</sup>. Dosoglu et al. reported a case of entero-cutaneous fistula following posterior iliac bone graft harvest where the tip of the osteotomic slipped anteriorly during the procurement, patient presented with spillage of formed fecal material from the donor site 12<sup>th</sup> day postoperatively<sup>11</sup>. Younger and Chapman, in a retrospective study of fifty-four patients in whom the incision for the primary procedure was also used to procure the graft from the posterior iliac crest, reported eleven (20 per cent) major and fifteen (28 percent) minor complications<sup>12</sup>.

In our study injury to the cutaneous nerve around the iliac crest was the major component of morbidity. Injury to cutaneous nerve was very distressing in one patient with paresthesia and burning pain along the distribution of lateral cutaneous nerve of thigh. Use of bone wax and proximity of the perineum may be the contributory factors for the deep persistent infection in one patient. Donor site pain was not

such a major problem as compared to other studies, as one (1.8%) patient had residual pain at 6 months. Tricortical graft harvesting definitely had more problems like hematoma, hernia and obvious cosmetic defect. We believe that with knowledge of anatomy and use of safer techniques like using wolf-kawamoto's and sub-crestal methods instead of removing tricortical graft, morbidity following graft harvesting can be minimized.

## References

1. Kirkham B Wood. Adult & Pediatric Spine, The 3rd Edition. Bone Grafting: Techniques and Complications, pp1192-99. Lippincott Williams & Wilkins, 2004.
2. Elke Ahlmann MD, Michael Patzakis, MD, Nikolaos Roidis, MD, MSc, Lane Shepherd, MD and Paul Holtom, MD. Comparison of anterior and posterior iliac crest bone grafts in terms of harvest-site morbidity and functional outcomes. *J Bone and Joint Surg Am* 2002;84-A:716-20.
3. Banwart JC, Asher MA, Hassanein RS. Iliac crest bone graft harvest donor site morbidity. *Spine* 1995;20:1055-60.
4. Arrington ED, Smith WJ, Chambers HG, et al: Complications of iliac crest bone graft harvesting. *Clin Orthop* 1996;329:300-9.
5. Kurz LT, Garfin SR, Booth RE. Harvesting autogenous iliac bone grafts: A review of complications and techniques. *Spine* 1989;14:1324-31.
6. Oldfield MC: Iliac hernia after bone grafting *Lancet* 1945;810-2.
7. Porchet F, Jaques B. Unusual complications at iliac crest bone graft donor site: experience with two cases. *Neurosurgery* 1996;39 (4):856-9.
8. Lichtblau, Sheldon. Dislocation of the Sacro-iliac Joint: A complication of Bone-Grafting. *J Bone and Joint Surg Am* 1962;44-A:193-8.
9. Brumback RJ. Traumatic rupture of the superior gluteal artery, without fracture of the pelvis causing compartment syndrome of the buttock: A case report. *J Bone Joint Surg Am* 1990;72:134-7.
10. Escalas F, DeWald RL: Combined traumatic arteriovenous fistula and ureteral injury: A complication of iliac crest bone grafts. *J Bone and Joint Surg Am* 1977;59:270-1.
11. Dosoglu M, Orakdogan M, Tevruz M, Gogusgeren MA, Mutlu F. Enterocutaneous fistula: A complication of posterior iliac bone graft harvesting not previously described. *Acta Neurochir* 1998;140(10):1089-92.
12. Younger EM, Chapman MW. Morbidity at bone graft donor sites. *J Orthop Trauma* 1989;3:192-5.
13. Ebraheim NA, Yang H, Lu J, Biyani A, Yeasting RA. Anterior iliac crest bone graft. Anatomic considerations. *Spine* 1997;22(8):847-9.
14. Ghent WR: Further studies on meralgia paresthetica. *Can Med Assoc J* 1961;85:871-5.
15. Chou D, Storm PB, Campbell JN. Vulnerability of the intercostal nerve to injury during bone graft harvesting from the iliac crest. *J Neurosurgery spine* 2004;(1):87-9.
16. Saleh M. Bone graft harvesting: a percutaneous technique. *J Bone Joint Surg Br* 1991;73-B:867-8.
17. Kreibich DN, Scott, IR, Wells JM, Saleh M. Donor Site Morbidity at the Iliac Crest: Comparison of Percutaneous and Open Methods. *J Bone And Joint Surg Br* 1994;76-B (5):847-8.
18. Sanders R, Di Pasquale T. A technique for obtaining bone graft. *J Orthop Trauma* 1989; 3(4): 287-9.
19. Grillon GL, Gunther SF, Connole PW. A new technique for obtaining iliac bone grafts. *J Oral Maxillofac Surg* 1984; 42(3):172-6.
20. Behairy YM, Al-Sebai W. A modified technique for harvesting full thickness iliac crest bone graft. *spine* 2001;26(6):695-7.
21. Summers BN, Eisenstein SM. Donor site pain from the ilium: A complication of lumbar spine fusion. *J Bone Joint Surg Br* 1989;71-B:677-80.
22. Fernyhaugh JC, Schimandle JJ, Weigel MC, Edwards CC, Levine AA. Chronic donor site pain complicating bone graft harvesting from the posterior iliac crest for spinal fusion. *Spine* 1992;17:1474-80.
23. Colterjohn NR, Bednar DA. Procurement of bone graft from iliac crest: An operative approach with decreased morbidity. *J Bone and joint Surg Am* 1997;79:754-9.
24. Hill NM, Horne JG, Devane PA. Donor site morbidity in the iliac crest bone graft. *Aust NZ J Surg* 1999;69(10):726-8.
25. Ross N, Tacconi L, Miles JB. Heterotopic bone formation causing recurrent donor site pain following iliac crest bone harvesting. *Br J Neurosurg* 2000;14(5):476-9.
26. Silber JS, Anderson DG, Daffner SD, Brislin BT, Leland JM, Hilibrand AS, Vaccaro AR, Albert TJ. Donor site morbidity after anterior iliac crest bone harvest for single level anterior cervical discectomy and fusion. *Spine* 2003;28(2):134-9.
27. Grossman MG, Ducey SA, Nadler SS, Levy AS. Meralgia paresthetica: diagnosis and treatment. *J Am Acad Orthop Surg* 2001;9(5):336-44.
28. Bents RT. Ilioinguinal neuralgia following anterior iliac crest bone harvesting. *Orthopaedics* 2002;25(12):1389-90.
29. Bosworth DM: Repair of hernia through iliac crest defects. *J Bone Joint Surg Am* 1955;37-A:1069-73.
30. Patten LC, Awad SS, Berger DH, Fagan SP. A novel technique for the repair of lumbar hernias after iliac crest bone harvest. *Am J Surg* 2004;188 (1):85-8.
31. Hu RH, Hearn T, Yang J. Bone graft harvest site as determinant of iliac crest strength. *Clin Orthop* 1995;310:252-6.
32. Coventry MB, Tapper EM: Pelvic instability: A consequence of removing iliac bone for grafting. *J Bone Joint Surg Am* 1972;54A:83-101.
33. Chan K, Resnick D, Pathria M, Jacobson J. Pelvic instability after bone graft harvesting from posterior iliac crest: Report of nine patients. *Skeletal Radiol* 2001;30(5):278-81.

**Author Information**

**Sunil Kukreja**

Department of Orthopedics, NSCB Medical College Hospital

**HKT Raza**

Department of Orthopedics, NSCB Medical College Hospital

**Alok C Agrawal**

Department of Orthopedics, NSCB Medical College Hospital