

Bilateral Laparoscopic Nephrectomy For Autosomal Dominant Polycystic Kidney Disease

H Tiong, T Shim, Y Lee, J Tan

Citation

H Tiong, T Shim, Y Lee, J Tan. *Bilateral Laparoscopic Nephrectomy For Autosomal Dominant Polycystic Kidney Disease*. The Internet Journal of Urology. 2007 Volume 5 Number 2.

Abstract

In patients with autosomal dominant polycystic kidney disease (ADPKD) and end stage renal failure, the indications for nephrectomy include cyst rupture, haemorrhage, compression, renal calculi, hypertension and infection. It may also be a preparatory measure preceding kidney transplantation. Laparoscopic nephrectomy is associated with decreased morbidity but is technically challenging. We present our initial experience of laparoscopic synchronous bilateral nephrectomy and specimen extraction.

A transperitoneal laparoscopic approach was undertaken for bilateral nephrectomy in a 61 year old female with symptomatic ADPKD and end stage renal failure. A 3-port technique was used with the patient in a lateral position on each side. Selective cyst aspiration was crucial to increase the working space for safe hilar dissection and ligation. Specimen extraction was performed via a muscle splitting Pfannenstiel incision after both kidneys were resected and placed in laparoscopic specimen bags.

The operation was uncomplicated. Total operative time was 430 minutes. Pre and post operative hemoglobin levels were 12.6 g/dL and 9.5 g/dL respectively. Normal diet was resumed on day 3 and the patient was fit for discharge.

Laparoscopic nephrectomy is challenging due to the large kidney size but can be made manageable with cyst aspiration. En bloc extraction through a Pfannenstiel incision further facilitates recovery.

INTRODUCTION

Autosomal dominant polycystic kidney disease (ADPKD) affects 500,000 people in the United States and is the direct cause of renal failure for 5 to 10% of patients with end stage renal failure [1, 2]. It is a hereditary disorder, caused by a mutation in either ADPKD-1 or ADPKD-2 genes, resulting in the abnormal synthesis of polycystin-1 and polycystin-2 proteins respectively. The clinical syndrome is characterised by the progressive compression and replacement of normal renal tissue by multiple enlarging cysts. Progressive renal failure develops in 45% of patients by the age of 60 years [2].

In addition, up to 60% of patients with ADPKD suffer from pain due to cyst rupture with hematuria or cyst haemorrhage, cyst compression, recurrent renal calculi formation, hypertension and infection. The management of these symptoms is generally restricted to conservative measures. Surgical treatment is reserved for symptomatic cases refractory to medical treatment. In patients with established

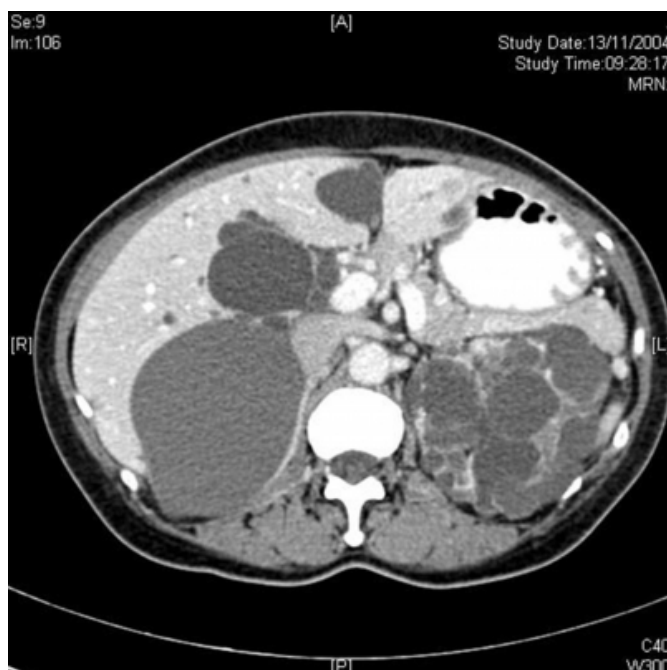
end-stage renal disease, these symptoms can be alleviated significantly by unilateral or bilateral nephrectomy, which may also be an indicated measure preceding kidney transplantation in recurrent infected cysts or extremely large polycystic kidneys. Bennet et al first reported open nephrectomy in 31 cases of ADPKD patients with a relatively high 38% morbidity and 3% mortality [3]. Recently, laparoscopic nephrectomy for ADPKD has been reported with the advantages of decreased blood loss, post-operative analgesia requirement and hospital stay compared to the open approach [4,5,6,7,8]. However, the large kidney size often results in technical difficulties in terms of adequate space for hilar control and the optimum technique for organ extraction is still evolving, especially if bilateral nephrectomy is performed in the same operative session [6,7,8]. We present our initial experience of bilateral laparoscopic transperitoneal nephrectomy in ADPKD, with a focus on our method of removal of the surgical specimen via a Pfannenstiel skin incision.

CASE HISTORY

A 60-year-old lady with ADPKD and end stage renal failure on haemodialysis for 3 years presented with a history of recurrent episodes of gross hematuria, associated with abdominal pain, distention and early satiety. Her other co-morbidities included hypertension, dyslipidaemia and uterine leiomyoma. A computer tomography revealed multiple cysts enlarging both kidneys, resulting in minimal residual intervening parenchyma (Figure 1). The largest cyst was seen in the right upper pole with a size of 9.2 x 7.3 cm. Features of scattered mural calcifications and increased density pre-contrast within multiple cysts bilaterally were noted, indicative of haemorrhage. There were no suspicious enhancing masses either in the residual parenchyma or within the cyst cavities. No hydronephrosis or perinephric fluid collection was evident. The liver also shows similar cystic lesions throughout both lobes. Surgical options including open and laparoscopic nephrectomy, cyst decortication were discussed with the patient and bilateral laparoscopic nephrectomy was elected to maximise symptom relief for her.

Figure 1

Figure 1: CT abdomen demonstrating bilateral enlarged cystic kidneys and liver.



TECHNIQUE

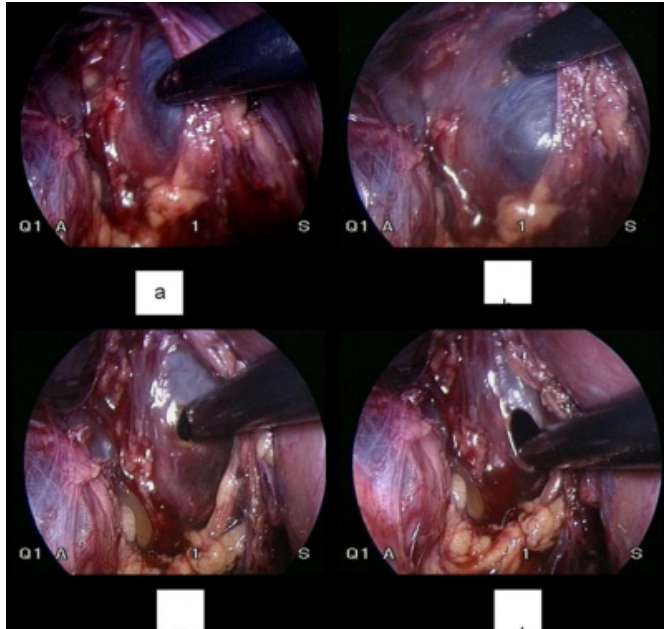
Under general anaesthesia, the patient was placed in the lateral decubitus position with the left side up initially. The patient was secured using tapes and belts, with the left kidney bolstered up with bean bag. Both the surgeon and

assistants stood anterior to the patient and the endoscopic monitors were positioned to the right and left of the operating table. The patient received preoperative antibiotics.

A 15 mm Hg carbon dioxide pneumoperitoneum was established with a 10 mm laparoscopic cannula (primary camera port) placed lateral to the umbilicus at the level of the left rectus border using an open technique. Two further ports of 5mm and 12 mm (Versaport, Autosuture, Tyco Healthcare) were placed under direct vision in a gentle arc formation. A 30o-viewing 10 mm laparoscope was then inserted through the primary camera port. On the left side, the descending colon was mobilized medially to expose the kidney. To facilitate safe dissection of the hilum, the large kidney was made manageable by reducing its volume through cyst puncture and aspiration. This was performed with a combined laparoscopic suction irrigator and diathermy hook (Surgiwand II, Autosuture, Tyco healthcare) to minimize cyst contents spillage (Figure 2). In addition, cyst drainage was carried out in a selective manner to drain as few cysts as is needed to provide adequate working space. Subsequently, the renal vein and artery were dissected sequentially and individually ligated with either 10 mm plastic locking clips (Hem-o-lok, Autosuture, Tyco healthcare) or 12 mm endoscopic vascular staplers (Endo GIA, Autosuture, Tyco healthcare). Further dissection in the renal hilum was performed to ensure all secondary vessels were secured and divided. The ureter was clipped and divided and the kidney mobilised within the Gerotas fascia, leaving the adrenal gland intact. After the kidney had been completely mobilised, the primary camera port was removed and exchanged for a 15 mm laparoscopic specimen bag (Endocatch II, Autosuture, Tyco healthcare). The resected left kidney was placed within the specimen bag and its opening was closed securely to ensure no spillage of its contents. The specimen bag was left within the pelvis in the left iliac fossa. After hemostasis was confirmed, all 3 port site incisions were closed.

Figure 2

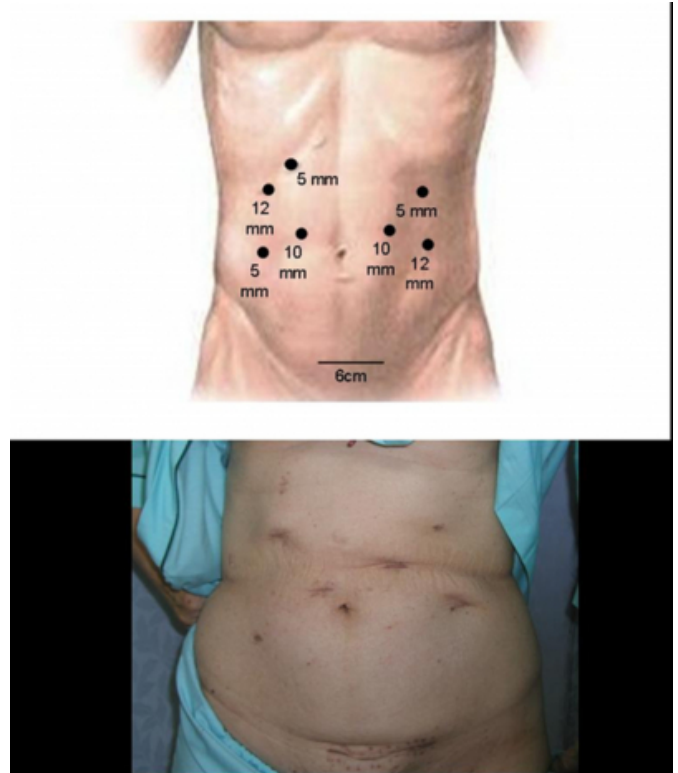Figure 2: Photo sequence (a to d) showing the use of a combined laparoscopic suction irrigator and diathermy hook to incise and drain a large renal cyst, providing space to mobilise the right upper pole of kidney from the liver and minimizing cyst contents spillage.



The patient was then repositioned on the opposite flank. Intraperitoneal laparoscopic nephrectomy was performed in a similar manner. On the right side, the colon and duodenum was mobilized to expose the kidney. An additional 5mm port was used for liver retraction to facilitate dissection. After resection and hemostasis, the intact specimen was placed in a second laparoscopic specimen bag (Endocatch II). A transverse muscle splitting pfannensteil incision approximately 6 cm long was made for specimen extraction. Following incision of the rectus sheath, the rectus muscles were separated in the midline to expose the peritoneum. Under laparoscopic vision, the peritoneum was bluntly punctured from externally with a finger, which retrieved the strings attached to both laparoscopic specimen bags. Intact manual extraction of each of the kidneys was performed in a transverse orientation through the pfannestial incision. This incision and the 3 port sides were closed after a thorough 2-litre washout and insertion of Jackson Pratt drain. Figure 3 shows port site positions and specimen extraction incision.

Figure 3

Figure 3: Schematic diagram and photo showing port site positions and specimen extraction incision.



Total operative time was 430 minutes and subsequent postoperative recovery was uneventful. Blood loss was estimated to be less than 500 mls. Pre and postoperative haemoglobin levels were 12.6 g/dL and 9.5 g/dL respectively and no blood transfusion was required. The immediate post-operative pain score was 6 on a pain analogue scale of 0 to 10. This decreased to 3 and 0 on day 1 and day 2 respectively, using oral analgesia including paracetamol and codeine phosphate. Haemodialysis was resumed on day 1. Ambulation was started on day 2 and normal diet resumed on day 3. Drain volumes varied from 90 to 390 mls of bloodstained fluid and the drain was removed on day 5. Subsequently, the patient was fit for discharge.

DISCUSSION

With the introduction of minimally invasive surgical techniques, the current management of symptomatic ADPKD is evolving. Failing conservative management, several minimally invasive options are available, including percutaneous aspiration, sclerosis, and laparoscopic marsupialization or cyst decortication [9, 10]. As these treatment options do not completely ablate all the cysts, pain and other symptoms can recur with time. For ADPKD

patients with end stage renal failure on renal replacement therapy, a more durable response is achieved with unilateral or bilateral nephrectomy. The laparoscopic approach is technically difficult due to the large renal size, surrounding fibrosis and difficulty in identifying associated renal vessels; this is even more demanding when bilateral synchronous nephrectomy is contemplated. Laparoscopic nephrectomy in ADPKD with or without hand assist, using intraperitoneal or retroperitoneal approach, has been reported in case control series from tertiary centers [4,5,6,7,8]. These consistently demonstrate a superior outcome in terms of blood loss, post-operative analgesia requirements, and hospital stay when compared to the open approach. The optimal approach is still under development and our initial case was performed with the objective of addressing the current issues regarding cyst aspiration during dissection and specimen extraction technique.

Cyst aspiration in laparoscopic nephrectomy for ADPKD is important for the debulking of the kidneys in order to create sufficient intraabdominal working space and to access the renal vessels for ligation. There is a potential risk of localised chemical peritonism and septic complications from the spillage of cyst contents. Currently, this is fortunately uncommon and has not occurred in most published case series of laparoscopic nephrectomies [4, 5] or cyst marsupialization [9]. However, it is seen in a minority of patients from bilateral single stage nephrectomy case series [6,7,8] and this may be due to the greater volume of cyst spillage compared to unilateral cases. In the above case, several steps were taken to prevent this possible complication. Pre-operatively, all ongoing sepsis should be treated and prophylactic antibiotics given. During the surgery, we adopted selective cysts aspiration, draining as few cysts as possible. In addition, the use of a combined laparoscopic suction irrigator and diathermy hook to puncture and aspirate the cysts ensured minimal spillage of cyst contents and also eliminated repeated instrument changes. Thorough washout of the abdomen at the end of the procedure and the use of a drain post operatively further ensured that the risk of any septic complications is minimal.

In bilateral synchronous nephrectomy for ADPKD, the extraction of the specimen en bloc presents a particular challenge. Besides morcellation, midline wound extraction is the general convention, regardless of whether hand assist

was used. We believe that the advantage of a pure laparoscopic approach over a hand assist one is that the former facilitates the organ extraction through a low transverse muscle splitting incision, which has a lower morbidity and better cosmetic result than a midline longitudinal incision. In addition, a low transverse incision will also not affect any potential renal transplantation site.

CONCLUSION

Laparoscopic nephrectomy is feasible but challenging in patients with ADPKD. The technical difficulties due to the large kidney size can be made manageable with cyst aspiration. However, steps should be taken during cyst aspiration to minimise spillage and potential infective complications. En bloc extraction through a pfannensteil incision is possible with a laparoscopic technique to provide a cosmetic scar with low morbidity.

References

1. Parfrey, P. S., Bear, J. C., Morgan, J. et al: The diagnosis and prognosis of autosomal dominant polycystic kidney disease. *N Engl J Med*, 323:1085, 1990.
2. Gabow PA. Autosomal dominant polycystic kidney disease. *N Engl J Med* 329:332, 1993.
3. Bennet AH, Stewart W and Lazarus JM.:Bilateral nephrectomy in patients with polycystic renal disease. *Surg Gynecol Obstet* 137:819, 1973.
4. Dunn M. D., Portis A. J., Elbahnasy A. M., et al: Laparoscopic nephrectomy in patients with end stage renal disease and autosomal dominant polycystic kidney disease. *Am J Kidney Dis* 35:720, 2000.
5. Seshadri P. A., Poulin E. C., Pace D., et al: Transperitoneal laparoscopic nephrectomy for giant polycystic kidney disease: a case control study. *Urology* 58: 23, 2001.
6. Rehman J., Landman J., Andreoni C., et al: Laparoscopic bilateral hand assisted nephrectomy for autosomal dominant polycystic kidney disease: initial experience. *J Urol* 166: 42, 2001.
7. Jenkins M. A., Crane J. J., Munch L. C: Bilateral hand assisted laparoscopic nephrectomy for autosomal dominant polycystic kidney disease using a single midline handport incision. *Urology* 58:32, 2002
8. Gill I. S., Kaouk J. H., Hobart M. G., et al: Laparoscopic bilateral synchronous nephrectomy for autosomal dominant polycystic kidney disease: the initial experience. *J Urol* 165: 1093, 2001.
9. Lifson B. J., Teichman J. M. H and Hulbert J. C.: Role and long term results of laparoscopic decortication in solitary and autosomal dominant polycystic kidney disease. *J Urol* 159: 702, 1998.
10. Dunn M. D., Portis A. J., Naughton C., et al: Laparoscopic cyst marsupialization in patients with autosomal dominant polycystic kidney disease. *J Urol* 165: 1888, 2001.

Author Information

Ho Yee Tiong, B. Med. Sci BM. BS MRCS FAMS(Urology)

Department of Urology, Tan Tock Seng Hospital

Timothy Shim, MB. BS MRCS

Department of Urology, Tan Tock Seng Hospital

Yee Mun Lee, MB. BS FRCS FAMS (Urology)

Department of Urology, Tan Tock Seng Hospital

James Khaw Ngiap Tan, MB. BS FRCS FAMS (Urology)

Department of Urology, Tan Tock Seng Hospital