

# Case Report Of A Very Long Foreign Body In Urinary Bladder

B Jani, S Aldujaily, N Katiyar

## Citation

B Jani, S Aldujaily, N Katiyar. *Case Report Of A Very Long Foreign Body In Urinary Bladder*. The Internet Journal of Urology. 2005 Volume 4 Number 1.

## Abstract

A case report of 20 year old man, who presented after self introduction of 95 cms long plastic tube in his urinary bladder, is described here.

## INTRODUCTION

Self-introduction is one of the causes of foreign body in urinary bladder. Considering the complex anatomy of urethra, it is more difficult for the foreign body to reach the urinary bladder in males. This is a rather unusual instance where a foreign body of this size has reached the urinary bladder in a male.

## CASE SUMMARY

A 20 year old man presented after inserting a long plastic tube inside his penis and unable to retrieve it. On direct questioning, he admitted of doing this for pleasure. On clinical examination foreign body was not visible on inspection of external urethral meatus or palpation of his penis. Plain X-ray was unremarkable. He underwent a rigid cystoscopy under general anaesthesia. During the procedure, Patient was found to have a 95 cms long plastic tube all the way inside the urinary bladder. (Fig 1 and 2) It was removed with the help of biopsy forceps. He had an uneventful recovery and was discharged home.

Figure 1


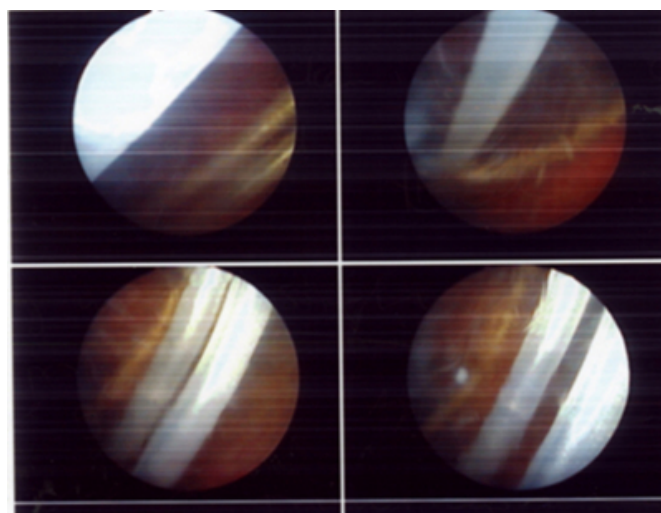


Figure 2



## DISCUSSION

Urinary Bladder is the commonest site of foreign body in the urinary tract and if neglected can lead to complications. A large variety of foreign body in urinary bladder have so far been reported (1, 2). Instances of Calculus formation secondary to long standing foreign body have been reported (3). It can also lead to chronic cystitis which in turn can lead to bilateral hydronephrosis with hydroureter and renal failure (4). Cystoscopy is the best way to manage these patients which could be diagnostic and therapeutic. Plain X-ray may be useful in some cases. In some cases an open surgery may be needed to remove the foreign body if cystoscopy is not successful (2).

## References

1. Eckford SD, Persad RA, Brewster SF, Gingell JC Intravesical Foreign Bodies: Five Year Review. British Journal of Urology 1992 (69)

2. Van Ophoven A, De Kernion JB Clinical Management of foreign bodies of genitourinary tract. J Urol 2002 (164)
3. E S Garba A O Oguntayo Secondary vesical calculus following translocated IUCD in Urinary Bladder Grand Rounds Gynaecology Vol 3
4. R I Bhatt, M Lau V A C Ramani, Renal Failure secondary to foreign body in Bladder British Journal of Urology 2001 (88)

**Author Information**

**Bhautesh Jani, MBBS**

Department of Urology, Basildon University Hospital

**Saad Aldujaily, FRCS**

Department of Urology, Basildon University Hospital

**Nikhil Katiyar, MBBS**

Department of Urology, Basildon University Hospital