

# Experiences of Single Technique in Removing Nasal leech Infestation: An analysis of 25 cases

P Adhikari

## Citation

P Adhikari. *Experiences of Single Technique in Removing Nasal leech Infestation: An analysis of 25 cases*. The Internet Journal of Otorhinolaryngology. 2008 Volume 9 Number 2.

## Abstract

**Objective:** The objective of this study is to describe our technique to remove the nasal leeches and to observe the results with this technique. **Material and Methods:** This prospective study was carried out in 25 patients attending Department of ENT and Head and Neck Surgery, TU Teaching Hospital, Kathmandu, in patients with history suggestive of leech infestation in the nasal cavity. Patients between April 2004 and December 2008 were enrolled for the study. All age groups were included. The technique includes wait and watch policy in the treatment room. In this technique, water was poured into the kidney tray and adjusted 1cm below the nasal vestibule. As soon as the leech was seen in nasal vestibule coming towards the water, they were caught with artery forceps. Time taken to remove the leech, bleeding status, assessment of pain and patient's /caretaker's satisfaction were evaluated. No local anaesthesia or sprays was used. Informed consent and ethical approval for the study was taken. Statistical analysis was done using frequency and percentage. **Results:** Out of 25 patients, 17 were male and 8 were female. Age ranges from 2 years to 45 years. Symptomatology includes- Bleeding from nose (88%), foreign body sensation in nose (80%) and nasal obstruction (74%). Positive history of leech infestation was present in 80% cases. The mean time taken to remove the leech was 30.25 minutes. No patients experienced bleeding and pain during the procedure. All of the parents/ caretakers/understandable children were fully satisfied with the procedure. **Conclusion:** Wait and watch policy (keeping the water in kidney tray just below the nasal vestibule) is a better technique because of less pain and less blood loss with full satisfaction to the patients and caretakers, though it is more time consuming.

## INTRODUCTION

Leech infestation primarily occurs in tropical areas, such as in Mediterranean countries, Africa and Asia [1]. Leeches are blood – sucking a hermaphroditic parasite that varies in color and length [2]. They are cylindrical or leaf like in shape, depending on the contraction of their bodies [2]. Leeches enters the human body when the polluted water is drunk, and they localize in the mucosa of the oropharynx, nasopharynx, tonsils, esophagus or nose but rarely in larynx [34]. The objective of this study is to observe the results of an innovative technique in removing the nasal leech infestation. This is the first study on nasal leech infestation done in a larger sample size and removed with the same technique which makes this study more relevant.

## MATERIAL AND METHODS

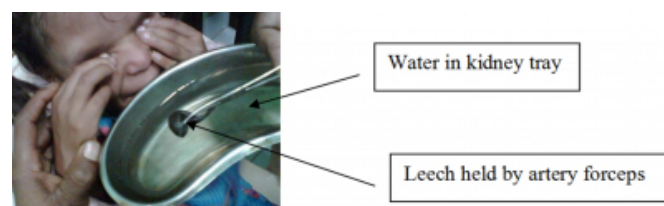
This prospective study was carried out in 25 patients attending Department of ENT and Head and Neck Surgery, TU Teaching Hospital, Kathmandu, in patients with history suggestive of leech infestation in the nasal cavity. Patients

between April 2004 and December 2008 were enrolled for the study. All age groups were included.

Proper history and examination performed and recorded in performa. The technique includes wait and watch policy in the treatment room. In this technique, water was poured into the kidney tray and adjusted 1cm below the nasal vestibule. As soon as the leech was seen in nasal vestibule coming towards the water, they were caught with artery forceps (Fig-1).

### Figure 1

Figure 1: Showing the technique to remove the leech.



Time taken to remove the leech, bleeding status, assessment

of pain and patient's /caretaker's satisfaction were evaluated. Nasoendoscopy was done to confirm the diagnosis in clinically suspected cases not removed by these techniques. No local anaesthesia or sprays was used. Informed consent and ethical approval for the study was taken. Statistical analysis was done using frequency and percentage.

### RESULTS

Out of 25 patients, 17 were male and 8 were female. Age ranges from 2 years to 45 years. Symptomatology includes- Bleeding from nose (88%), foreign body sensation in nose (80%) and nasal obstruction (74%). Positive history of leech infestation was present in 80% cases. The mean time taken to remove the leech was 30.25 minutes. No patients experienced bleeding and pain during the procedure. All of the parents/ caretakers/understandable children were fully satisfied with the procedure.

### DISCUSSION

In a country like Nepal, leech infestation should also be considered as an important cause for unilateral intermittent epistaxis. Common species that can manifest humans are *Dinobella ferox*, *Hirudinea granulose* and *Hirudinea viridis* [5]. Both, aquatic and land leeches are known to attack humans.

When water is drunk from streams or puddles, leeches can infest the human body. They can then be located anywhere in the upper respiratory tract from the nose to the larynx. Leeches are blood sucking hermaphroditic parasites that attach themselves to vertebrate hosts, bite through the skin, and suck out blood [6]. Leeches attach to the tissues by two muscular suckers, use three teeth inside their anterior sucker for biting and blood amounting ten times its body weight is sucked into stomach by peristalsis [7].

Leech infestation has not been mentioned as a cause of epistaxis in standard textbooks [8]. Because leech bites are painless, the infestation remains symptomless until a warning sign appears. Epistaxis, nasal obstruction and sensation of a moving foreign body are the usual presenting complains of a leech in the nose [9]. The saliva of the leech contains hirudin, which inhibits thrombin in the clotting process, and histamine like substances which may cause continuous bleeding by preventing closure of capillaries [10]. It can be paralysed by anaesthetic agents which cause the worm to migrate towards the surface. Its attachment to the nasal mucosa makes the leeches weak resulting in easy removal. But in this study, we used a technique of wait and

watch policy by keeping the kidney tray filled with water just below the nasal vestibule. This technique is beneficial when local sprays or injections are not available in remote areas.

From this study, we can say that there is a high prevalence of leech infestation in Nepal. This is because of the fact that in the literature only few cases are reported about this disease. Because these locations are not readily visualized, endoscopic assessment is generally required for diagnosis. But only 5.0% needed endoscopic assessment in our study. So, even when the facility of endoscopy is not available, we can remove the leech by this innovative technique as explained in our study, when there is a positive history of leech infestation.

If a foreign body in the nasal cavity is a leech, it presents an emergency that requires immediate attention, because after leeches attach themselves to a mucous membrane, they ingest blood, which weighs on average 8.9 times their weight [11]. They may cause severe anaemia, which may require blood transfusion [12].

Diagnosis is easy when a leech is in the nasal cavity. Direct removal of a leech might be difficult because of its powerful attachment to the mucosa and its slimy and mobile body [13]. Techniques for the removal of nasal leeches vary from using forceps for immediate extraction to the use of various substances to tranquilize the leech or relieve pain as the parasite is being removed [4]. If the leech is in the nares or upper pharynx, it can be detached by applying 30% cocaine, 1:10,000 adrenalin or dimethyl phthalate to it [2]. Another method is irrigation with strong saline, vinegar, turpentine, or alcohol. This is the first study done in the literature with a larger sample size and introducing an innovative technique.

### CONCLUSION

Wait and watch policy by keeping the water in kidney tray just below the nasal vestibule is one of the good technique because of less pain and less blood loss with full satisfaction to the patients and caretakers, though it is more time consuming process. Leech infestation should be considered in the differential for epistaxis, particularly in leech-endemic areas. Endoscopic evaluation of nasal cavity is mandatory in recurrent epistaxis, particularly when the cause is not obvious.

### References

1. Uygur K, Yasan Haran, Yavuz Lutfi and Harun Digru. Removal of laryngeal leech: A safe and effective method. *Am J Otolaryngol* 2003;24 (5):338-40.

2. EI- Award ME, Patik K. Jaematemesis due to leech infestation. *Ann Trop Paediatr* 1990;10:61-62.
3. Kaygusuz I, Yachin S, Keles E. Leeches in the larynx. *Eur Arch Otorhinolaryngol* 2001;258:455-7.
4. Bilgen C, Karci B, Uloz U. A nasopharyngeal mass: Leech in the nasopharynx. *Int J Pediatr Otorhinolaryngol* 2002;64:73-6.
5. Gangadharan SKS, Rajesgwor A. An unusual foreign body in the nose. *Gujarat J Otolaryngol Head Neck Surg* 2005;2:21-22.
6. Foonant S, Puntasri W, Manorot M, Niwasabuttra S.. A leech in the nasal cavity: case report. *Chiang Mai Med Bull* 2006;45(1):27-30.
7. Robert W. The fall and rise of medicinal leech. *Student BMJ* 1998: Education.
8. Satyawati, Singhal SK, Dass A. Multiple live leeches from nose in a single patient- a rare entity. *Indian J Otolaryngol Head Neck Surg* 2002;54(2):154-5.
9. Garcia AD, Martin AM, De Luna Gijan CE et al. Leech in the epiglottis: an unusual discovery in our times. *Am J Otolaryngol* 2002;23:91-2.
10. Faust EC, Russel PF, Jurg RC. Criag and Faust's clinical parasitology. 8th ed. Philadelphia: lea and Febiger;1970:563-70.
11. AI- Hadrani, Debry C, Faucon F, Fingerhut A. Hoarseness due to leech ingestion. *J Laryngol Otol* 2000;14:145-6.
12. White GB. Leeches and leech infestation. In Cook GC, Manson's Tropical Diseases. 20th ed. London: Saunders;1998:1523-5.
13. Pandey CK, Sharma R, Baronia A, Agrawal A, Singh N. An unusual cause of respiratory distress: live leech in the larynx. *Anesth Analg* 2000;90:1227-8.

**Author Information**

**Prakash Adhikari, MS**

Resident, Department of ENT and Head and Neck Surgery, GMS Memorial Academy of ENT and Head and Neck Studies,  
TU Teaching Hospital