

Urinary Bladder Rupture Associated With Squamous Cell Carcinoma Of The Bladder; A Cause Of Acute Peritonitis

H Ohzawa, W Arai, Y Kondo, S Endo, T Morita, S Matsubara

Citation

H Ohzawa, W Arai, Y Kondo, S Endo, T Morita, S Matsubara. *Urinary Bladder Rupture Associated With Squamous Cell Carcinoma Of The Bladder; A Cause Of Acute Peritonitis*. The Internet Journal of Urology. 2009 Volume 7 Number 2.

Abstract

Spontaneous rupture of the urinary bladder associated with bladder cancer is very rare. Its signs and symptoms are those of peritonitis, and thus non-specific, possibly causing diagnostic confusion. A 69-year-old man with a history of macrohematuria and possible neurogenic bladder presented with signs of peritonitis. Laparotomy revealed bladder rupture associated with squamous cell carcinoma of the bladder. This condition should be added as a differential diagnosis of peritonitis, especially with a history of urinary symptoms.

INTRODUCTION

Clinical presentations of bladder rupture in an acute phase are usually those of peritonitis and thus non-specific¹, possibly leading to diagnostic confusion. Spontaneous rupture of the urinary bladder associated with bladder cancer is very rare. This report presents the case of a 69-year-old man with rupture of the urinary bladder associated with squamous cell carcinoma of the bladder.

CASE REPORT

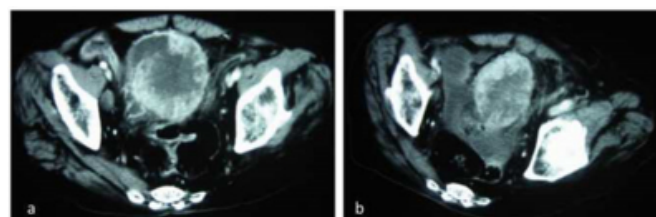
A 69-year-old man was admitted with acute severe lower abdominal pain after urination. He had noticed macrohematuria and had had intermittent lower abdominal pain since 3 months before. He had gait disturbance due to spinal cord injury as a result of attempted suicide by jumping.

On admission, he had blood pressure 152/95 mmHg, pulse rate 111 bpm, and body temperature 37.2 °C, with tenderness with guarding in the left lower quadrant. Macrohematuria was observed, with urinalysis revealing protein and white blood cells. Laboratory data were: white blood cells, $18.8 \times 10^9/L$; C-reactive protein, 11.4 mg/dL; serum creatinine, 1.2 mg/dL. Abdominal computed tomography (CT) revealed bladder tumors in the entire bladder, which was distended with urine (Fig. 1a). The perivesical area and sigmoid colon wall showed thickening, compatible with tumor invasion to the sigmoid colon. No free air or ascites were observed. We diagnosed this condition as localized peritonitis due to bladder cancer

invading the sigmoid colon. Antibiotics improved his symptoms and laboratory data.

Figure 1

Figure 1. Imaging findings of contrast-enhanced computed tomography on admission (a) and on day 3 (b).



a. Markedly enhanced tumor of the bladder is noted.

b. Massive ascites is noted. Compared with (a), urine volume and bladder tension appear to be decreased. This may suggest perforation of the bladder, which was not noticed before laparotomy.

On day 3 the abdominal pain suddenly increased and a CT revealed massive ascites (Fig. 1b), necessitating an emergent laparotomy. The bladder wall was markedly thickened and infiltrated by a tumor that had invaded the sigmoid colon through the adjacent mesentery. The dome of the bladder had a 1cm diameter perforation, through which urine was leaking. A partial cystectomy followed by primary closure and a partial sigmoid colectomy were performed. Histological examination of the excised bladder revealed poorly differentiated squamous cell carcinoma (SCC). His general condition deteriorated and he died 2 months

postoperatively.

DISCUSSION

This case brought up three important clinical issues. First, bladder cancer, although rare, could cause bladder rupture, leading to acute onset of peritonitis. A Pubmed and manual search yielded 18 cases of bladder rupture associated with bladder cancer (Table 1)¹⁻¹⁶. The present case is, to our knowledge, the 19th such case. While transitional cell carcinoma accounted for 7 (37%: 7/19), SCC accounted for 9 (47 %: 9/19), showing a stark contrast to <5%, the reported incidence of SCC among bladder cancer. SCC may be vulnerable to perforation, the reason for which is unclear.

Figure 2

Table 1. Reported cases of bladder rupture associated with bladder cancer

Author ^{ref} (reported year)	Age and sex	Presenting symptoms	Previous urinary symptoms	Diagnosed before or during surgery	Histology
Bastable ² (1959)	57 M	suprapubic pain	Yes	During	polypoid carcinoma
	57 M	lower abdominal pain	Yes	Before	TCC
Glashan ³ (1967)	43 F	upper abdominal pain, nocturia	No	During	SCC
	38 M	generalized abdominal pain	No	During	TCC
Agapitidis ⁴ (1976)	82 M	abdominal pain	Yes	During	undetermined*
Jenkins ⁵ (1981)	73 F	lower abdominal pain	Yes	During	SCC
Powell ⁶ (1983)	42 M	lower abdominal pain	Yes	Before (cystoscopy)	TCC
Huffman ⁷ (1983)	49 F	abdominal pain	Yes	During	SCC
Budd ⁸ (1984)	79 F	generalized abdominal pain, urine incontinence	Yes	During	TCC
Wujanto ⁹ (1989)	79 F	lower abdominal pain	No	During	SCC
Sorensen ¹⁰ (1991)	51 F	swelling and discoloration of the abdominal wall	Yes	At autopsy	urothelial carcinoma
Gough ¹¹ (1992)	77 F	suprapubic pain	Yes	During	SCC
Rasmussen ¹ (1993)	61 F	abdominal pain	Yes	During	TCC
O'Neill ¹² (1997)	46 M	lower abdominal pain, hematuria, fever	Yes	Before (CT cystogram)	TCC
Atalay ¹³ (1998)	75 F	abdominal pain, nausea, vomiting	No	During	TCC
Goel ¹⁴ (2001)	55 M	generalized acute peritonitis	No	During	SCC
Jayathilake ¹⁵ (2002)	72 F	lower abdominal pain	Yes	During	SCC
Shiraishi ¹⁶ (2006)	71 F	bladder irritation, lower abdominal pain	Yes	Before (excretory urography, CT)	SCC
This case	69 M	lower abdominal pain	Yes	During	SCC

SCC: Squamous cell carcinoma, TCC: Transitional cell carcinoma, CT: computed tomography

*Laparotomy revealed macrocarcinoma of the bladder but tumor resection was not performed. Bacon (J Urol 1943;49:432) reported 4 cases of bladder rupture associated with bladder cancer, but no detailed data were described, and thus were omitted from this Table.

Second, the preceding urinary symptoms should be assessed. Symptoms and signs of bladder rupture in the acute phase are those of peritonitis caused by any other disease and are non-specific. Preoperative diagnosis is difficult: preoperative diagnoses were made in only 19 % (4/19); however, previous urinary symptoms were present in 74% (14/19). The present patient had had macrohematuria for 3 months. Abdominal pain occurred after urination. A small rupture and thus a small amount of urine leakage may have occurred

at this time.

Third, neurogenic bladder may have played an additional role in spontaneous rupture, which no previous reports have addressed. Neurogenic bladder was suspected from the previous history of spinal cord injury and distended bladder shown by CT, although no detailed neurological and/or urological examinations had been performed. Neurogenic bladder may cause bladder over-distension and also chronic inflammation, which may have accelerated the bladder rupture. Sensory disturbance, if it was present, may have masked the pain possibly caused by bladder cancer, discouraging an earlier medical checkup, and thus its detection. If these histories and/or symptoms, i.e., hematuria, pain after urination, and signs compatible with neurogenic bladder, had been more carefully assessed, a precise preoperative diagnosis may have been made. Cystography¹³ or CT cystography^{12, 17} may have provided a preoperative diagnosis.

Repair of the bladder and drainage are standard procedures for bladder rupture. The prognoses of bladder cancer patients with bladder rupture may be poor since the disease is highly advanced to the extent that it has induced bladder rupture¹. Taking this into account, minimally invasive treatment based on the correct preoperative diagnosis may be employed. Bladder rupture should be included in the differential diagnosis of a patient with peritonitis, especially with a previous history of urological problems.

CONCLUSION

Physicians must be aware that bladder cancer can lead to bladder rupture, which can cause peritonitis. Previous history of urological problems should be paid attention to.

ACKNOWLEDGEMENTS

We thank Dr. Akifumi Fujita of the Department of Radiology of Jichi Medical University for analyzing the CT images. We also thank the Clinical Research Support Team (CRST) of Jichi Medical University for advice on preparing this manuscript.

References

1. Rasmussen JS. Spontaneous bladder rupture in association with carcinoma. Scand J Urol Nephrol. 1994;28:323-326.
2. Bastable JR, De Jode LR, Warren RP. Spontaneous rupture of the bladder. Br J Urol 1959;31:78-86.
3. Glashan RW. Perforation as a complication of carcinoma of the bladder. Br J Urol 1967;39:178-180.
4. Agapitidis N, Papadopoulos N, Papastamatiou L. A rare case of spontaneous rupture of the urinary bladder. South

Med J 1976;69:244-245.

5. Jenkinson LR. Spontaneous intraperitoneal rupture of the urinary bladder. Postgrad Med J 1981;57:269-270.

6. Powell JM, Williams G. Spontaneous perforation of the bladder in association with malignant disease and schistosomiasis. Br J Urol 1983;55:126-126.

7. Huffman JL, Schraut W, Bagley DH. Atraumatic perforation of bladder. Necessary differential in evaluation of acute condition of abdomen. Urology 1983;22:30-35.

8. Budd JS. Spontaneous intraperitoneal rupture of the bladder in association with transitional cell carcinoma. Postgrad Med J 1988;64:165-166.

9. Wujanto R, Brough R, O'Reilly PH. Spontaneous perforation of squamous cell bladder carcinoma associated with hypercalcaemia. Br J Urol 1989;63:647-648.

10. Sørensen VT, Asklin B, Brunkwall P. Extraperitoneal perforation of the urinary bladder in association with urothelial cancer in a female. Scand J Urol Nephrol 1991;25:277-278.

11. Gough M, McDermott EW, Lyons B, Hederman WP. Perforation of bladder carcinoma presenting as acute

abdomen. Br J Urol 1992;69:541-542.

12. O'Neill GF, Alexander JH. Spontaneous bladder rupture in a patient with widespread superficial transitional cell carcinoma. Aust N Z J Surg 1998;68:79-79.

13. Atalay AC, Karaman MI. Spontaneous rupture of a bladder with invasive bladder carcinoma. Int Urol Nephrol 1998;30:723-724.

14. Goel A, Goel A. Carcinoma urinary bladder presenting as acute abdomen. Int Urol Nephrol 2001;33:491-492.

15. Jayathillake A, Robinson R, Al-Samarri A, Manoharan M. Spontaneous rupture of bladder presenting as peritonitis. N Z Med J 2002;115:U222-222.

16. Shiraishi Y, Moroi S, Negoro H, Iwamura H, Oka H, Kawakita M. Squamous cell carcinoma of the bladder presenting with bladder rupture: a case report (in Japanese with English abstract). Hinyokika Kiyo (Acta Urologica Japonica) 2006;52:139-141.

17. Chan D, Abujudeh H, Cushing G, Novelline R. CT cystography with multiplanar reformation for suspected bladder rupture: experience in 234 cases. AJR Am J Roentgenol 2006;187:1296-1302.

Author Information

Hideyuki Ohzawa

Surgery, Koga Red Cross Hospital

Wataru Arai

Surgery, Koga Red Cross Hospital

Yasuo Kondo

Surgery, Koga Red Cross Hospital

Shin-ichi Endo

Urology, Koga Red Cross Hospital

Tatsuo Morita

Urology, Jichi Medical University

Shigeki Matsubara

Obstetrics and Gynecology, Jichi Medical University