

Lacrimal Cellulitis: An Unusual Complication Of Acute Sinusitis

D Owens, B Olima, R Winter, H Williams

Citation

D Owens, B Olima, R Winter, H Williams. *Lacrimal Cellulitis: An Unusual Complication Of Acute Sinusitis*. The Internet Journal of Otorhinolaryngology. 2006 Volume 6 Number 2.

Abstract

We report the case of an 11 year old girl presenting with acute pan-sinusitis and a rare sequelae, that of lacrimal adenitis. If lacrimal cellulitis is left untreated, abscess formation can occur. Previous case reports have discussed abscess formation and the requirement for surgical drainage. If lacrimal cellulitis is diagnosed early in the disease process by understanding typical signs conservative management can accomplish resolution without the need for surgical exploration and the cosmetic implications of facial surgery.

INTRODUCTION

Lacrimal cellulitis is a rare infection associated with pan-sinusitis, treatment requires antibiotic therapy. It can mimic intra-orbital abscess formation, which requires surgical exploration and must be differentiated from this. With early detection by recognition of early signs indication lacrimal cellulitis, including supero-lateral peri-orbital swelling with infero-lateral globe displacement and investigation revealing diffuse lacrimal gland swelling effective medical management can be instituted without the requirement for surgical exploration surgical intervention can be avoided preventing both the complications of surgery to the orbit and the cosmetic problems associated with facial surgery. Previously lacrimal gland abscess has been described but to our knowledge, this is the first reported case of lacrimal cellulitis secondary to sinus infection treated medically with resolution of symptoms.

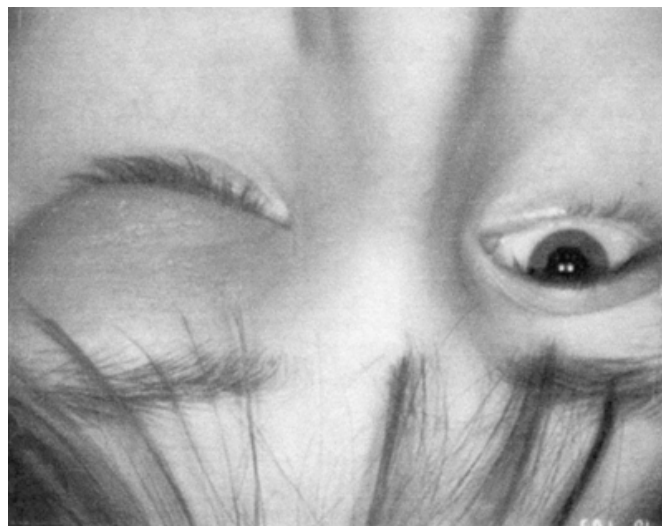CASE HISTORY

An 11-year-old girl attended ophthalmology clinic with a 24-hour history of left sided peri-orbital swelling which had been preceded by 3 days of malaise with associated nausea. An initial diagnosis of facial cellulitis was made and outpatient treatment with oral co-amoxyclav was commenced with a follow-up appointment booked at 1 week to review progress.

24 hours later she returned to hospital with worsening symptoms of increasing pyrexia, confusion, increasing headache and the development of general unsteadiness, she

was also found to be disorientated in time, place and person. Examination revealed grossly oedematous and erythematous left sided periorbital tissue including the eyelid, lateral nose and cheek (FIG 1 “peri-orbital swelling with erythema. Note supero-lateral swelling.”).

Figure 1



No evidence of proptosis or chemosis was noted on examination of the eye and movements were considered normal. Tenderness was elicited on sinus percussion over the left frontal and maxillary sinuses.

Anterior rhinoscopy revealed oedema of the left lateral nasal wall with frank pus visualised tracking from the middle meatus. Further ENT examination at this time was unremarkable. A provisional diagnosis of pre-septal cellulitis

secondary to acute sinusitis was made and treatment with intravenous cefuroxime and metronidazole was commenced.

Blood results on admission revealed a mild neutrophilia with raised CRP.

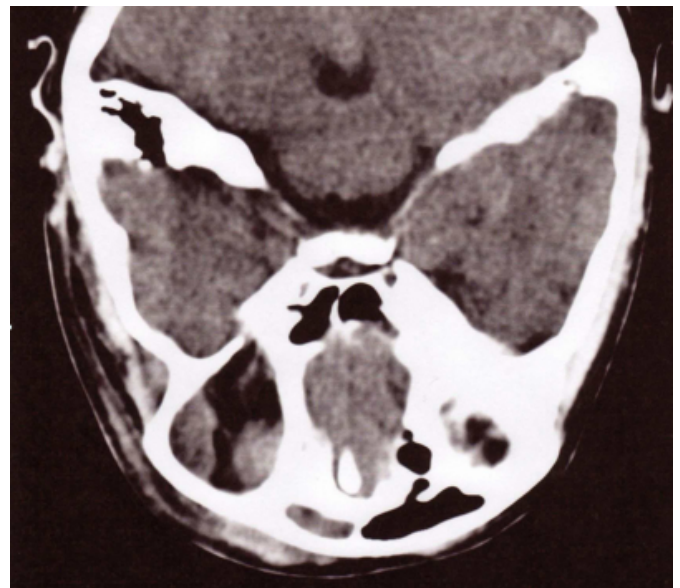
An emergency contrast enhanced computerised tomograph (CT) was performed to exclude intracranial complications as there had been an increase in neurological symptoms. The investigation displayed opacification of the frontal, ethmoid and maxillary sinuses with thickening/cellulitis of the pre-septal tissue of the orbit, suggesting acute sinusitis and preseptal. No evidence of orbital cellulitis or abscess formation within the orbit was seen. No intracranial abnormality was detected. These findings concurred with the diagnosis of pre-septal cellulitis. (FIG 2 "Axial CT of the orbit showing left preseptal cellulitis and opaque left anterior ethmoid cells")

By day 2 of conservative treatment the girl symptoms had changed, proptosis was now evident and the globe appeared to be displaced infero-medially with diplopia on right lateral gaze. Eye movements were restricted but no evidence of chemosis or loss of visual acuity was noted. The possibility that the disease had progressed to orbital cellulitis/ abscess was considered. The possibility of intra-orbital collection was considered and a further CT scan was organised to confirm or refute this assumption prior to surgical exploration. The investigation revealed reduction in the volume of pre-septal tissue an improvement with no obvious post-septal extension. There was however noted to be defined area of inflammation in the upper lateral quadrant of the orbit, which was considered to be a cellulitis of the lacrimal gland, no collection was noted. (FIG 3 "Axial CT showing resolving peri-orbital/frontal swelling and diffuse enlargement of the lacrimal gland consistent with cellulitis.").

Figure 2

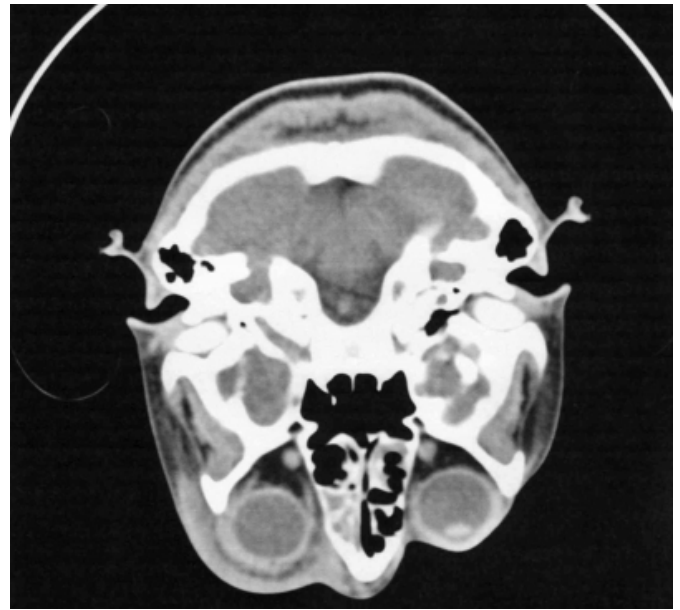

Figure 3



The diagnosis of improving pre-septal cellulitis with associated lacrimal adenitis was made and discussion about appropriate management was undertaken.

An interdisciplinary meeting involving ENT, ophthalmology and microbiology was undertaken and the decision to continue with conservative management or surgical intervention was discussed. Conservative treatment was continued with the addition of intravenous clarythromycin as suggested by microbiology. Within 24 hours reduction in peri-orbital swelling had occurred with general improvement in orbital and sinogenic symptoms. After 48hours of

intravenous therapy oral treatment was commenced and continued for 2 weeks.

On review at 4 weeks total resolution of symptoms and signs had occurred and the girl was discharged from clinic.

DISCUSSION

Infectious disease of the lacrimal gland is rare (¹) and tends to develop by local transmission from skin (cellulitis) and eye (conjunctivitis) (^{2,3}). Haematogenous spread has been described with systemic illnesses such as mumps and also with gonorrhoea, typhoid and pneumonia (⁴). The most common pathogens responsible for lacrimal gland infections are gram-positive bacterium including *Haemophilus influenza*, *Staphylococcus aureus* and *Streptococcus pneumoniae* and *Branhamella catarrhalis*. These infections have little resistance to co-amoxyclav or to third generation cephalosporins (⁵).

In this case, the lacrimal adenitis is likely to have been either a complication of the sinusitis or due to obstruction of lacrimal gland drainage due to peri-orbital swelling. Although transmission via the sinuses is unusual without orbital infection vascular transmission via thepian vessels within the skull base is a possibility and may account for some of the neurological symptoms noted on initial examination.

Without adequate treatment cellulitis of the lacrimal gland deteriorates with abscess formation and the necessity for surgical drainage.

As with pre-septal cellulitis first-line treatment is 24 hours of intravenous antibiotics providing no evidence of post-septal infection is present. If improvement does not occur scanning with computerised tomography is indicated to exclude worsening infection and abscess formation which without surgical intervention has serious complications including loss of sight, intracranial infection and cavernous sinus thrombosis (⁶).

References

1. McCabe A.A. Lacrimal gland abscess: two case reports. *Aust. N.Z. J. Ophthalmol.* (1999) 27:75-78
2. Chandler J.R, Langenbrunner D .J, Stevens E. R. The Pathogenesis of orbital complications in acute sinusitis. *J. Laryngoscope* (1970) 80:1414-1428
3. Harris G.J, Synder R.W. Lacrimal gland abscess, *Am. J. Ophtalmol.* 1987 104 (2): 193-194
4. Mizra S, Lobo C, Counter P, Farrington W.T. Lacrimal gland abscess: an unusual complication of Rhinosinusitis, *ORL J.Otolaryngol* (2001) 63: 379-381
5. Healy G, B. Comment on Chandler et al. The Pathogenesis of orbital complications in acute sinusitis, *Laryngoscope* 1997 107: 411-6
6. Goodwin W.J, Weinshall M, Chandler J.R. The role of high resolution computerized tomography and standardized ultrasound in the evaluation of orbital cellulitis, *Laryngoscope* (1982) 92:728-731

Author Information

David Owens, MRCS

Department of Otolaryngology, Royal Glamorgan Hospital

Bellice Olima, MRCS

Department of Otolaryngology, Royal Glamorgan Hospital

Richard Winter, FRCR

Department of Otolaryngology, Royal Glamorgan Hospital

Huw Williams, FRCS

Department of Otolaryngology, Royal Glamorgan Hospital