

Pattern of Ocular Malignant Tumors in Bhairahwa, Nepal

R Kumar, R Adhikari, M Sharma, D Pokharel, N Gautam

Citation

R Kumar, R Adhikari, M Sharma, D Pokharel, N Gautam. *Pattern of Ocular Malignant Tumors in Bhairahwa, Nepal*. The Internet Journal of Ophthalmology and Visual Science. 2008 Volume 7 Number 1.

Abstract

The pattern of ocular malignant tumors in institutes of western Nepal was analyzed by a retrospective study of 277 ocular cases from 2000 to 2007 carried out through clinical examinations and histopathological confirmations. The cases other than ocular malignancy were excluded. A total of 59 ocular malignant tumors were encountered. Male and female cases were 45.8% and 54.2% respectively. Squamous cell carcinoma was diagnosed as the most common (66.1%), followed by basal cell carcinoma (10.2%), meibomian gland carcinoma (10.2%), retinoblastoma (7%), malignant melanoma (5.1%) and 1.7% lacrimal gland adenocarcinoma. Squamous cell carcinoma was found to be the most common tumor (65%) among the elderly persons (>40 years of age) with females presenting at relatively earlier average age to males. Among the cases below 15 years of age, retinoblastoma was the commonest tumor (57%) followed by squamous cell carcinoma (43%).

INTRODUCTION

Various tissues of visual system contribute to lesions from inflammation to different types of neoplastic conditions. Ocular malignant tumors are relatively rare compared to other eye lesions, require immediate diagnosis and management. But ignorant care due to unawareness of persons can result into debility, loss of vision, and occasionally life is jeopardized. Malignant tumors of eyelid, conjunctiva, retina and orbit in both adults and children have been reported¹. However, there exists a variation in pattern and frequency on the basis of geographical locations^{2,3,4,5}. Retinoblastoma in children and basal cell carcinoma in adults were the commonest findings in a study conducted in eastern Nepal². Many patients visit the Lumbini Eye Institute, and Universal College of Medical Sciences Teaching Hospital (UCMSTH), Bhairahwa, Nepal, for their treatment of ocular complaints. However, ocular malignant tumors have not been reported so far from this part of Nepal. During literature survey, we found only one such report from this country. Hence, we designed a retrospective study to analyze the above on the basis of histopathological diagnosis by retrieving the hospital based data of the patients.

MATERIALS & METHODS

The patients with ocular complaints consulted the ophthalmologist at hospitals where all history taking, clinical examination, investigations and surgical interventions were done. The biopsy specimens of eye and adnexa were

submitted to the Pathology Laboratory of UCMSTH from 2000 to 2007. The specimens were fixed, processed and stained with hematoxylin & eosin, and special stains were used as and when required. The diagnosis was confirmed with the help of light microscope. There were altogether 277 ocular cases registered in the Department of Pathology, the slides of which were reviewed with the help of hospital data and malignant cases were selected. All other cases including benign neoplasm, tumor-like lesions and inflammatory conditions, on the basis of history, clinical examination and histology findings, were excluded during study. Malignant tumors of various histological types were included for the study and these cases were analyzed on the basis of gender, age group, and location of lesion, and thereafter results designed in the form of tables, figures and text seen over a period of 8 years.

RESULTS

In this retrospective study of 277 cases, 59 were diagnosed of malignant tumor (21.3%) with 27 males (45.8%) and 32 females (54.2%), (Table-1).

Figure 1

Table 1: Showing age group and sex of the malignant cases

Age group	Male	Female	Total
0-10	3	1	4
11-20	1	5	6
21-30	1	2	3
31-40	2	4	6
41-50	4	6	10
51-60	7	8	15
61-70	7	3	10
71-80	2	2	4
81-90	0	1	1
Total	27	32	59

There was a bimodal age distribution with one peak in younger age group at about 15 years and another at about 55 years in the age group of 41-70 years, (Figure-1).

Figure 2

Figure 1: Showing distribution of cases in different age group

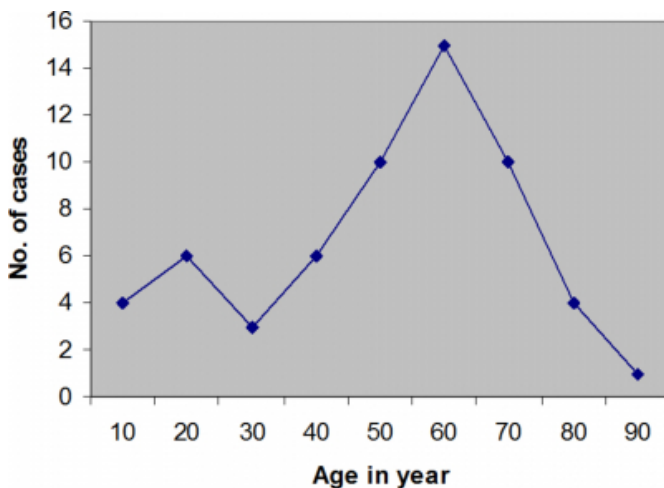
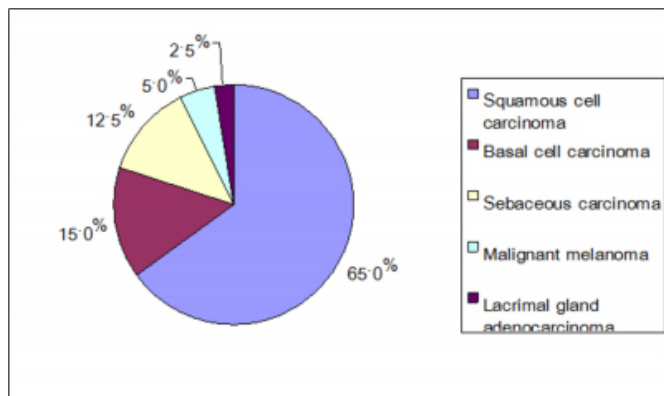


Figure 3

Figure 2: Showing pattern of malignancy in cases above 40 years of age.



The average age of presentation was 47 years. There were 27

left eyes/adnexae (45.8%) and 32 right eyes/adnexae (54.2%) involvements. None of the case had bilateral involvement. The locations of lesion and detection of malignancy are presented in Table-2.

Figure 4

Table 2: Showing malignant neoplasm by subsites

Sites	No. of cases	% of cases
Conjunctiva		
Squamous cell carcinoma	29	96.7
Malignant melanoma	1	3.3
Total	30	100
Cornea		
Squamous cell carcinoma	2	100
Total	2	100
Eyelid		
Squamous cell carcinoma	8	38.1
Sebaceous carcinoma	6	28.6
Basal cell carcinoma	6	28.6
Malignant melanoma	1	4.7
Total	21	100
Retina		
Retinoblastoma	4	100
Total	4	100
Choroid		
Malignant melanoma	1	100
Total	1	100
Lacrimal gland tissue		
Lacrimal gland adenocarcinoma	1	100
Total	1	100

The pattern of malignant neoplasm is shown in Table 3.

Figure 5

Table 3: Showing pattern of malignant tumors in the study

Malignant neoplasm	No. of cases	% of cases
Squamous cell carcinoma	39	66.1
Basal cell carcinoma	6	10.2
Sebaceous carcinoma	6	10.2
Retinoblastoma	4	6.7
Malignant melanoma	3	5.1
Lacrimal gland adenocarcinoma	1	1.7
Total	59	100

The diagnosis of squamous cell carcinoma was the most common (66.1%), involving 19 males (48.7%) and 20 females (51.3%). There were 26 cases (66.7%) above 40 years of age and 13 cases (33.3%) below it including 3 cases of lower than 15 years. M/F ratio was 1:1. The average age of presentation (48 years) for males was 55 years and 41 years for females. It was affecting conjunctiva in 29 cases (74%), cornea in 2 cases (5%) and eyelids were involved in 8 cases (21%). Poorly differentiated type was detected in 5 cases involving conjunctiva (2), cornea (1) and eyelids (2).

Basal cell carcinoma was affecting 6 cases of one male

(16.7%) and 5 females (83.3%) with M/F ratio of 1: 5. All the 6 cases were involving above 40 years of age. The average age of presentation was 62 years. Lower eyelid was affected in 4 cases (66.7%), and upper eyelid in 2 cases (33.3%). It includes one case of basosquamous carcinoma with ulcerative lesion.

The Sebaceous carcinoma was affecting 6 cases with equal gender involvement. There were 5 cases of above 40 years, and one case of 35 years. The average age of presentation was 52 years. Upper eyelids were affected in 4 cases including one had ulcerative nodule for 1^{1/2} years. One case was involving lower eyelid and another one to lateral canthus.

There were total 4 cases of retinoblastoma affecting 3 males and one female. Of these 3 cases were of less than or 5 years and one case of 10 years male. Eyeballs were enucleated in all the cases. None of the case had bilateral or optic nerve involvement.

Malignant melanoma was affecting 3 cases of one male and 2 female. There were 2 cases of above 40 years of age and one case was of 28 years. The average age of presentation was 47 years. Each one case of conjunctiva, upper eyelid and choroid were affected. In one case enucleation was done.

In this study, there was only one case of lacrimal gland adenocarcinoma. It was involving upper eyelid of a 70 years female.

In cases older than 15 years of age squamous cell carcinoma was found to be the commonest tumor (69.2%), followed by basal cell carcinoma (11.5%), sebaceous carcinoma (11.5%), malignant melanoma (5%) and lacrimal gland adenocarcinoma (2.5%). Among the cases below 15 years, retinoblastoma was the most common (57%) followed by squamous cell carcinoma (43%) (Table 4).

Figure 6

Table 4: Showing malignant neoplasm in different age groups

Malignant neoplasm	No. of cases	% of cases
Involving >15 years		
Squamous cell carcinoma	36	69.2
Basal cell carcinoma	6	11.5
Sebaceous carcinoma	6	11.5
Malignant melanoma	3	5.8
Lacrimal gland adenocarcinoma	1	1.9
Total	52	100
Involving <15 years		
Retinoblastoma	4	57.1
squamous cell carcinoma	3	42.9
Total	7	100

The present study has the high specificity of histological biopsy test of 98.93% for non-malignant cases and sensitivity of 64.04% for malignant cases. Calculated χ^2 test with Yate's correction is more than the theoretical value of χ^2 0.0001 at 1 degree of freedom (Table 5).

Figure 7

Table 5: Calculation of sensitivity and specificity of malignancy in the study (2x2 Contingency Table)

Cases	No. of patients with +ve test result	No. of patients with -ve test result	Totals
No. of patients with malignancy	57	32	89
No. of patients without malignancy	2	186	188
Totals	59	218	277
Sensitivity (TP/TP+FN) = 57/89 = 64.04%			
Specificity (TN/FP+TN) = 186/188 = 98.93%			
Significant dependence (χ^2 , p<0.0001) of biopsy performance			

Hence it shows significant dependence (χ^2 , p<0.0001) of histological biopsy performance with respect to the diagnosis of malignancy

DISCUSSION

The present work revealed 45.8% males and 54.2% females. This was similar to the findings of 48.8% and 51.2% respectively in eastern Nepal and closer to 53.6% and 46.4% respectively in Singapore²⁴. The study expressed bimodal age distribution with one peak around 15 years and another around 55 years similar to other reports⁴⁶⁷⁸.

The most common malignancy in this study was squamous cell carcinoma (66.1%), supported by a study in Sudan which showed it as the commonest tumor with 50.4% cases⁹. Poso M.Y. et al also reported it as the commonest tumor in their study with 33.5% cases¹⁰. In the present study it was affecting conjunctiva most commonly (74.3%) and cornea (5.1%). Among the tumors of conjunctiva and cornea, Sunderraj revealed 55.1% in his study⁶. Other scientists also reported conjunctiva as the commonest site⁸⁹. In our series, out of 21 eyelid involvement, 8 were of squamous cell

carcinoma (38.1%). Sunderraj reported 34% whereas other authors observed 22.4% and 22.2% respectively among eyelid tumors in neighboring India⁶¹¹². Ultraviolet spectrum could be a factor for high incidence of this tumor, as large no. of persons work in the open sun, especially farmers and workers are exposed to it.

Basal cell carcinoma was by far most frequent neoplasm arising from cutaneous surface of eyelids involving 10.2% all above 40 years with average age of 62 years in our study. Reports from Sudan and Papua New Guinea revealed 6.1%, and 9.1% respectively with average age of 54 years⁹¹³. In our study, it was involving 4 lower and 2 upper eyelids out of total 21 eyelid cases (28.6%) including one case affecting medial canthus and another one to conjunctiva also. It was reported 33.3% and 37.6% respectively among eyelid tumors in some of the studies¹²¹⁴. In our series, lower eyelids were affected in 66.7% cases. It was reported 55% involvement in a study¹.

Sebaceous carcinoma was observed 1.7% and 31.7% respectively in studies in Papua New Guinea and Shanghai (China)¹³¹⁴. It was reported 12.1% of all ocular malignant tumors in a study in Korea, similar to our result of 10.2%¹⁵. This variation may account for the geographical factors in the study involved. Out of 21 eyelid cases in our study, 6 were affected by this carcinoma (28.6%). Studies in Korea and India found 21.2% and 33% respectively⁶¹⁵. However, according to Kass et al, it accounts for 1-5.5% of all eyelid malignancies in the USA¹⁶.

Retinoblastoma in our series revealed 6.7%. It varies greatly from some reports of 32%, and 31.7%⁶¹⁰. Other studies reported 20.8% & 19.8% respectively⁹¹⁷. It may be due to less number of cases in our study as enucleation started recently in the institutes. Retinoblastoma cases in our study were 75% in or below 5 years which was similar to the findings in Nepal who found 88.2% cases². Marshall observed it as the most common ocular malignancy in children⁸.

Malignant melanoma was reported 4.6% and 4.5% respectively in the studies⁹¹³. There was 5.1% melanoma in the present study including a case affecting eyeball so much, that enucleation was to be done. The study conducted in Eastern Nepal and Nigeria reported 9.5% and 7.7% respectively of all ocular malignancies²⁵.

The lacrimal gland carcinoma was found to be 1.7% in this series, similar to the findings of Sunderraj and Verma et al

who found least number of 3% and 3.4% cases respectively in their studies⁶¹³.

This retrospective study of malignant tumors of eye and adnexa has shown squamous cell carcinoma as the most common tumor (65%) with females presenting relatively at earlier average age (of 41 years) to males (55 years), followed by basal cell carcinoma (15%), and sebaceous carcinoma (12.5%) involving cases older than 40 years (Figure 2).

It will help ophthalmologist in shaping the strategy for diagnosis and management of malignant neoplasm in this region and compare from other parts of the globe...

ACKNOWLEDGMENTS

Authors are thankful to the Directors of the Universal College of Medical Sciences & Teaching Hospital, and Lumbini Eye Institute, Bhairahwa, Nepal for proper guidance, and their laboratory staff for co-operation in analyzing the data.

CORRESPONDENCE TO

Dr Rajendra Kumar, Department of Pathology, Universal College of Medical Sciences, Paklihawa Campus, P.O. Box 53, Bhairahwa, Nepal Phone No.: +977-71-522896(Office), 526384(Residence) Fax No.: +977-71-522921 Email: neerurkumar@rediffmail.com

References

1. Gunduz K, Esmali B. Diagnosis and management of malignant tumors of the eyelid, conjunctiva, and orbit. *Expert Rev Ophthalmol*. 2008; 3: 63-75.
2. Thakur SK, Sah SP, Lakhey M, Badhu BP. Clinical research. Primary malignant tumours of eye and adnexa in Eastern Nepal. *Clinical & Experimental Ophthalmology* 2003; 31: 415-417.
3. Cheng CY, Hsu WM. Incidence of eye cancer in Taiwan: an 18-year review. *Eye*. 2004; 18: 152-158.
4. Lee SB, Au Eong KG, Saw SM, Chan TK, Lee HP. Eye cancer incidence in Singapore. *Br J Ophthalmol*. 2000; 84: 767-770.
5. Askira BH, Nggada HA. Orbito-ocular malignancies in Maiduguri, North Eastern Nigeria: a histopathologic review. *The Internet Journal of Ophthalmology and Visual Science*. 2007; 5: Number1.
6. Sunderraj P. Malignant tumours of the eye and adnexa. *Indian J Ophthalmol*. 1991; 39: 6-8.
7. Ud-Din N, Mushtaq S, Mamoon N, Khan AH, Malik IA. Morphological spectrum of ophthalmic tumors in northern Pakistan. *J Pak Med Assoc*. 2001; 51: 19-22.
8. Marshall EC. Epidemiology of tumors affecting the visual system. *Optom Clin*. 1993; 3: 1-16.
9. Malik MO, El Sheikh EH. Tumors of the eye and adnexa in the Sudan. *Cancer*. 1979; 44: 293-303.
10. Poso MY, Mwanza JC, Kayembe DL. Malignant tumors of the eye and adnexa in Congo-Kinshasa. *J Fr Ophthalmol*. 2000; 23: 327-332.

11. Abdi U, Tyagi N, Maheshwari V, Gogi R, Tyagi SP. Tumours of eyelid: a clinicopathologic study. *J Indian Med Assoc.* 1996; 94: 205-209.
12. Banait PP, Patoria NK, Sharma KD. Primary tumours of eye-lid. *Indian J Ophthalmol* 1973; 21: 200-203.
13. Verma N, Murthy DP, Kerek A. Orbital malignancy in Papua New Guinea: A 21 year review. *Australian and New Zealand Journal of Ophthalmology.* 1999; 27: 27-31.
14. Ni Z. Histopathological classification of 3,510 cases with eyelid tumor. *Zhonghua Yan Ke Za Zhi.* 1996; 32: 435-437.
15. Roh KK, Lee JH, Youn DH. Clinical analysis of tumors of the eye and its adnexa. *Kor. J. Ophthalmol.* 1998; 2: 27-31.
16. Kass LG, Hornblass A. Sebaceous carcinoma of the ocular adnexa. *Surv Ophthalmol.* 1989; 33: 477-490.
17. Scat Y, Liotet S, Carre F. Epidemiological study of 1705 malignant tumors of the eye and adnexa. *J Fr Ophthalmol.* 1996; 19: 83-88.

Author Information

Rajendra Kumar, MD

Department of Pathology, Universal College of Medical Sciences and Teaching Hospital

Rishi K. Adhikari, MS

Department of Oculoplasty, Lumbini Eye Institute

Manoj K. Sharma, MD

Department of Cornea & Ocular Surface, Lumbini Eye Institute

Daya R. Pokharel, PhD

Department of Biochemistry, Universal College of Medical Sciences and Teaching Hospital

Narayan Gautam, MSc

Department of Biochemistry, Universal College of Medical Sciences and Teaching Hospital