

Neglected peritalar dislocation

S Tak, G Dar, M Halwai, M Mir

Citation

S Tak, G Dar, M Halwai, M Mir. *Neglected peritalar dislocation*. The Internet Journal of Orthopedic Surgery. 2007 Volume 10 Number 2.

Abstract

We present a case of neglected peritalar dislocation, 8 weeks old in a young male treated by open reduction and pin fixation. Patient was followed for 2 years and at the end of 2 years patient had good functional result.

INTRODUCTION

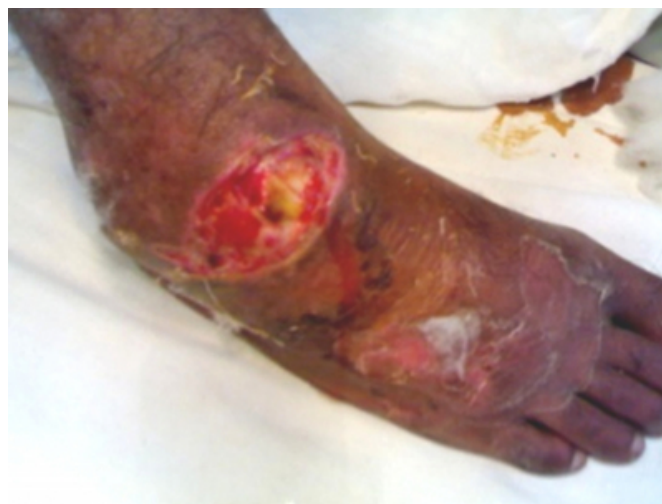The peritalar dislocation is a rare injury (^{1,2,3,4,5,6}). It consists of the simultaneous displacement of talocalcaneal (subtalar) and talonavicular joints, with no associated fracture at the talar neck or body, and without any compromise of talocrural (ankle) and calcaneocuboid joints (^{6,7,8,9,10,11,12}). Peritalar dislocation represents around 1% to 2% of all traumatic dislocations (¹³) and 15% of all talar injuries (^{2,6,7,8,14}). Most affected patients are young and male at the third decade of life (^{8,15}). 50% to 80% of peritalar dislocations are caused by a violent trauma resulting from motorcycle or car accidents or from a fall from height. Some injuries are caused by a torsional trauma associated to sports activities, and are called "basketball foot" (^{6,8,15}). Medial peritalar dislocations represent 80% cases, four-fold more often than lateral dislocations (17%) (^{4,9,17,18}). Lateral dislocations usually occur due to trauma with higher energy and more than 50% of these lesions are open (¹⁹). There is a lower frequency of posterior and anterior dislocations, representing 2.5% and 1% of all cases, respectively (¹⁸). Immediate reduction is important to avoid skin necrosis and peripheral vascular compression (^{7,8,11,12,16}). Closed reduction is possible in most peritalar dislocations (^{1,7,22}); however, in around 10% to 20% of cases, open reduction becomes necessary due to soft tissue interposition or due to severe swelling created by the diagnostic delay (^{7,11,12,13,21}).

CASE REPORT

A 30 year old male presented with neglected medial peritalar dislocation of right ankle, 8 weeks old with sloughing of skin over the talar head. (Fig.1)

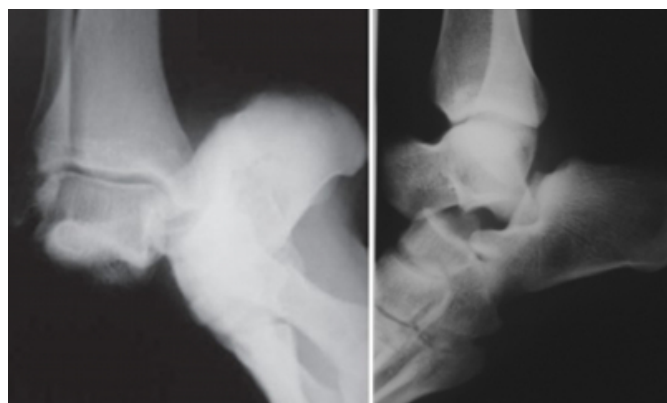
Figure 1

Figure 1: Neglected peritalar dislocation of right ankle with sloughing of skin.



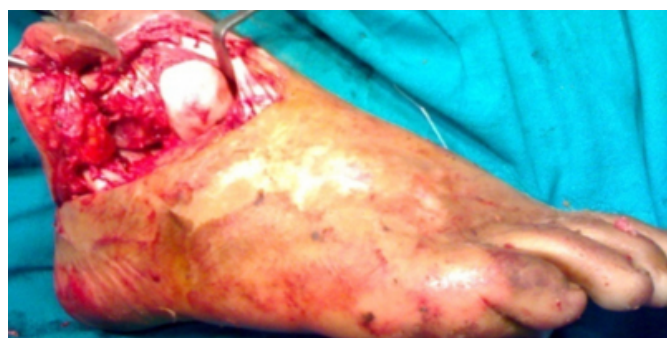The distal neuro-vascular status was intact. Patient had injured his ankle, when he met an accident while riding a bike. Following accident patient developed swelling and deformity of his ankle. Instead of seeking medical help, the patient felt pray to quackery as such diagnosis and treatment was delayed for more than 8 weeks. Radiographs revealed medial peritalar dislocation (Fig 2a-b). Fig. 2a and 2b AP and Lateral Radiodiographs Showing medial peritalar dislocation.

Figure 2



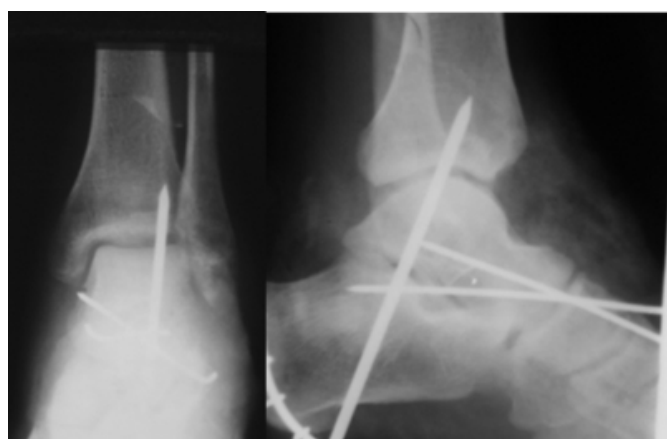Debridement of wound and open reduction was performed under spinal anesthesia. Fig 3.

Figure 3



The reduction was not stable and was maintained with tibio-calcaneal and talo-navicular pins. Fig 4. Post operative AP and Lateral radiograph.

Figure 4

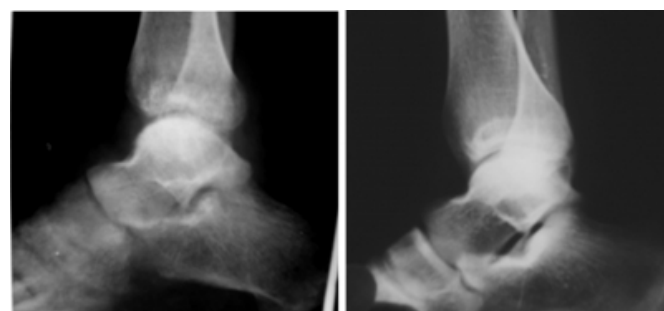


Post operatively limb was immobilized in a below knee POP cast with a window. Pins and plaster were removed at 6 weeks when partial weight bearing was allowed. Weight bearing was progressed over next 4 weeks when patient was

able to bear full weight and without any limp. Patient was followed for 2 years and at the end of 2 years patient was pain free walked normally. However the motion of subtalar joint was restricted. Radiograph of ankle revealed normal vascularity of talus, slight decrease in subtalar space. Fig.5

Figure 5

Figure 5: Lateral radiographs Of both ankle joints for comparison.



DISCUSSION

Literature is replete with case reports of peritalar dislocations; however there is no report of any neglected case as to our knowledge. We present the management and outcome of a neglected medial peritalar dislocation more than 8 weeks old initially mismanaged by a quack. Peritalar dislocation is a rare lesion, caused by a torsional mechanism that usually involves high-energy (^{2,5,7,8,15}). It mainly affects male subjects at the economically-active age (^{8,11,15}). Medial peritalar dislocations are most common (^{4,9,18}). Lateral, posterior and Anterior dislocations occur less often. 50% to 70% of cases have associated fractures (¹). Most fractures affect talonavicular and subtalar joint surfaces, producing small osteochondral or cartilaginous fragments that may eventually go unnoticed on pre- or post reduction simple X-rays. Those hidden fractures occur in all lateral and posterior dislocations, and in around 12% to 38% of medial dislocations (^{1,18, ^{26, 27, 28, 29}}). Early diagnosis, anatomical reduction, stable fixation of peritalar joint fractures, and the resection of small, free osteochondral fragments are decisive factors for the prevention of early posttraumatic arthrosis which, in turn, may cause pain, joint stiffness, and an unsatisfactory final result (¹).

As a treatment form of peritalar dislocation, immediate reduction is important to avoid skin ischemia around the bony prominence and the consequent skin necrosis, besides neurovascular bundle compression. Treatment delay renders the reduction of dislocation difficult, due to capsuloligamentous retraction (^{7,8,11,12,16}). Peritalar dislocations usually can be treated with closed reduction

under intravenous sedation or general anesthesia (^{1,7,17,22}). Open reduction may be needed in around 10% to 20% of cases due to difficulties in performing closed reduction, or when joint incongruity is seen after close reduction (^{2,7,12,13,21,23,29}). Joint stability, after reduction of open peritalar dislocations, occurs in approximately 50% of cases (⁸). The presence of instability warranted the transient fixation of subtalar, talo-navicular, or calcaneocuboid joints fixation with Kirschner wires. The cause of instability was probably due to higher grade of soft tissue injury or associated intraarticular fractures. In open, peritalar dislocations, instability should be treated with open reduction and transarticular wire fixation to retain the reduction¹⁷. Talar avascular necrosis is rare after peritalar dislocation (^{24, 26, 27}). It usually occurs as a consequence of severe dislocations due to high-energy trauma, with important compromise of soft tissues and higher grade of talar devascularization (^{15,21, 29}). Necrosis may occasionally occur in closed injuries. Degenerative signs are frequent on radiographic analysis after peritalar dislocation, although, in most cases, painful symptoms are uncommon (^{1, 22,23}).

References

1. DeLee JC, Curtis R. Subtalar dislocation of the foot. *J Bone Joint Surg Am.* 1982; 64(3):433-7.
2. Meinhard BP, Girgis I, Moriarty RV. Irreducible talar dislocation with entrapment by the tibialis posterior and the flexor digitorum longus tendons. A case report. *Clin Orthop Relat Res.* 1993; (286):222-4.
3. Chen YJ, Liang SC, Huang TJ, Hsu KY, Hsu RW. Fragment of entire posterior talar process as an obstacle to reduction of an anterior talar subluxation: case report. *J Trauma.* 1997;42 (2):314-7.
4. Leitner B. Obstacles to reduction in subtalar dislocations. *J Bone Joint Surg Am.* 1954;36 (A:2):299-306.
5. Hiraizumi Y, Hara T, Takahashi M, Mayehiyo S. Open total dislocation of the talus with extrusion (missing talus): report of two cases. *Foot Ankle int.* 1992; 13(8) : 473-7.
6. Tucker DJ, Burian G, Boylan JP. Lateral subtalar dislocation: review of the literature and case presentation. *J Foot Ankle Surg.* 1998;37(3):239-47;
7. Dimentberg R, Rosman M. Peritalar dislocations in children. *J Pediatr Orthop.* 1993;13(1):89-93.
8. DeLee, J. "Fractures and dislocations of the foot" In: Coughlin MJ, Mann RA. *Surgery of the foot and ankle.* 6th ed. St. Louis: Mosby Year Book; 1993. pp. 1465-1597.
9. Bohay DR, Manoli A 2nd. Occult fractures following subtalar joint injuries. *Foot Ankle Int.* 1996;17(3):164-9. Review.
10. Chen YJ, Hsu RW, Shih HN, Huang TJ. Fracture of the entire posterior process of talus associated with subtalar dislocation: a case report. *Foot Ankle Int.* 1996;17(4):226-9.
11. Kinik H, Oktay O, Arıkan M, Mergen E. Medial subtalar dislocation. *Int Orthop.* 1999;23(6):366-7.
12. Heck BE, Ebraheim NA, Jackson WT. Anatomical considerations of irreducible medial subtalar dislocation. *Foot Ankle Int.* 1996;17(2):103-6.
13. Pennal GF. Fractures of the talus. *Clin Orthop Relat Res* 1963;30:53-63.
14. Ruiz Valdivieso T, de Miguel Vielba JA, Hernandez Garcia C, Castrillo AV, Alvarez Posadas JJ, Sanchez Martin MM. Subtalar dislocation. A study of nineteen cases. *Int Orthop.* 1996;20(2):83-6.
15. Inokuchi S, Hashimoto T, Usami N. Posterior subtalar dislocation. *J Trauma.* 1997;42(2):310-3.
16. Bohay DR, Manoli A 2nd. Subtalar joint dislocations. *Foot Ankle Int.* 1995;16(12):803-8.
17. Zimmer TJ, Johnson KA. Subtalar dislocations. *Clin Orthop Relat Res.* 1989;(238):190-4.
18. Monson ST, Ryan JR. Subtalar dislocation. *J Bone Joint Surg Am.* 1981; 23.
19. Toohey JS, Worsing RA Jr. A long-term follow-up study of tibiotalar 63(7):1156-8. dislocations without associated fractures. *Clin Orthop Relat Res.* 1989;
20. Barber JR, Bricker JD, Haliburton RA. Peritalar dislocation of the foot. (239):207-10. *Can J Surg.* 1961;4:205-10.
21. Ebraheim NA, Skie MC, Podeszwa DA. Medial subtalar dislocation associated with fracture of the posterior process of the talus. A case report. *Clin Orthop Relat Res.* 1994;(303):226-30.
22. M. Clinical rating systems for the ankle-hindfoot, midfoot, hallux, and lesser toes. *Foot Ankle Int.* 1994;15(7):349-53.
23. Craig FS, McLaughlin HL. Injuries of the foot. In: falta autor do livro. *Acta Orthop Scand.* 1977;48(6):707-11.
24. Merchan EC. Subtalar dislocations: long-term follow-up of 39 cases. *Injury.* 1992;23(2):97-100.

Author Information

Shafaat Rashid Tak, M.S. Orthopaedics

Registrar, Department of Orthopaedics, Government Medical College Srinagar, University of Kashmir

G.N. Dar, M.S. Orthopaedics

Registrar, Department of Orthopaedics, Government Medical College Srinagar, University of Kashmir

M.A. Halwai, M.S. Orthopaedics

Department of Orthopaedics, Government Medical College Srinagar, University of Kashmir

M. Ramzan Mir, M.S. Orthopaedics

Professor and Head of the Department, Department of Orthopaedics, Government Medical College Srinagar, University of Kashmir