

Unexpected Complications After Excision Of Splenic Aneurysm In Osler-Weber-Rendu Disease

M Delvi, S Khan-Ghori, M Al-Salman, M Takroui

Citation

M Delvi, S Khan-Ghori, M Al-Salman, M Takroui. *Unexpected Complications After Excision Of Splenic Aneurysm In Osler-Weber-Rendu Disease*. The Internet Journal of Anesthesiology. 2002 Volume 7 Number 2.

Abstract

Osler-Weber-Rendu disease is an autosomal dominant disease, sometimes known as hereditary hemorrhagic telangiectasia (HHT) with a family history. It is a rare disease and there are no records of families with inheritance lineage in Riyadh. We experienced anesthetic management of a 28-yr-old woman with Osler-Weber-Rendu disease. She was diagnosed to have splenic aneurysm and was scheduled for the repair of the aneurysms. A chest X-ray revealed pulmonary arterio-venous malformation all over the lungs. The anesthesia and surgery went deliberately smoothly with selective period of intensive care admission. In the intermediate post operative period she was diagnosed as having pleural effusion and chest drain was inserted as emergency, but the patient developed tension pneumothorax, which necessitated resuscitation and readmission to intensive care unit. Reconsideration to the initial diagnosis went in the direction of lung atelectasis. On the ground of low experience of the surgical night staff and lack of communication there are good lesson to be considered namely vigilance not to be reduced, communication, and consultation are as important as the properly conducted management of such rare cases.

INTRODUCTION

Osler-Weber-Rendu disease is a hereditary disorder of autosomal dominant type characterized by cutaneo-mucous telangiectasia and vascular abnormalities (arterio-venous malformations and aneurysms) in several organs. These is due to mutations of endoglin gene ENG or ALK1 [1]

This is a report on a case of Osler-Weber-Rendu (OWR) disease which was presented for excision of splenic artery aneurysm. There was an unexpected post-operative course, which ended with good outcome. The treatment is primarily supportive including iron supplement and blood transfusions. Septal dermatoplasty and oral oestrogens may allow prolonged remission from epistaxis. Legation resection and immobilization may be indicated for pulmonary AVMs. Patients may present with aneurysms in any of the major blood vessels or organs for excision. [1,2]

The purpose of this report is alerting anesthesiologists to some problems in managing these patients, when they undergo surgical, diagnostic or therapeutic procedures. Review of anesthesia literature yielded only one report on handling a case under anesthesia for brain abscess [3]

CASE REPORT

A 28-year-old female patient was admitted to King Khalid

University Hospital with complaints of shortness of breath, haemoptysis and epistaxis for a period of 4 months. She gave a history of pleuritic type of chest pain, loss of appetite and weight loss. She had a number of previous admissions to the hospital due to similar complaints, which was treated symptomatically, and she was diagnosed as an asthmatic. A detailed history elicited repeated episodes of epistaxis, haemoptysis and bleeding per rectum. On examination she was comfortable at rest with clubbing of fingers and prominent veins in her upper extremities. Chest examination revealed reduced bilateral air entry with no added sounds, rhonchi or wheeze. Examination of other systems was unremarkable.

LABORATORY INVESTIGATIONS:

Routine laboratory investigations were within normal limits except for a picture of anemia (Hb 8.9 gm%). Arterial Blood Gases on room air showed a PaO₂ of 60 mm Hg and PCO₂ of 33 mmHg.

CHEST X-RAY:

Plan X- ray chest was showing bilateral round and oval irregular in size opacities all over the lung fields. The provisional x-ray diagnosis was either Koch's disease or secondary metastasis. (Fig. 1)

Figure 1

Figure 1a: PA view plain X- ray chest of the patient with Osler-Weber-Rendu disease

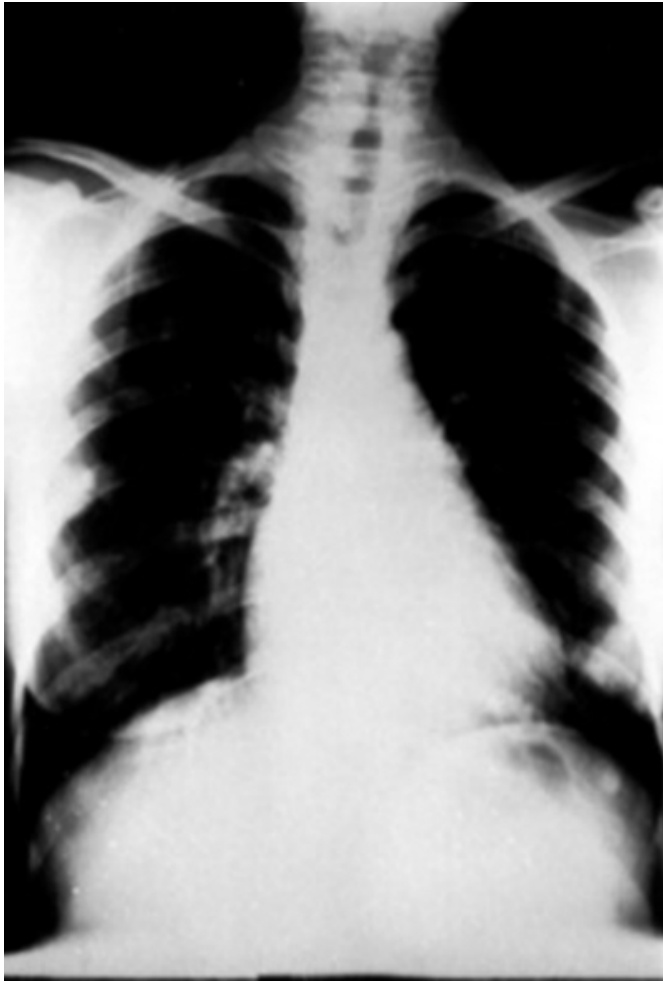
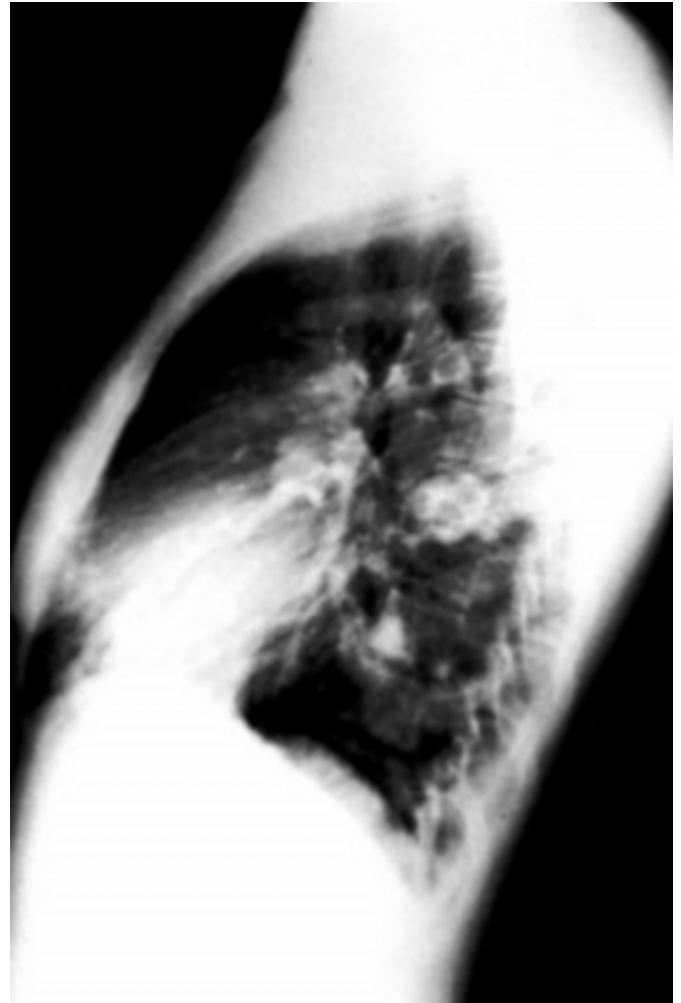


Figure 2

Figure 1b: Lateral view chest X-ray showing few irregularly rounded opacities

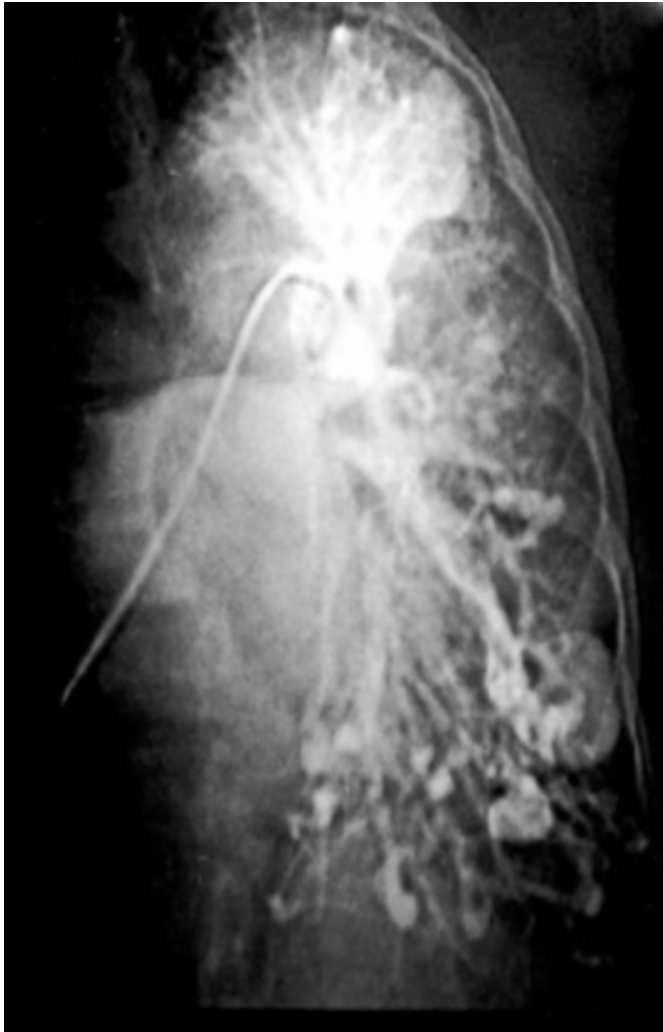

PULMONARY ANGIOGRAM:

Bilateral multiple arterio-venous malformations of various sizes were elicited. Two big round areas filled with contrast with no venous backflow seen in the right mid and left lower pulmonary zones representing big aneurysms. (Fig. 2)

Figure 3

Figure 2: Pulmonary Angiogram on the same patient showing many ovals shaped irregularly sized opacities

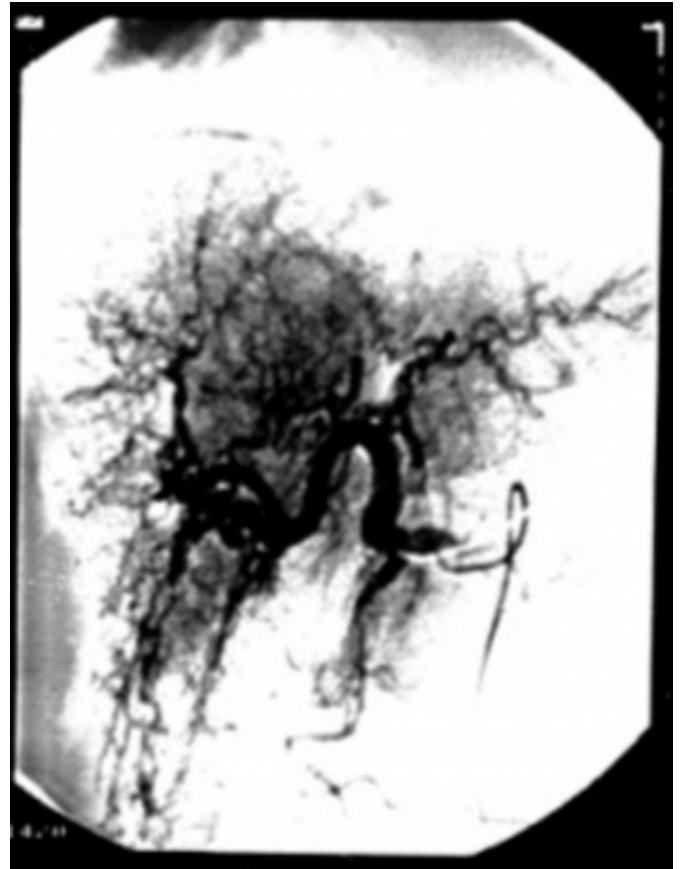

AORTOGRAM WITH SELECTIVE HEPATIC-SPLENIC ARTERIOGRAM:

Multiple aneurysms of the splenic artery, left occipito-cortical fistula, telangiectasia of hepatic and internal carotid arteries were demonstrated. (Fig 3)

Figure 4

Figure 3: Spleen artery aneurysm seen with radio-paque contrast, in the same patient



OESOPHAGEAL ECHOCARDIOGRAPHY:

All cardiac chambers were normal apart from a slight dilatation of the left atrium. Valve structures were normal. There were no other cardiac anomalies. On color Doppler and contrast study there was a suspicion of aorta-pulmonary or coronary pulmonary fistula.

The patient was scheduled for elective splenectomy under general anaesthesia.

GENERAL ANAESTHESIA

The patient received Lorazepam (2 mg) and Ranitidine (150 mg) as premedication (at bedtime and two hours prior to anesthesia). On arrival to the operating theatre routine monitors were placed, intra-venous access (14G Vygon) and an arterial line (20G Ohmeda) were inserted under local anesthesia. General anesthesia was induced using fentanyl, propofol and atracurium. The lungs were ventilated artificially with a mixture of oxygen and nitrous oxide (50:50%). The ventilatory parameters were maintained to keep a peak airway pressure of less than (20 cm) of water.

Blood loss was approximately (650 ml) replaced with human purified plasma fraction. At the end of surgery, which lasted for 150 min., the patient's trachea was extubated after reversal of neuro-muscular block. The patient was transferred to the surgical intensive care unit (SICU), while receiving oxygen supplements through facemask (FiO₂ of 0.5).

SURGICAL ICU COURSE

Regular incentive spirometry and chest physiotherapy were instituted at 4 hourly intervals and the patient had a smooth immediate post-operative recovery. She was transferred to the ward on the second post-operative day in a satisfactory clinical condition.

18 hours later, the patient was tachypneic, tachycardic and hypoxic. Portable Chest X-ray showed complete left lung opacity. A needle was inserted in the 6th intercostal space in the left mid-axillary line to rule out the presence of haemothorax. No blood or fluid was aspirated but the needle insertion caused an iatrogenic pneumo-thorax. Patient's general condition deteriorated and coded. After resuscitation she was transferred back to SICU. Patient's trachea was intubated and lungs were mechanically ventilated. A chest drain was inserted in the left 5th intercostal space in the mid-axillary line and the tube was connected to a water-seal. A fibre-optic bronchoscopic suction was performed. The left lung expanded completely after a period of 36 hours. The trachea was extubated, chest physiotherapy and incentive spirometry was continued. 48 hours later the patient was transferred to the ward and a few days later she was discharged from the hospital.

DISCUSSION

Osler-Weber-Rendu disease is a hereditary disorder of autosomal dominant type characterized by cutaneo-mucous telangiectasia and vascular abnormalities (arterio-venous malformations and aneurysms) in several organs. Mutations in the endoglin gene are responsible factor for OWR syndrome. Endoglin (CD 105) is a cell surface component of transforming growth factor-beta (TGF beta) receptor complex highly expressed by endothelial cells. Bleeding especially epistaxis is an important clinical feature. Pulmonary arterio-venous malformations (AVMs) are seen in 15-20% of these patients and cause hypoxemia, haemoptysis, polycythemia and clubbing. These pulmonary AVMs are distended during pregnancy due to an increase in blood volume, cardiac output. Cerebral embolism, cerebral infarction and brain abscess are clinical manifestations due

to loss of "lung filter" in pulmonary AVMs. In this particular patient, there was concern regarding respiratory involvement and the possibility of bleeding and airway obstruction. Also, the amount of pulmonary circulation shunt effect, which may accompany the atriovenous malformation, can produce severe hypoxemia. Beside this shunt effect the compression on the lung tissues, by A-V anomalies may constitute airway obstruction. In the course of anesthesia this was helped by artificial ventilation of the lungs and close monitoring of saturation of hemoglobin, elimination of carbon dioxide and serial blood gases.

A variety of neurological symptoms caused by CNS angiodyplasia are seen as a part of this disease. AVMs may also extend to the spinal canal hence care should to be taken prior to centro-neuron blocks. So, local anesthesia was out of question, on the ground of site of operation and the required time to fulfill the surgical task. The logic behind immediate intensive care admission post-operatively, is that patient's diagnosis was based mainly on personal history, telangiectasis and investigations (endoscopies, chest X-ray, C.T., and angiographies). The prognosis and survival are favorable provided that treatable complications are diagnosed accurately and treated appropriately. The AVMs are of particular concern during anesthesia as there is a risk of rupture or bleeding due to hemodynamic changes during the process of anesthesia and recovery. The surrounding anxiety and special precaution was enough in the operative and immediate post-operative period to keep the patient safe. The reason for that unexpected complication was probably the lack of communication or misinformation, which made the intermediate post-operative period rather eventful. The excuses given by the surgical night staff -regarding inserting a chest drain- (and may be due to his lack of experience) was failure in diagnosing atelectasis of the lung which might occur post-operatively.

So although all necessary measures were taken to face any possibilities, the surgical team reaches to life threatening situation when atelectic changes happened and misdiagnosed as pneumothorax. The patient was saved and enjoys a good outcome; nevertheless this complication could have been prevented, if the patient was closely observed in the intermediate post-operative period.

CONCLUSION

Although medical teams are in high alert when a patient with rare disease requires to their services, still sometime the team may get caught off-guard. Communication among the

medical team is important to safeguard against such events. Consultation is needed, most of the time, with senior colleagues even in emergency situation.

CORRESPONDENCE TO

Mohamad Said Maani Takrouri, MB. ChB. FFARCS (I)
Professor of Anesthesiology. Consultant in charge of
intensive care unit. Department of Anesthesia King Khalid
University Hospital, Riyadh 11461 P.O. Box 2925 e-mail:
takrouri@ksu.edu.sa

References

1. Shovlin CL, Guttmacher AE, Buscarini E, et al: Diagnostic criteria for hereditary hemorrhagic telangiectasia (Rendu- Osler-Weber syndrome). *Am J Med Genet* 2000 Mar 6; 91(1): 66-7
2. Kjeldsen AD, Oxhøj H, Andersen PE, et al: Pulmonary arteriovenous malformations: screening procedures and pulmonary angiography in patients with hereditary hemorrhagic telangiectasia. *Chest* 1999 Aug; 116(2): 432-9
3. Matsunami K., Nishikawa N., Kawahito M., Kida H. Anesthetic management of a patient with Osler-Weber-Rendu disease. *Masui*. 1999 Jul;48(7):793-5. Japanese.

Author Information

Mohamad Bilal Delvi, MB ChB FKSUA DABA

Senior Registrar, King Khalid University Hospital

Shuja Khan-Ghori, MB ChB FKSUA DABA

Consultant, Dept. of Anaesthesia, King Khalid University Hospital

Mussaid MS Al-Salman, MB ChB FCPS

Professor of Surgery / Chief of Vascular Surgery, King Khalid University Hospital

Mohamad Said Maani Takrouri, MB. ChB. FFARCS (I)

Professor of Anesthesiology / Consultant in charge of intensive care, Department of Anesthesia, King Khalid University Hospital