

Foot Drop Due To Peroneal Ganglion Cyst In An Adolescent

C Jackman, D Sokol, K Applegate, K Kayes, W Mahmud

Citation

C Jackman, D Sokol, K Applegate, K Kayes, W Mahmud. *Foot Drop Due To Peroneal Ganglion Cyst In An Adolescent*. The Internet Journal of Neurology. 2004 Volume 3 Number 2.

Abstract

Nerve compression by a ganglion is rare in children. Compression of the peroneal nerve by a ganglionic cyst causing foot drop is reported in an adolescent male.

CASE REPORT

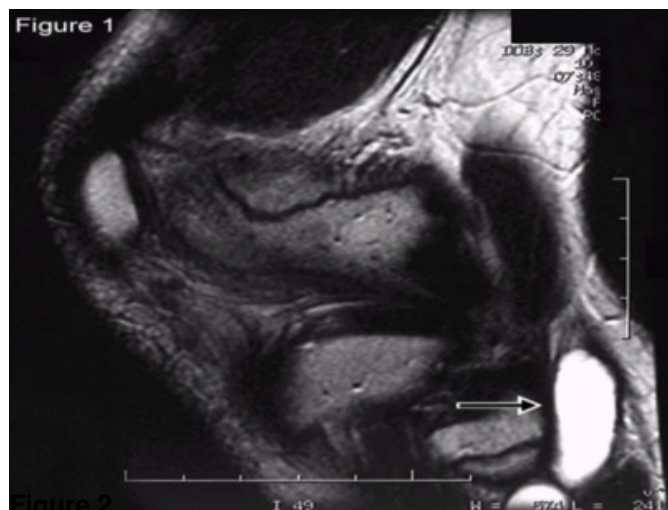
A 14 year-old male tennis player presented with a gradually progressive left foot drop. Three weeks prior, he found a knot behind his left knee that resolved. Sagittal MRI T2-weighted images of the left knee demonstrated a lobulated, cystic mass, antero-lateral to the fibular head. Upon excision, a ganglion cyst was found to be compressing the common peroneal nerve. The child recovered at three months.

CONCLUSION

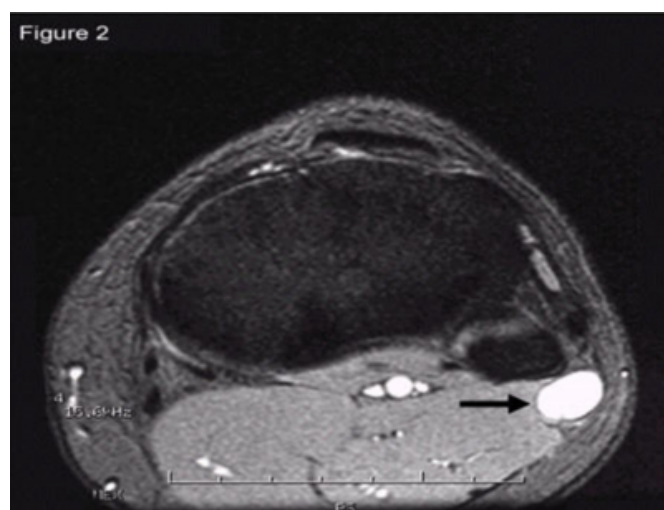
Nerve compression by a ganglion is rare in children (1). Rapid, repetitive actions involving acceleration/deceleration have been theorized to predispose ganglion cyst formation (2).

Figure 1

Figure 1: Sagittal T-2 weighted image of left knee showing ganglion cyst compressing peroneal nerve.



ganglion cyst.



References

1. Beck, TD Jr, Miller, KE & Kruse, RW. An unusual presentation of in toeing in a child. *Journal of the American Osteopathic Association*, 1998; 98: 48-50.
2. Wang, DH, Koehler, SM. Isolated infraspinatus atrophy in a collegiate volleyball player. *Clinical Journal of Sport Medicine*, 1996; 6:255-8.

Figure 2: Axial T-2 weighted image of left knee showing

Author Information

C. Jackman

Department of Neurology, Riley Hospital, Indiana University School of Medicine

D. Sokol

Department of Neurology, Riley Hospital, Indiana University School of Medicine

K. Applegate

Department of Neurology, Riley Hospital, Indiana University School of Medicine

K. Kayes

Department of Neurology, Riley Hospital, Indiana University School of Medicine

W. Mahmud

Department of Neurology, Riley Hospital, Indiana University School of Medicine