

Uncommon Complications Following Burch Colposuspension

R Jeganathan, D Carey

Citation

R Jeganathan, D Carey. *Uncommon Complications Following Burch Colposuspension*. The Internet Journal of Gynecology and Obstetrics. 2007 Volume 9 Number 1.

Abstract

We describe two uncommon cases referred for further surgical management following colposuspension using the Burch technique. In reviewing literature associated with complications following colposuspension, only sparse data were found. Here we present two cases referred to our department within 18 months of primary surgery, in which the aetiology was difficult to diagnose.

CASE 1

A 55 year old lady who had undergone colposuspension for urinary stress incontinence following failure of adequate medical therapy presented with a series of operation site wound infection which was then superseded by the development of an incisional hernia. The hernia recurred despite initial repair. On presentation for repair of the recurrent hernia by the surgical team, the patient also complained of having irritative bladder symptoms which were initially attributed to the existing hernia. Intra-operative repair revealed the incidental finding of a large urinary bladder stone formed on the non-absorbable suture used in colposuspension. This appeared to be the underlying cause to her irritative bladder symptoms. At laparotomy, the ethibond® suture material and stone were extracted from the bladder neck and wall (Fig 1). The patient made an uneventful recovery with complete relief of her bladder symptoms.

CASE 2

A 54 year old lady who had undergone abdominal hysterectomy and colposuspension presented two years later with a fluctuant lump beneath the old scar which originally had healed by delayed primary intention. The tender mass was discharging purulent material and despite three courses of antibiotic treatment, failed to heal. Further wound exploration revealed a discharging sinus extending from the abdominal scar to the pubic symphysis, which was excised and subsequently healed. However, the woman presented again ten months later with similar symptoms and was referred surgically. An initial sinogram (Fig 2a and 2b)

revealed a sinus tract leading to a regular space within the pelvis with no other communication. Further exploration revealed two infected non-absorbable ethibond® sutures just posterior to the pubic symphysis lying in an abscess cavity. All infected material was removed. Post-operative recovery was uneventful and the patient has had complete healing of her wound.

Figure 1

Figure 1: Urinary bladder stone [long arrow] which formed around a non-absorbable suture material [short arrow] (Ethibond®) used in colposuspension.

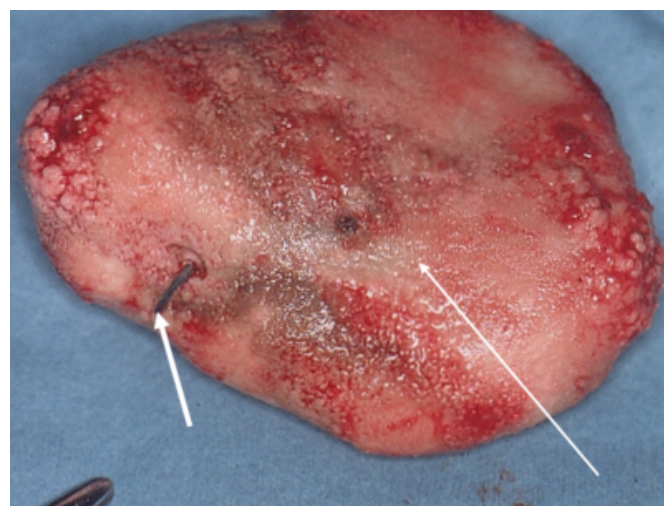


Figure 2

Figure 2a: Sinogram showing a sinus tract leading to a potential space [arrow] within the pelvis.

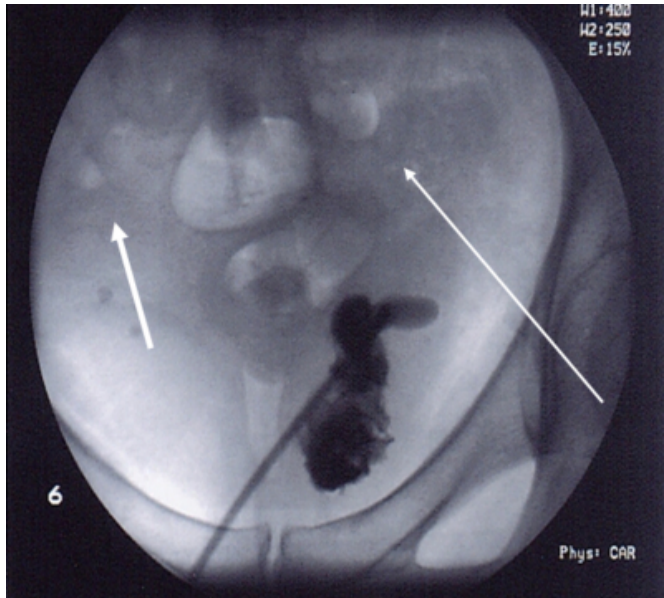
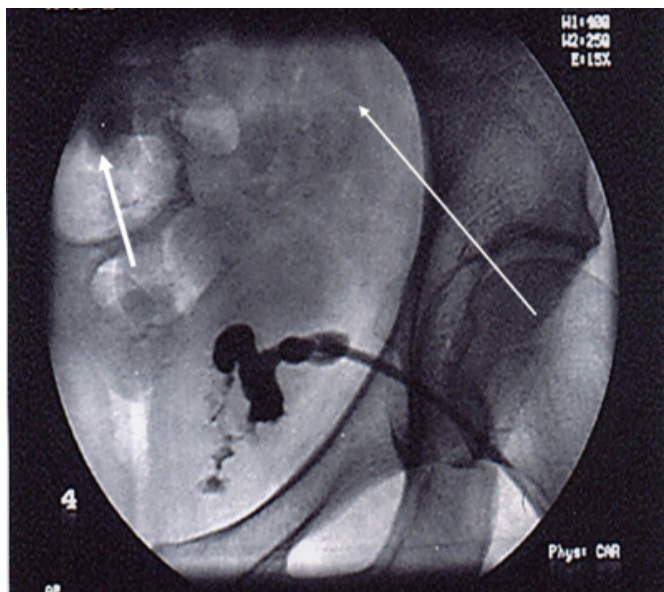


Figure 3

Figure 2b: Sinogram showing the fully outlined potential space [arrow].



DISCUSSION

The aims of continence surgery are to elevate the bladder neck, support the mid urethra or increase urethral resistance. In general, the first attempt at continence surgery produces better results than repeat procedures [1].

Colposuspension is one of many techniques used in the surgical management of genuine urinary stress incontinence associated with cystourethrocele. Described by Burch in

1961, it involves placing two or three sutures (ethibond) between the paravaginal fascia on either side of the bladder neck and the base of the bladder and is attached to the ipsilateral iliopectineal ligament [2]. This procedure corrects both urethral sphincter incompetence and descent of the anterior vaginal wall (cystourethrocele).

Iatrogenic bladder stone formation may result from the use of non absorbable suture material in sustaining long term maintenance of bladder neck elevation, as has been previously reported [3]. As mentioned above, the sutures which are placed at the bladder neck may inadvertently erode into the bladder lumen and thus create a nidus for stone formation. Alternatively, they may be inadvertently placed through the bladder wall and enter the bladder lumen.

The use of non-absorbable suture material was mainly advocated in maintaining the long term effect of bladder neck elevation, thus preventing a recurrence of urinary symptoms. However, with adequate tissue mobilization during surgery and the subsequent healing with adherence, it is possible to use absorbable suture material in place of non-absorbable material, thus reducing the incidence of such complications [4].

Persistence of wound discharge and infection is due to infected foreign material until proven otherwise, as noted in the above mentioned case. Thus, the need for a sinogram as part of the investigation is important to establish the possibility of a chronic infective cavity, which in the above mentioned case was missed at first exploration. Only when the infected foreign material was located and removed did the patient make a full recovery.

The other possible complications associated with this technique are bleeding from the perivesical veins, injury to the bladder and ureter during dissection and suturing, voiding dysfunction, detrusor instability, prolapse and infection. Rare complications such as deep vein thrombosis have been known to occur as can incisional hernia, pulmonary embolism, ileus, sepsis and external iliac vein injury. The success rate is between 60-90% for patients who have not had previous incontinence surgery [5].

Colposuspension remains the gold standard operation against which new techniques should be compared [6].

CONCLUSION

The two cases mentioned are infrequent yet probable complications following colposuspension and need to be addressed with concern. These two separate complications

whilst arising from the same technique, were seen within 18 months of primary surgery by the same surgical team for further management, thus questioning the frequency of such complications. The occult nature of bladder calculi and deep pelvic infection make early diagnosis difficult. There should be a greater awareness of the possibility of complications which could arise from the use of non-absorbable suture material.

CORRESPONDENCE TO

Mr R Jeganathan Ward 5, General Surgical Unit Ulster
Hospital Dundonald Belfast BT16 1RH N. Ireland Tel: +44
(0) 28 90561358 Fax: +44 (0) 28 90561374 Email:
rakeshjeganathan@yahoo.co.uk

References

1. Jarvis GJ. Surgery for genuine stress incontinence. *Br J Obstet Gynecol* 1994; 101: 371-74.
2. Burch JC. Urethro-vaginal fixation of Cooper's ligament for correction of stress incontinence, cystocele and prolapse. *AM J Obstet Gynecol* 1961; 81: 281-90.
3. Moyana Calvo JL, Romero Diaz A, Ortiz Gamiz A et al. Iatrogenic bladder lithiasis in the Burch technique. *Arch Esp Urol* 2000 Jun; 53(5): 468-469.
4. HH Woo, DJ Rosario, CR Chapple. Stone formation on permanent suture material used previously in colposuspension. *Br J Urol* 1995; 76: 139-40.
5. Jarvis GJ. Surgical treatment of incontinence in adult women. In: Abrams P, Saad K, Wein A, eds. *Incontinence*. St Helier, NJ : Health Publications 1999 : 637-56.
6. Bidmead J, Cardozo L. Genuine Stress Incontinence: Colpocystourethropexy versus sling procedures. *Current opinion in Obstetrics & Gynaecology* 2000 Oct ; 12(5): 421-26.

Author Information

Rakesh Jeganathan, M.B.B.S MRCSEd

Clinical Fellow, G. Surgery, General Surgery Unit, Belfast City Hospital

Declan Carey, MCh. FRCSI

Consultant Surgeon, General Surgery Unit, Belfast City Hospital