

# The Occurrence Of Pleural Effusion Secondary To Ovarian Fibroma

S Kant, S Verma, R Verma

## Citation

S Kant, S Verma, R Verma. *The Occurrence Of Pleural Effusion Secondary To Ovarian Fibroma*. The Internet Journal of Pulmonary Medicine. 2008 Volume 10 Number 2.

## Abstract

The association of pleural effusion and ascitis, secondary to ovarian tumor, are considered to be uncommon clinical condition. Hereby we reported a case of 43 years old female presented as right sided pleural effusion and ascitis secondary to ovarian fibroma and after removal of ovarian tumor resulted into disappearance of the pleural effusion and ascitis.

## INTRODUCTION

Meigs's syndrome is defined as the presence of ascites and hydrothorax in association with a benign ovarian tumor and found to be a rare clinical entity<sup>1</sup>. The ovarian tumour is usually a fibroma, followed by ovarian cyst, thecoma, granulosa cell tumour and leiomyomas of uterus. Meig's syndrome accounts for about 1% of ovarian tumours<sup>2</sup>. It is very uncommon before 40 years of age and becomes more frequent as the years progress but there are some reports of it arising from teratomas or cystadenomas in pre-pubertal girls. Characteristically ascites and hydrothorax resolve spontaneously and permanently after removal of the tumor<sup>3</sup>. Pseudo-Meigs syndrome consists of pleural effusion, ascites, and benign tumors of the ovary other than fibromas. These benign tumors include those of the fallopian tube or uterus and mature teratomas, struma ovarii, and ovarian leiomyomas.

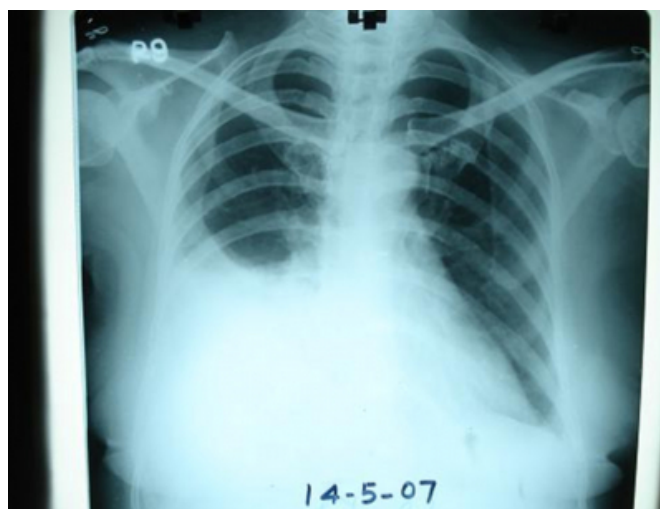
## CASE REPORT

A 43 year old female was admitted to our department with complaints of breathlessness and right sided chest pain for the last 1 months. She also had swelling of lower abdomen for last 2 months. The resting pulse rate was 92/min and blood pressure was 112/74 mm Hg. Her general examination reveals pallor and on chest examination, there was evidence of fluid in the right pleural cavity. Abdominal inspection revealed fullness of lower abdomen without any prominent veins or distortion of the umbilicus. No mass could be palpated but there was tenderness in the left iliac fossa and part of the hypogastrium. Liver, spleen, and inguinal lymph nodes were not palpable. On percussion there was shifting dullness due to free fluid. Auscultation revealed normal

intestinal peristaltic sounds. Her chest x-ray revealed right sided pleural effusion(Figure: 1).

## Figure 1

Figure 1: revealed right sided pleural effusion

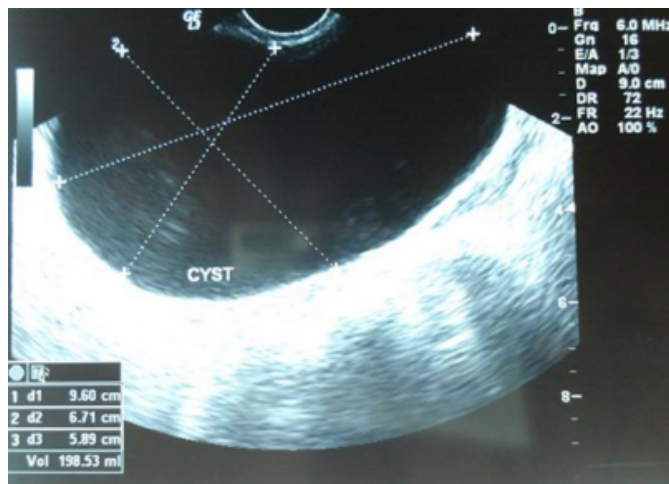


A right thoracentesis was done that revealed thin, straw, pleural fluid. Pleural fluid was sent for examination that revealed protein 5.4 g/100 mL (serum protein, 8.0 g/100 mL, sugar 44 mg%, total leukocyte count 880 cells/mm<sup>3</sup>, differential leucocytes count: neutrophils 12, lymphocytes 88. Adenosine deaminase (ADA) level in the pleural fluid was 32 u/lit (normal limit being less than 40 u/lit). No organisms were identified on Gram's stain or culture (including Mycobacterium Tuberculosis). Pleural fluid was negative for malignant cells on 5 consecutive occasions. Her pleural biopsy was done by Abraham's needle that came to be negative. PPD showed no indurations. Her CT thorax revealed left sided pleural effusion.

As thyroid, breast and genitourinary tract malignancies can very commonly present initially as lung metastasis, so ultrasound neck for thyroid, mammography for breast nodule and ultrasound abdomen but all investigations came out to be normal except left sided ovarian mass of 10 x 8.4 x 7.6 cm with few cystic spaces, moderate ascitis found on Ultrasonography abdomen( Figure: 2).

**Figure 2**

Figure 2 : Revealed left sided ovarian mass of 10 x 8.4 x 7.6 cm with few cystic spaces.



So The Diagnosis Of syndrome called as Meigs syndrome was arisen. Her serum CA 125 was 10.8 U/mL (Normal: 2-35 U/mL).

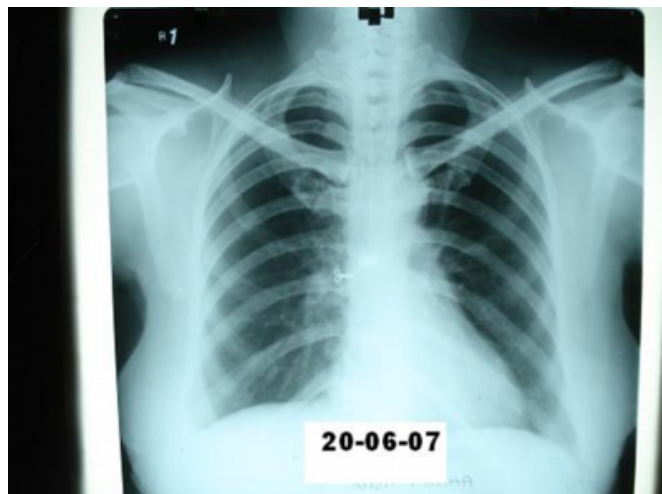
She underwent exploratory laparotomy under general anesthesia and a decision for left salpingo oophorectomy was taken. Exploration of the peritoneal cavity did not show any palpable lymph node or other metastasis. Post-operative period was uneventful. The histopathology of left ovarian mass confirmed diagnosis of fibroma .

Thus a diagnosis of Meigs syndrome presented as pleural effusion was made.

The patient was discharged in a healthy condition. She came for follow up after 4 weeks with a repeat abdominal USG and chest x-ray which showed complete disappearance of the ascites and pleural effusion respectively( Figure: 3).

**Figure 3**

Figure 3 : Revealed complete disappearance of pleural effusion .



## DISCUSSION

Meigs in 1932<sup>4</sup>, and Meigs and Cass<sup>5</sup>, drew attention to the occurrence of cases of ovarian fibroma associated with simultaneous fluid effusion in the abdominal and chest cavity and the effusion disappearing spontaneously when the tumor is removed.

The Ovarian tumors are divided into the following histologic subgroups, and Meigs syndrome can be observed with any of the benign tumors. The commonest are the epithelial tumours forming 80 % of all tumor. 80 % are benign tumour and 20 % are malignant. Of all malignant tumor, 90 % are epithelial in origin. 80 % are primary in the ovary and 20 % secondary from breast, gastrointestinal tract and colon. The benign tumor can become secondarily malignant.

A. Coelomic epithelial tumors: These tumors, which originate from the coelomic epithelium, constitute 80-85% of all ovarian tumors.

-Serous cystadenoma and mucinous cystadenoma: Fifteen to 20% are malignant.

-Endometrioid type and clear cell: Ninety-five to 98% are malignant.

-Brenner tumor: Two percent are malignant.

B. Germ cell tumors: These tumors originate from the germ cell and constitute 10-15% of all ovarian tumors. All are malignant except mature teratomas and gonadoblastomas, which are always benign.

-Mature teratoma

- Immature teratoma
- Dysgerminoma
- Gonadoblastoma
- Endodermal sinus
- Embryonal carcinoma
- Nongestational choriocarcinoma

C. Gonadal-stromal cell tumors : These tumors constitute 3-5% of all tumors.

- Granulosa cell
- Fibroma: Fewer than 5% are malignant.
- Thecoma: Fewer than 5% are malignant.
- Sertoli-Leydig cell: Fewer than 5% are malignant.
- Lipid cell type: Thirty percent are malignant.
- Gynandroblastoma: One hundred percent are malignant

The pathogenesis of ascetic fluid patients with meigs syndrome appears to be a generalized secretion of fluid from primary tumor. The serum levels of IL-1, IL-6, IL-8, tumor necrosis factor alpha and VEGF are elevated in patients with meigs syndrome as compared with controls. Interestingly, cytokine levels in the pleural fluid and ascetic fluid were higher than the simultaneously obtained serum levels <sup>6</sup>.

Genesis of the ascitic fluid may be explained in four possible ways. Firstly, it may be produced by transudation from the tumour surface. Secondly, there may be special secretory cells within the tumour which produce the fluid. Thirdly, it may be produced as a result of disturbances in hormone metabolism. Some ovarian tumours are oestrogenic. Hypersecretion of oestrogens has an adverse effect on electrolyte balance which is usually shown as increased water percentage in the intra cellular spaces of the uterus <sup>7,8</sup>. Lastly, the fluid may be produced by mechanical stretching of the peritoneal lining above the ovary as the tumour grows in size. This would bring about an increase in the size of the inter-cellular spaces which could ultimately be such that lymph would escape through them.

The genesis of pleural fluid in meigs syndrome is probably due to passage of fluid through pores in the diaphragm. Meigs demonstrated in some of his cases, that India ink

injected into the ascitic fluid, quickly passed into the pleural fluid <sup>9</sup>. As no dye appeared in the blood or corpuscles, it was assumed that passage was solely through the lymphatics. Yoffey and Courtice<sup>18</sup> have discussed fully the lymphatic drainage of the peritoneum <sup>10</sup>, and Efskind reported that Chinese ink injected intra-peritoneally was eliminated quickly by the retro-sternal lymphatics and was to be found, within half-an-hour, in the lymphatics on the pleural side of the diaphragm <sup>11</sup>. Florey<sup>20</sup> pointed out that the very porous nature of the lymphatics on the diaphragmatic surface appears to be unique, having the ability to pass small particulate matter <sup>12</sup>. It has also been observed that the lymphatic drainage does not take place evenly over the whole diaphragmatic surface, but is more extensive on the right side.

Patients with Meigs syndrome usually have a chronic illness characterized by weight loss, pleural effusion, ascites and pelvic mass.

Pleural effusion, in cases of meigs syndrome, are usually right sided in approximately 70 % and left sided in 10 % and s bilateral in 20 % <sup>13</sup>. The pleural effusion is usually exudates in meigs syndrome, although several authors had stated that it may be transudate also <sup>1,14</sup>. Most pleural fluids secondary to Meigs syndrome have proteins level above 3.0 g/dL <sup>1,14</sup>. The pleural fluid usually has a low white blood cells( WBC) count(fewer than 1,000/cmm <sup>3</sup>) and occasionally hemorrhagic <sup>15,16</sup>. The patients with meigs syndrome may even have markedly elevated serum CA 125 levels <sup>17</sup>.

The dignosis of meigs syndrome considered in all women who have pelvic masses, ascitis and pleural effusion. if in such patients cytologic examination of ascitis and pleural fluid is negative, an exploratory or atleast a diagnostic laproscopy should be performed with surgical removal of primary neoplasm. The diagnosis is conformed when pleural fluid and ascetic fluid resolve postoperatively and do not recur. Postoperatively pleural fluids disappear from the thoracic cavity rapidly and is usually completely gone within 2 weeks <sup>18</sup>.

### **CORRESPONDENCE TO**

Prof. Surya Kant M.D., FCCP(USA), FNCCP, FCAI  
Department of Pulmonary Medicine C.S.M. Medical  
University (Erstwhile King Georges Medical University),  
Lucknow(India)- 226003 E-mail: Kant\_skt@rediffmail.com  
Phone: 0522-2258059

## References

1. Meigs JV. Pelvic tumors other than fibroma of ovary with ascitis and hydrothorax. *Obstet Gynecol* 1954;3:471-86.
2. Abramov Y, Anteby SO, Fasouliotis SJ, et al; The role of inflammatory cytokines in Meigs' syndrome.; *Obstet Gynecol*. 2002;99:917-9.
3. Samanth KK, Black WC 3rd; Benign ovarian stromal tumors associated with free peritoneal fluid.; *Am J Obstet Gynecol*. 1970 15;107:538-45.
4. Meigs J V . Tumours of the female pelvic organs. Macmillan &Co., Ltd. New York, 1934.
5. Meigs JV, Cass JW. Fibroma of the ovary with ascites and hydrothorax: with a report of seven cases.; *Am J Obstet Gynecol* 1937; 33: 249-267.
6. Abramov Y, Anteby SO, Fasouliotis SJ, Barak V. The role of inflammatory cytokines in Meigs' syndrome. *Obstet Gynecol*. 2002 ;99:917-9.
7. Bernnan D M , Zarrow M X . *Endocrinology*, 1959 ;64, 907.
8. Spaziani E , Szego C M . *Amer. J. Physiol.* 1959 , 197, 355.
9. Meigs J V , Armstrong S H , Hamilton H H. *Amer. J. Obstet. Gynec.* 1943, 46: 19.
10. Yoffey J M , Courtice F C . *Lymphatics, Lymph and Lymphoid Drainage*, Edward Arnold (Publishers) Ltd., London, 1956.
11. Efskind L . *Exper. Untersuch, uber die Biologie des Peritoneum,I-II*, Oslo, 1940.
12. Florey H . *Lectures on General Pathology*, Lloyd-Luke (Medical Books) Ltd., London, 1954.
13. Mazlin G,Stevens FL.Meigs syndrome: case report and review of literature. *J Int Coll Surg*,1964;42:625-630.
14. Flanagan SJO, Tighe BF, Egan TJ, , Delaney PV . Meigs' syndrome and pseudo-Meigs' syndrome. *J R Soc Med.* 1987 ; 80: 252-253.
15. Neustadt JE, Levy RC. Hemorrhagic pleural effusion I meigs syndrome .*JAMA*,1968;204:179-80
16. Agaba EI, Ekwempu CC, Ugoya SO, Echejoh GO. Meigs' syndrome presenting as haemorrhagic pleural effusion. *West Afr J Med.* 2007 ;26:253-5.
17. Patsner B. Meigs syndrome and "false positive" preoperative serum CA-125 levels: analysis of ten cases. *Eur J Gynaecol Oncol.* 2000;21:362-3.
18. Jimerson SD. Pseudo-Meigs's syndrome. An unusual case with analysis of the effusions. *Obstet Gynecol.* 1973 ;42:535-7.

**Author Information**

**Surya Kant, MD, FCCP (USA), FNCCP**

Professor, Department of Pulmonary Medicine, C. S. M. Medical University

**Sanjay Kumar Verma, MD**

Senior Resident, Department of Pulmonary Medicine, C. S. M. Medical University

**Rajendra Verma**

Junior resident, Department Of Internal Medicine, M.L.N. Medical college