

Boop-like Reaction: An Unusual Presentation of Pulmonary Histiocytosis X

A Huaranga, N Herrera, F Leyva, C Sotelo, J Ro

Citation

A Huaranga, N Herrera, F Leyva, C Sotelo, J Ro. *Boop-like Reaction: An Unusual Presentation of Pulmonary Histiocytosis X*. The Internet Journal of Pathology. 1999 Volume 1 Number 1.

Abstract

We report the case of a 51-year-old non-smoking man who presented with flu-like symptoms and patchy, migratory infiltrates as evidenced on a chest-X ray. No response to antibiotic therapy was noted. Transbronchial lung biopsy revealed BOOP-like reaction associated with histopathology characteristic of pulmonary histiocytosis X. Immunoperoxidase stain showed histiocytic cells being positive for S-100 protein and CD1a. Along with the Langerhans cell proliferation, a bronchiolitis obliterans organizing pneumonia-like reaction was noted. In this paper, we discuss in this patient medical course and the clinical and pathologic characteristics of this unusual presentation of pulmonary histiocytosis X.

ABBREVIATIONS

INTRODUCTION

Pulmonary Histiocytosis X (PHX) is a rare granulomatous disease of unknown etiology characterized by ill defined granulomas containing a large number of Langerhans cells (LC). It represents less than 4% of all forms of interstitial lung disease. The pathogenesis of PHX is related to an uncontrolled immune reaction initiated by LC, and clearly associated with cigarette smoking. PHX responds modestly to corticosteroid, and other anti-inflammatory agents.

CASE REPORT

A 51-year-old White man was admitted to the hospital after 2 weeks of dry cough, low-grade fever, generalized malaise, and nasal congestion. He was treated for a respiratory tract infection with 1500-mg Penicillin qd for 7 days, with minimal response. Clarithromycin was then added at 500 mg twice a day for 7 days; without significant improvement.

The patient had a longstanding history of allergic rhinitis but no drug allergies. There were no environmental or occupational exposures. He did not smoke or abuse alcohol. He worked as a salesman.

Physical examination showed a patient was not in distress and was alert and oriented. Vital signs were temperature, 38.5°C; respiratory rate was 20 breaths/min; blood pressure,

130/70; heart rate, 90; oxygen saturation, 96% on room air. Auscultation of the lungs revealed a bilateral ronchi and basilar crackles. The remaining physical examination was normal. The hemoglobin and white cell count was normal with mild eosinophilia. The pulmonary function tests showed a mild decrease in diffusing lung capacity.

Chest-X radiograph (CXR) showed patchy infiltrates and consolidation in the left lower lobe (Fig 1.A). Lymphocytosis and eosinophilia were found in bronchoalveolar lavage. No organisms were identified.

On admission to the hospital, intravenous antibiotics were started, and of respiratory symptoms improved. The CXR done at discharge showed partial resolution of the previous patchy infiltrates. After seven days the patient returned complaining of fever, chills, and malaise and the CXR showed new infiltrates on the right lower lobe (Fig 1.B). He underwent bronchoscopy and transbronchial lung biopsy revealed in light microscopic examination ill-defined granulomas containing an interstitial infiltrate with large number of histiocytes. The histiocytes showed reniform nuclei with longitudinal nuclear grooves and abundant pale, eosinophilic cytoplasm, which were consistent with LC (Fig 2.A). Histopathology was confirmed by immunoperoxidase staining positive for S-100 protein, and CD1a, (Fig 2.B), which confirm the diagnosis of PHX. 14 actually known as

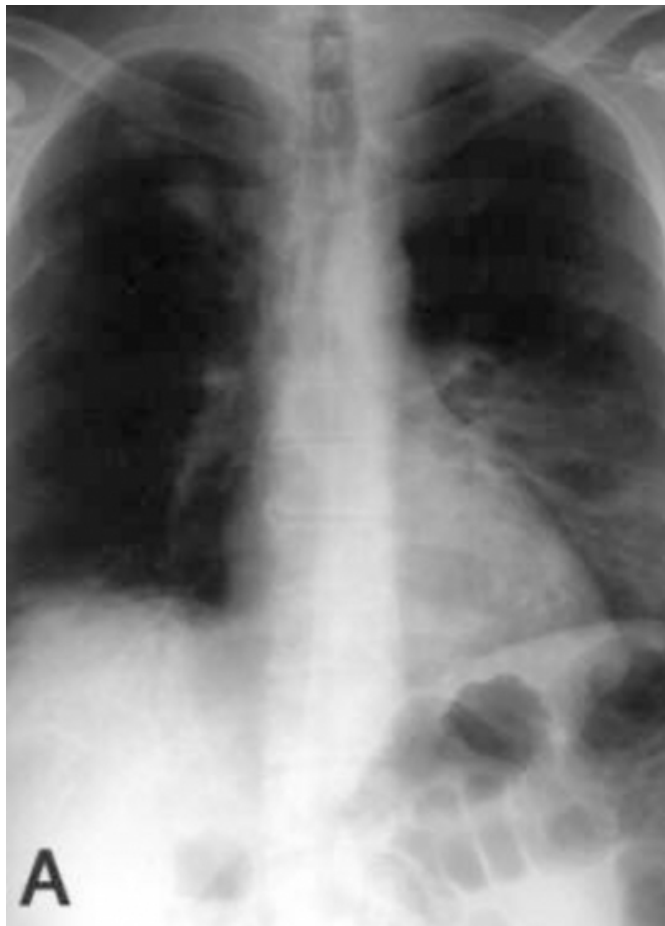Langerhans cell granulomatosis. ² In addition, granulation-tissue type fibrosis was observed obstructing the bronchioles and within alveolar spaces, which is compatible with bronchiolitis obliterans organizing pneumonia. (BOOP)(Fig 2.C)

Corticosteroids were started and marked clinical and radiological improvement was noted in only one week (Fig 1.C)

Chest-X radiograph (CXR) showed patchy infiltrates and consolidation in the left lower lobe (Fig 1.A).

Figure 1

Figure 1 A: Chest-X radiograph (CXR) showed patchy infiltrates and consolidations in the left lower lobe



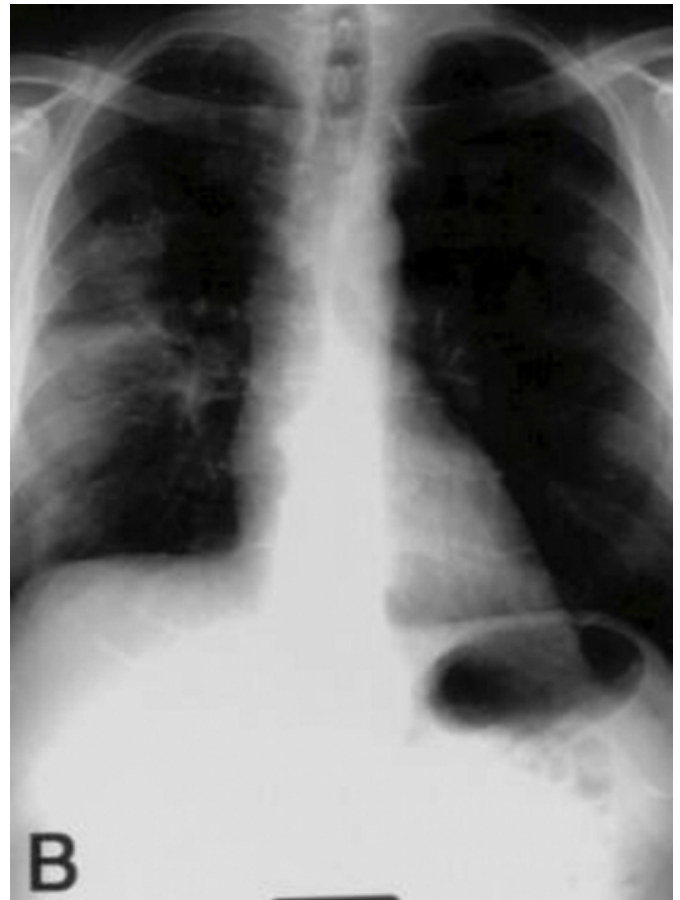
Lymphocytosis and eosinophilia were found in bronchoalveolar lavage. No organisms were identified.

On admission to the hospital, intravenous antibiotics were started, and of respiratory symptoms improved. The CXR done at discharge showed partial resolution of the previous patchy infiltrates. After seven days the patient returned complaining of fever, chills, and malaise and the CXR

showed new infiltrates on the right lower lobe (Fig 1.B).

Figure 2

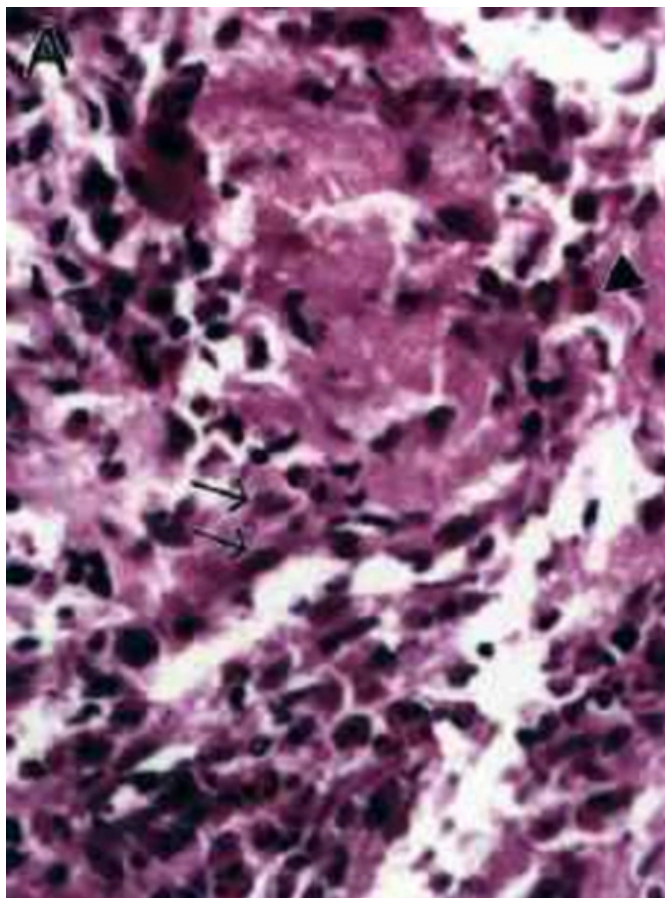
Figure 1 B: After seven days the CXR showed new infiltrates on the right lower lobe.



He underwent bronchoscopy and transbronchial lung biopsy revealed in light microscopic examination ill-defined granulomas containing an interstitial infiltrate with large number of histiocytes. The histiocytes showed reniform nuclei with longitudinal nuclear grooves and abundant pale, eosinophilic cytoplasm, which were consistent with LC (Fig 2.A).

Figure 3

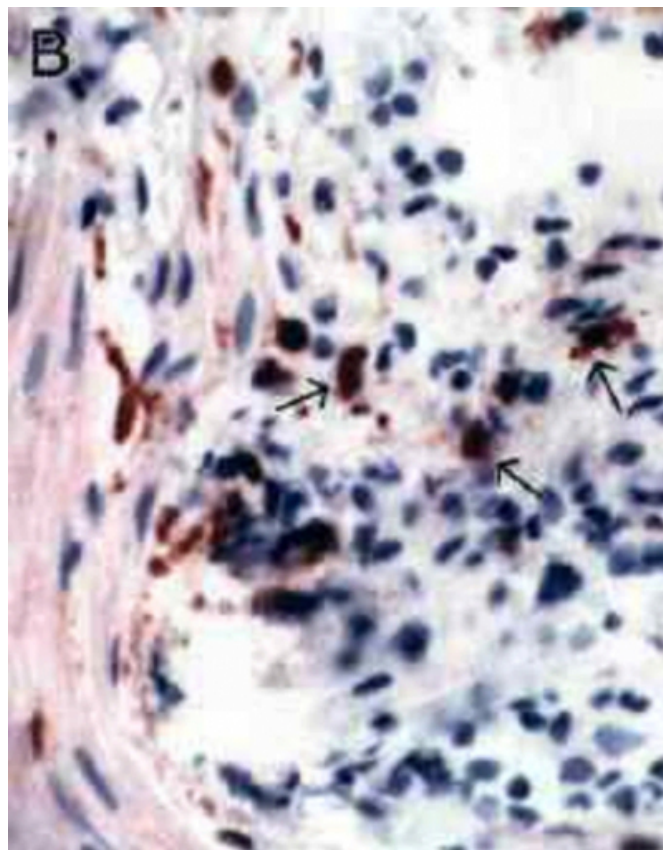
Figure 2 A: Pulmonary biopsy specimen revealing histiocytes with reniform nuclei (arrow) and scattered eosinophils (arrow head) (hematoxylin eosin, original x 400).



Histopathology was confirmed by immunoperoxidase staining positive for S-100 protein, and CD1a, (Fig 2.B), which confirm the diagnosis of PHX. ^{1,4} actually known as Langerhans cell granulomatosis. ²

Figure 4

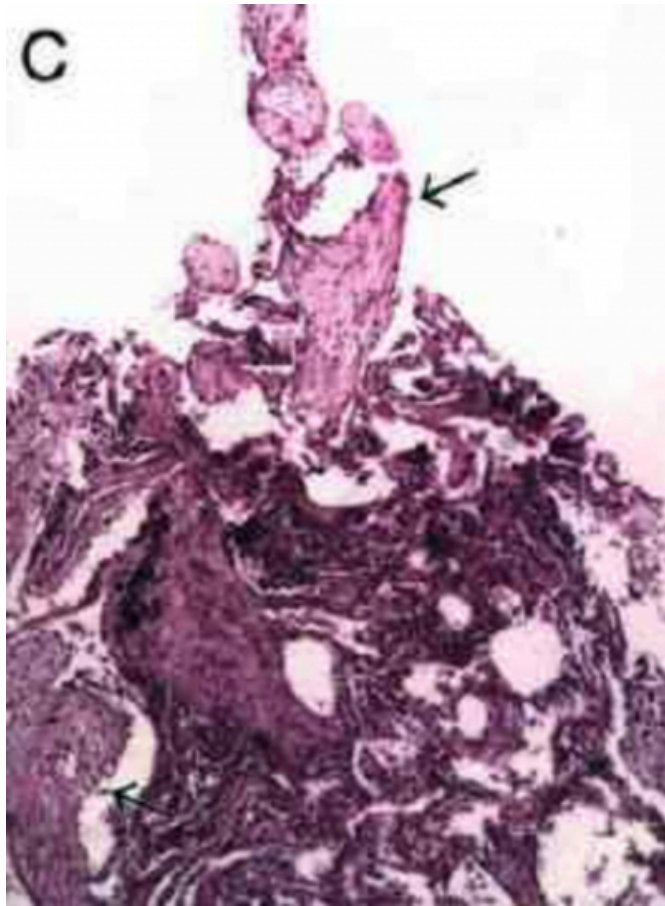
Figure 2 B: Immunohistochemical stain showing that these cells (arrow) were positive for S-100 protein (original x 400).



In addition, granulation-tissue type fibrosis was observed obstructing the bronchioles and within alveolar spaces, which is compatible with bronchiolitis obliterans organizing pneumonia. (BOOP)(Fig 2.C)

Figure 5

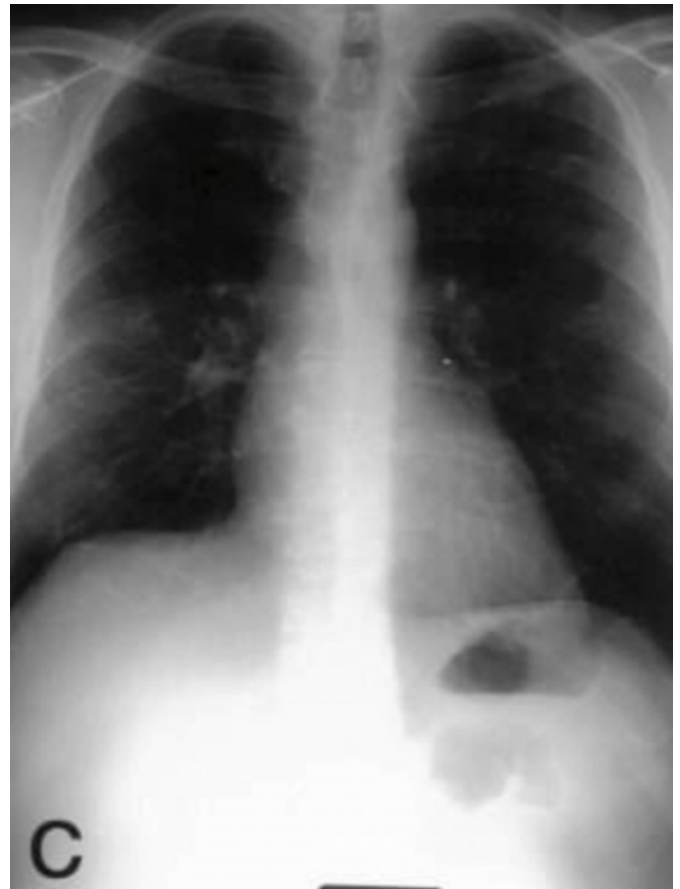Figure 2 C: Granulation tissue obliterating bronchioles characteristic of BOOP (original x 100).



Corticosteroids were started and marked clinical and radiological improvement was noted in only one week (Fig 1.C)

Figure 6

Figure 1 C: Improvement after one week of treatment



DISCUSSION

This patient did not follow the classic clinical, radiological, and pathological expression of PHX.

In fact, he presented with an acute pneumonic syndrome and did not respond to antibiotics. Migratory infiltrates were subsequently noted highly suggesting eosinophilic pneumonia. However, histopathology was very convincing of the presence of PHX and concomitant BOOP.

The characteristic pathologic finding in PHX is the presence of focal, discrete, and scattered granulomatous lesions containing LC. The granulomas are poorly demarcated. ^{1 3} Because of their strong predilection to occur around bronchioles, they may cause destruction of the bronchiolar wall with resultant cystic change. Subpleural lesions are common, and rupture of cysts causes pneumothorax.

Usually, the radiological features of PHX vary with the stage of the disease, ³ and patients with PHX have diffuse bilateral, reticulonodular, cystic, and honeycombing lesions, preferentially affecting the upper and middle zones; costophrenic angles are spared. The changes are bilateral and

diffuse but not always symmetrical; 3 however the patient we reported had alveolar patchy and migratory infiltrates.

The institution of corticosteroid therapy in this patient led to almost complete resolution of the pulmonary infiltrates in only one week. This was rather unusual, because patients normally respond slowly and not in the magnitude that this patient did.

BOOP, the clinicopathological syndrome, occurs in response to a wide variety of pulmonary injuries, resulting in proliferation of granulation tissue in the lumens of the small conducting airways 5 with preservation of the lung architecture. 4 BOOP should be considered in patients with flu-like symptoms lasting longer than expected with bilateral patchy infiltrates on the CXR and no response to antibiotics. Patients have sometimes a preexisting, associated conditions such as collagen vascular disease, drug or toxin reaction, resolving infections, toxic inhalation, human immunodeficiency virus infection, radiation therapy, thyroiditis, alcoholic cirrhosis, diffuse alveolar damage, and cancer. 5 6 BOOP reaction is commonly seen in cases of acute interstitial pneumonia, extrinsic allergic alveolitis,

chronic eosinophilic pneumonia, and non-infectious angeitis, and granulomatosis, but it has never been reported with PHX.

This is the first case of PHX that has been shown to behave in this rather unusual fashion with migratory infiltrates concomitantly associated with BOOP and also that has such as dramatic symptomatic response to corticosteroid therapy.

References

1. Tazi A, Hance AJ, Soler P. Cells of the dendritic cell lineage in human lung carcinomas and pulmonary histiocytosis X. In: Lipscomb MF, Russell SW, editors. Lung macrophages and dendritic cells in health and disease. New York: M. Dekker, 1997: 725-757.
2. Osband ME, Pochedly C. Histiocytosis-X: an overview. Hematol Oncol Clin North Am 1987; 1(1):1-7.
3. Marcy TW, Reynolds HY. Pulmonary histiocytosis X. Lung 1985; 163(3):129-150.
4. Shimosato Y, Miller RR. Chronic Infiltrative Lung Disease. In: Shimosato Y, Miller RR, editors. Biopsy interpretation of the lung. New York: Raven Press, 1995: 78-113.
5. Epler GR. Bronchiolitis obliterans organizing pneumonia: definition and clinical features. Chest 1992; 102(1 Suppl):2S-6S.
6. Colby TV. Pathologic aspects of bronchiolitis obliterans organizing pneumonia. Chest 1992; 102(1 Suppl):38S-43S.

Author Information

A. Huaringa, MD, FACP, FCCP

Department of Internal Medicine Specialties, Pulmonary and Critical Care Medicine, The University of Texas M. D. Anderson Cancer Center

N. Herrera, MD

Department of Internal Medicine Specialties, Pulmonary and Critical Care Medicine, The University of Texas M. D. Anderson Cancer Center

F. Leyva, MD

Department of Internal Medicine Specialties, Pulmonary and Critical Care Medicine, The University of Texas M. D. Anderson Cancer Center

C. Sotelo, MD

Department of Internal Medicine Specialties, Pulmonary and Critical Care Medicine, The University of Texas M. D. Anderson Cancer Center

J. Ro, MD, Ph.D.

Department of Internal Medicine Specialties, Pulmonary and Critical Care Medicine, The University of Texas M. D. Anderson Cancer Center