

Inverted ileal prolapse through patent Vitellointestinal duct: a case report

M Zea, R Chana, A Anees, S Khan

Citation

M Zea, R Chana, A Anees, S Khan. *Inverted ileal prolapse through patent Vitellointestinal duct: a case report*. The Internet Journal of Pediatrics and Neonatology. 2008 Volume 10 Number 2.

Abstract

Vitellointestinal duct is well known because of its various complication and presentation. Prolapse of small bowel through patent vitellointestinal duct is one of the presentations that have been reported. We are reporting a case of patent vitellointestinal duct through which whole of distal ileal segment had been intussuscepted and prolapsed outside the abdominal wall.

INTRODUCTION

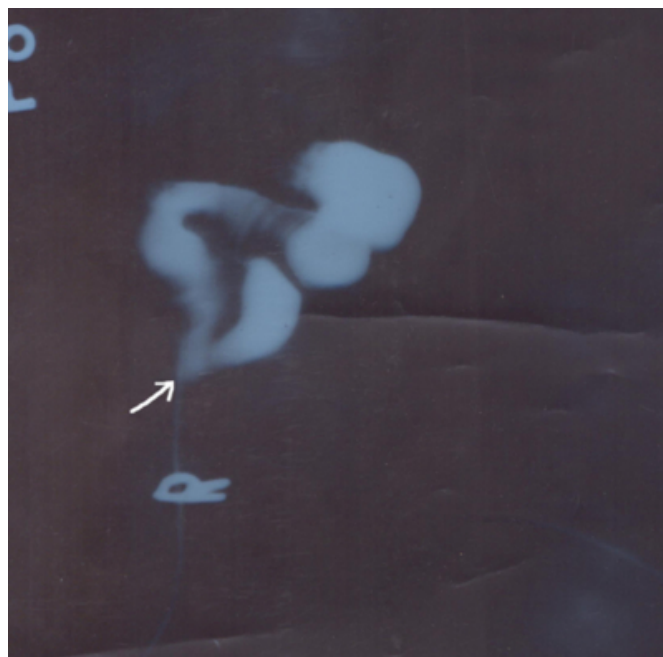
Meckel's diverticulum is most common gastrointestinal anomaly found in about 1 to 2 of normal subject, resulting from persistence of the intestinal end of the vitellointestinal duct. Mostly remains undiagnosed till it become complicated. We are presenting a case of patent vitellointestinal duct with umbilical fecal fistula presenting in emergency with prolapse of intussuscepted small bowel outside through the umbilical defect.

CASE REPORT

An 18 months old male baby presented in pediatric surgery OPD with history of fecal discharge from an opening at umbilicus since birth. He was advised contrast study through umbilical opening. Contrast study showed communication with small bowel (fig 1). The diagnosis of patent vitellointestinal duct was made. While patient was waiting for definitive surgery he developed pain abdomen, vomiting, and bowel loop coming out through umbilical defect. For these complains patients came in emergency.

Figure 1

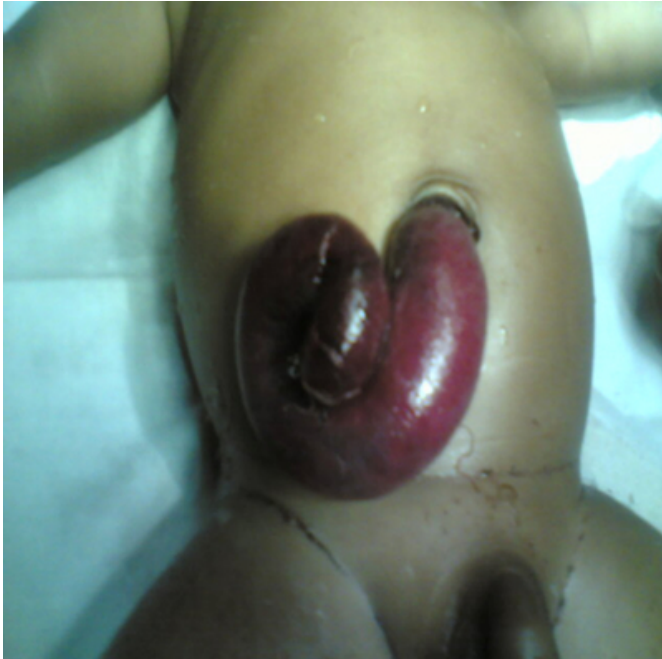Figure 1: Contrast study showing free passage of dye in ileum through the opening pointed



On examination abdomen was distended, prolapsed bowel loop was dusky red in color, tender and non reducible (fig. 2). Bowel sound was obstructive. Erect X-ray abdomen showed multiple air fluid levels.

Figure 2

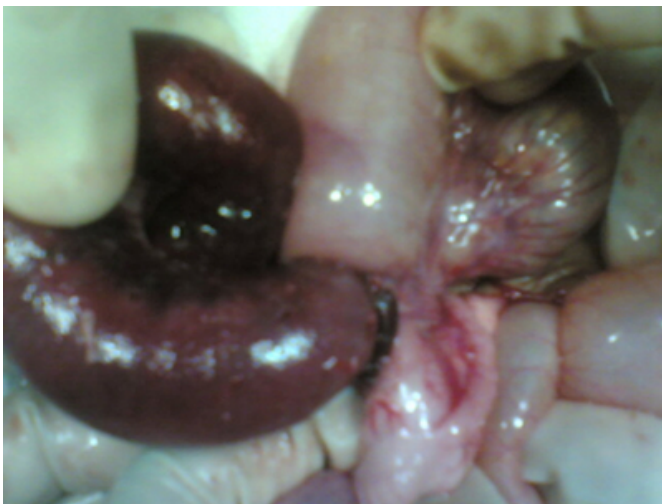Figure 2: Prolapsed bowel loop at the time of presentation



The baby was prepared for urgent laparotomy under general anesthesia. The abdomen was opened through below umbilicus midline incision. The prolapsed bowel loop was separated from the abdominal wall by fine dissection. The prolapsed bowel loop was intussuscepted distal ileal segment through patent vitellointestinal duct (fig 3). The intussusception was reduced slowly but whole of the distal ileal segment up to ileocaecal junction was found gangrenous.

Figure 3

Figure 3: Preoperative photograph showing gangrenous intussuscepted distal ileum



However no lead point was found. Whole gangrenous

segment was resected and ileotransverse end to end anastomosis was done. The baby was allowed orally from 5th day and discharged on seventh day.

DISCUSSION

Vitellointestinal or omphalomesenteric duct normally connects the primitive gut to the yolk sac usually obliterate around the seventh or eighth week of gestation. Failure to do this leads to several possible anomalies, including an omphalomesenteric fistula, an enterocyst, a fibrous band connecting the intestine to the umbilicus or a Meckel's diverticulum with or without a fibrous cord connecting to the umbilicus¹. Meckel's diverticulum has a 4 to 6 percent lifetime risk of developing a complication.² The largest study, by Yamaguchi and colleagues³, with 600 patients, 287 of whom were symptomatic, showed the following complication rates: obstruction, 36.5%; intussusception, which often presents as obstruction, 13.7%; inflammation or diverticulitis and perforation, 12.7% and 7.3%, respectively; hemorrhage, 11.8%; neoplasm, 3.2%; and fistula, 1.7%. Intussusceptions described above are inversion of meckel's diverticulum in to the ileum. This is most common type of intussusception involving vitellointestinal duct⁴.

Intussusception of small bowel in vitellointestinal duct is very rare entity to be reported in world literature. Only two cases had been reported previously one in 1985 by Gvalani⁴ and another by Mohite⁵ in 2007. In our case mouth of the duct was wider and the length of the duct was shorter. This finding was also present in previous cases⁶. The distance between vitellointestinal duct and ileocaecal valve is lesser in infants leading to higher intraluminal pressure⁷. Now, we can hypothesize that wider mouth and shorter duct may facilitate the intussusception in the presence of increased intraluminal pressure.

Early diagnosis and reduction is ideal treatment. In our case ileum was gangrenous leading to resection of the same.

CONCLUSION

Patent VID with prolapsed ileal loop is a rare condition needs prompt diagnosis and early treatment to save the intussuscepted segment's viability otherwise resection is inevitable.

References

1. Stone PA, Hofeldt MJ, Campbell JE, et al. Meckel diverticulum: ten-year experience in adults. *South Med J* 2004; 97: 1038-41.
2. Cullen JJ, Kelly KA, Moir CR, Hodge DO, Zinsmeister AR, Melton LJ 3d. Surgical management of Meckel's

diverticulum. An epidemiologic, population-based study.

Ann Surg 1994;220:564-9

3. Yamaguchi M, Takeuchi S, Awazu S. Meckel diverticulum. Investigation of 600 patients in the Japanese literature. Am J

Surg 1978; 136:247-9

4. Karadeniz Cakmak G, Emre AU, Tascilar O, Bektaş S, Ucan BH, Irkorucu O et al Lipoma within inverted Meckel's diverticulum as a cause of recurrent partial intestinal obstruction and hemorrhage: A case report and review of literature. World J Gastroenterol 2007; 13(7): 1141-1143

5. Gvalani AK, Acharya GV, Rao RV, Dawookkar VV: Ileal prolapse through a patent vitellointestinal. Indian Practitioner 1985, 38(7):629-32

6. Mohite P N, Bhatnagar A M, Hathila V P, Mistry J H, Patent vitellointestinal duct with prolapse of inverted loop of small intestine: a case report, Journal of Medical Case Reports 2007, 1:49doi:10.1186/1752-1947-1-49

7. Dumper J, Mackenzie S, Mitchell P, Sutherland F, Quan M L, Mew D et al Complications of Meckel's diverticula in adults Can J Surg, 2006; 49(5): 353-357

Author Information

Mohammad Iqbal Zea, MS

Senior Resident, Department of Surgery, Jawaharlal Nehru Medical College, Aligarh Muslim University, Aligarh, INDIA

Rajendra Singh Chana, M S M Ch (paediatric surgery)

Professor, Department of Surgery, Jawaharlal Nehru Medical College, Aligarh Muslim University, Aligarh, INDIA

Afzal Anees, M S, FAIS, FAIGES, FMAS

Lecturer, Department of Surgery, Jawaharlal Nehru Medical College, Aligarh Muslim University, Aligarh, INDIA

Sheeraz Mohd Khan

Junior Resident, Department of Surgery, Jawaharlal Nehru Medical College, Aligarh Muslim University, Aligarh, INDIA