

Adenomatoid Tumor Of Tunica Albuginea Mimicking A Testicular Neoplasm

S Garg, M Mathew, J Thomas, T Goel

Citation

S Garg, M Mathew, J Thomas, T Goel. *Adenomatoid Tumor Of Tunica Albuginea Mimicking A Testicular Neoplasm*. The Internet Journal of Urology. 2006 Volume 4 Number 2.

Abstract

Adenomatoid tumors arising from the tunica albuginea of the testis are rare lesions. We describe a case of a large adenomatoid tumor of the tunica albuginea measuring 4 cms. Because of its rarity, the clinical and histopathological aspects are discussed.

INTRODUCTION

Adenomatoid tumors are benign mesothelial tumors found in the paratesticular region, mainly arising from the epididymis. The average documented size is 2 cm¹. Here, we report a case of adenomatoid tumor originating in the tunica albuginea of the testis, measuring 4x3.5cms and mimicking an intratesticular neoplasm.

CLINICAL SUMMARY

A 40 year married male, presented with a dull ache and dragging sensation in the right hemiscrotum for last one year. It was associated with a gradual increase in the size of the right testis. The pain was not relieved with analgesics. A fine needle aspiration of the right testis done at another hospital and was reported as Seminoma. Thereafter, he was referred to our institute for further treatment.

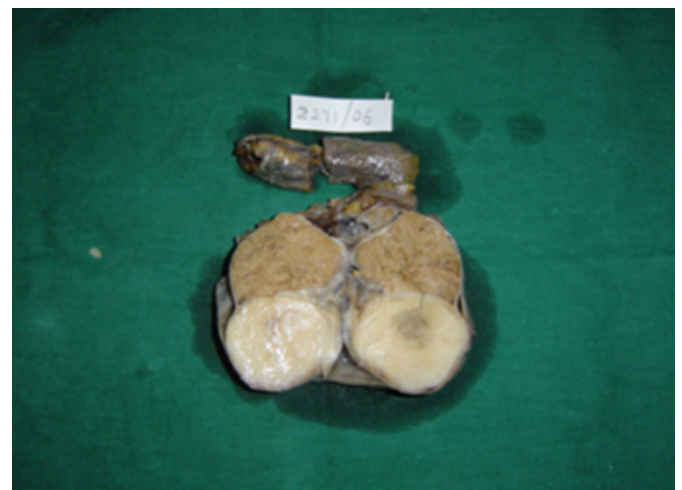On examination, the right testis was found to be slightly irregular at the lower pole. There was no palpable varicocele or hernial sac. The contralateral testis was normal. Investigations revealed normal serum α -FP, β -HCG, and LDH levels. A scrotal Doppler showed a hypoechoic lesion at the junction of the epididymis and the right testis. The patient underwent right radical orchidectomy as features were suggestive of a neoplastic process.

PATHOLOGICAL FINDINGS

Grossly, the orchidectomy specimen weighed 95gms and measured 5.5 x 3cms (Fig.1).

Figure 1

Figure 1: Gross photograph of tumor arising in the tunica albuginea.

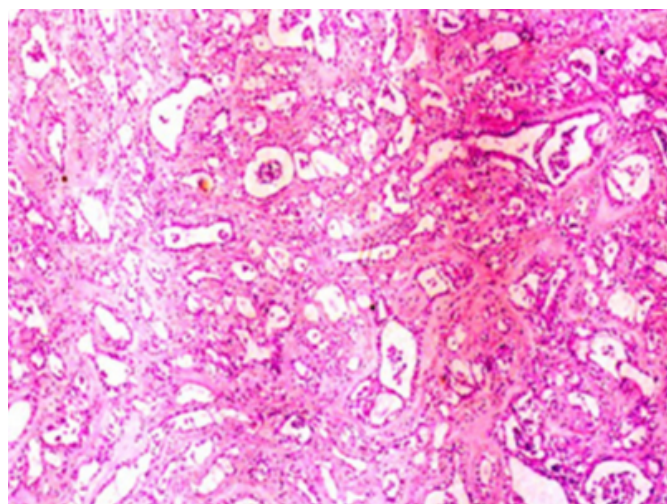


The capsule of the testis appeared to be adherent at the lower pole. Cut section showed a well circumscribed nonencapsulated, firm, homogenous grey white tumor measuring 4 x 3.5cms. Focal areas of hemorrhage were seen. Normal testicular parenchyma was seen above the tumor. The spermatic cord and the epididymis appeared uninvolved.

Microscopically, the sections showed a tumor arranged in cords and cystic tubules lined by cells with moderate eosinophilic, vacuolated cytoplasm and vesicular nuclei with small nucleoli. The intervening stroma was desmoplastic and had lymphoid aggregates (Fig 2).

Figure 2

Figure 2: Photomicrograph of Adenomatoid tumor showing cystic tubules and cords lined by malignant cells (H&E, x200).



No mitotic figures were seen. The testis, spermatic cord and epididymis were normal. The tumor cells were PAS with diastase and mucicarmine negative. On immunohistochemistry, the cells were cytokeratin positive, CD 34 negative and p53 negative.

DISCUSSION

Adenomatoid tumors account for approximately 30% of all paratesticular tumors¹, typically located in the epididymis^{2,3}. It has also been reported in other sites such as tunica albuginea⁴, spermatic cord, ejaculatory duct, ovary, adrenal gland, pancreas, pleura, and even the heart. It is also common in the fallopian tubes and the uterus⁶. It can be seen in all ages, but are most common in the third to fifth decades of life.

Adenomatoid tumors present as a relatively small, well-demarcated, and nonencapsulated nodule with a mean diameter of 2 cm, the largest reported diameter being 12 cm⁷. The cut surface is firm and solid with variable cystic spaces. Microscopically, the tumor is composed of two major elements, epithelial-like cells and fibrous stroma. The epithelial-like cells are arranged in a network of tubules, cords, channels, and microcystic spaces. The fibrous stroma may be hyalinised and may contain smooth muscle. Mitotic figures are mostly absent⁸. Special stains with PAS with diastase and mucicarmine are negative. Alcaine blue is positive but is hyaluronidase sensitive. The cells are cytokeratin 5/6, calretinin, EMA, and AE1-AE3 positive, indicating the mesothelial nature of the lesion.

The differential diagnosis includes metastatic carcinoma, malignant mesothelioma⁹, histiocytoid hemangioma¹⁰ and carcinoma of the rete testis. In metastatic carcinoma, cells are frankly malignant and show hyaluronidase resistant positivity in the cytoplasm. In carcinoma of rete testis, the cells are CEA positive and hyaluronidase resistant. The gross, microscopy and markers of malignant mesothelioma and histiocytoid hemangioma have been compared with adenomatoid tumor in Table 1.

Figure 3

Table 1: Comparison of Malignant mesothelioma and Histiocytoid hemangioma with Adenomatoid tumor

Table 1
Comparison of Malignant mesothelioma and Histiocytoid hemangioma with Adenomatoid tumor

	Adenomatoid tumor	Malignant Mesothelioma	Histiocytoid hemangioma ¹⁰
Gross Features	Tan-gray to white usually firm nodule	Solid or partly cystic with multiple, shaggy nodules and infiltrative margins	Reddish
Microscopic Features	Epithelial like cells are arranged in a network of tubules, cords, channels, and microcystic spaces without erythrocytes	Epithelial, sarcomatoid or biphasic. Cells have high mitotic rate and nuclear atypia. Psammoma bodies ⁺	Epithelioid cells arranged in nests, cords and small round to slit like channels that contain erythrocytes
Immunohistochemistry	<div> Cytokeratin CK5/6 EMA </div>	<div> Cytokeratin CK5/6 EMA </div>	<div> Factor VIII CD34 Ulex europaeus I lectin </div>
	Positive	Positive	Positive
	<div> CEA Factor VIII CD34 </div>	<div> CEA Factor VIII CD34 </div>	<div> Cytokeratin CK5/6 EMA </div>
	Negative	Negative	Negative
	P53 usually negative	P53 usually positive ⁹	

Adenomatoid tumors of the testicular tunica albuginea are rare. Although 99% of all testicular tumors are malignant, it must be emphasized that lesions such as the adenomatoid tumor do not require an aggressive surgical treatment; but an intraoperative frozen section followed by tumor resection. We report this case for its rarity of site of origin and large size. Thus, this benign tumor should also be borne in mind while dealing with a testicular lesion.

CORRESPONDENCE TO

Dr. Shveta Garg, Department of Pathology Kasturba Medical College, Manipal. 576104 Karnataka. India. Phone No.: +918202922328 Email: shvetatanmaya@gmail.com

References

- Samad AA, Pereiro B, Badiola A, Gallego C, Zungri E. Adenomatoid tumor of intratesticular localization. *Eur Urol* 1996; 30:127-128.
- Davis CJ, Sesterhenn IA, Woodward PJ. Tumors of paratesticular structures. In: Eble JN, Sauter G, Epstein JI, Sesterhenn IA eds. *Tumours of the Urinary System and Male Genital Organs*. Lyon: IARC Press; 2004:267-276.
- Pérez-Ordóñez B, Srigley JR. Mesothelial lesions of the paratesticular region. *Semin Diagn Pathol* 2000; 17:294-306.

4. Sidhu GS, Fresko O. Adenomatoid tumor of the epididymis: ultrastructural evidence of its biphasic nature. *Ultrastruct Pathol* 1980; 1:39-47.
5. Raaf HN, Grant LD, Santoscoy C, et al. Adenomatoid tumor of the adrenal gland: a report of four new cases and a review of the literature. *Mod Pathol* 1996; 9:1046-1051.
6. Srigley JR, Colgan TJ. Multifocal and diffuse adenomatoid tumor involving uterus and fallopian tube. *Ultrastruct Pathol* 1988; 12:351-355.
7. Klerk DP, Nime F. Adenomatoid tumors (mesothelioma) of testicular and paratesticular tissue. *Urology* 1975;6:635.
8. Manson AL. Adenomatoid tumor of testicular tunica albuginea mimicking testicular carcinoma. *J Urol* 1988; 139:819-20.
9. Delahunt B, Eble JN, King D, Bethwaite PB, Nacey JN, Thornton A. Immunohistochemical evidence for mesothelial origin of paratesticular adenomatoid tumour. *Histopathology* 2000 Feb; 36(2):109-15.
10. Fermina M, Mazzella, Steven C, Sieber, Victor Lopez. Histiocytoid Hemangioma of the testis. *J Urol* 1995; 153:743-44.

Author Information

Shveta Garg

Department of Pathology, Kasturba Medical College

Mary Mathew

Department of Pathology, Kasturba Medical College

Joseph Thomas

Department of Urology, Kasturba Medical College

Tanmaya Goel

Department of Urology, Kasturba Medical College