

# Spinal Osteomyelitis Due To Mycobacterium Avium-Intracellulare: MR Findings

T Higuchi, N Takahashi, H Yoshikawa, S Ishikawa, N Imai, M Shiotani, H Maeda, Y Takada

---

## Citation

T Higuchi, N Takahashi, H Yoshikawa, S Ishikawa, N Imai, M Shiotani, H Maeda, Y Takada. *Spinal Osteomyelitis Due To Mycobacterium Avium-Intracellulare: MR Findings*. The Internet Journal of Radiology. 2005 Volume 5 Number 1.

## Abstract

*Mycobacterium avium-intracellulare* (MAI) is one of the atypical mycobacteria, and MAI infection is well described in immunocompromized patients. While MAI may cause lung disease in non-HIV infected individuals, spinal osteomyelitis due to MAI in immunocompetent patients is extremely rare. In this report, we describe a case of spinal osteomyelitis due to MAI in an immunocompetent patient. MR findings of the spinal lesion were similar to those of tuberculous spinal osteomyelitis, rather than pyogenic disease.

## CASE REPORT

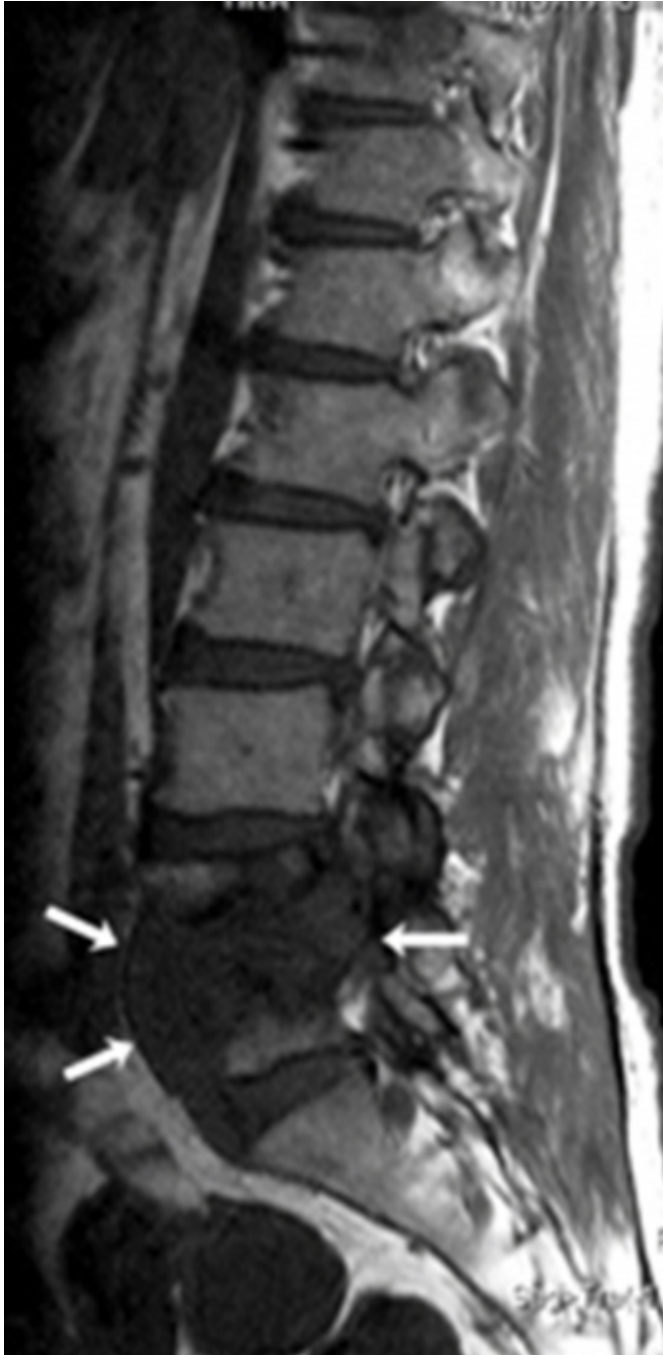A 65-year-old man was admitted to hospital because of lumbago and intermittent claudication. He had undergone laminectomy of the fifth lumbar vertebra due to spinal stenosis five years before the present admission. On admission, the general condition was good and chest radiograph did not demonstrate any abnormalities. Laboratory test findings were unremarkable. Human immunodeficiency virus (HIV) test was negative. He had no history of diabetes and was not receiving steroid therapy.

MR study was performed under a diagnosis of spinal

disorder. Sagittal T1-weighted MR imaging showed hypointense lesion from L4 to L5, extending to the paravertebral region (Fig. 1A). Sagittal T2-weighted MR imaging showed very hyperintense areas in the extended region and in the L4-5 intervertebral disc (Fig. 1B). Rim-like enhancement was demonstrated in the lesion after gadolinium administration (Fig. 1C, D). Those findings appeared to show discitis and vertebral osteomyelitis with intraosseous extension to paravertebral abscess. Infectious vertebral osteomyelitis, especially due to tuberculosis (TB) was interpreted from these MR findings.

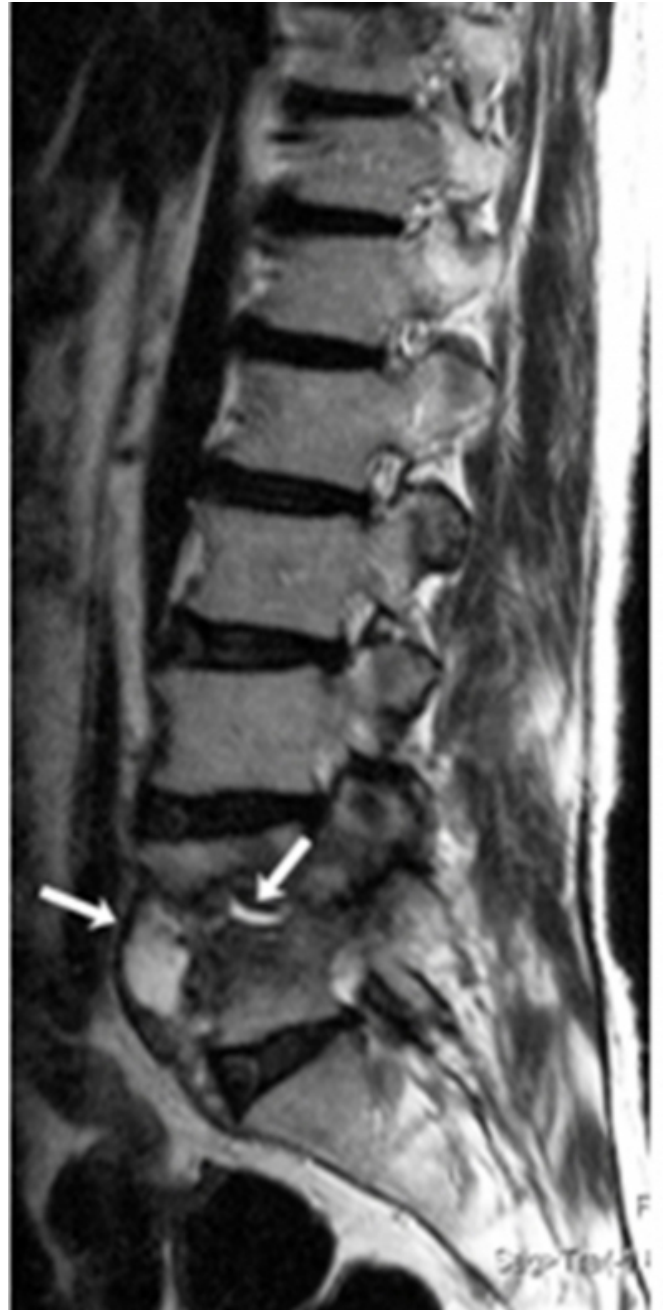**Figure 1**

Figure 1a: 65-year-old man with vertebral osteomyelitis due to *Mycobacterium avium-intracellulare*. Sagittal T1-weighted image shows hypointense lesion from L4 to L5, extending to the prevertebral region ().



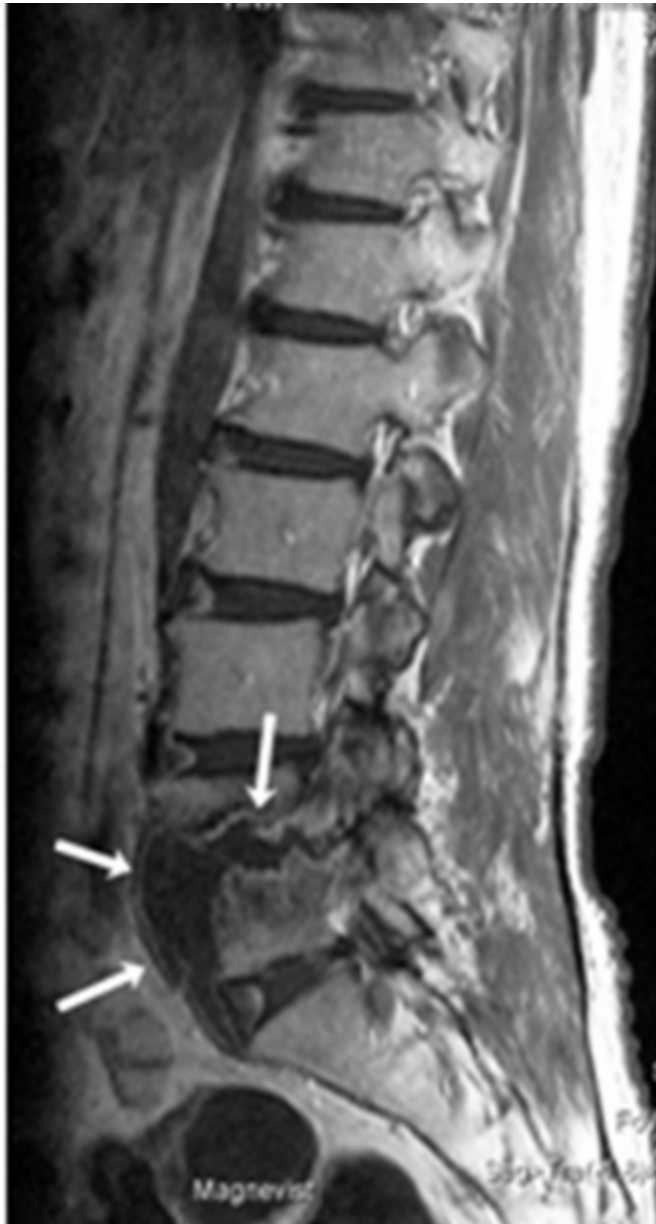**Figure 2**

Figure 1b: 65-year-old man with vertebral osteomyelitis due to *Mycobacterium avium-intracellulare*. Sagittal T2-weighted image obtained at the same level as shows very hyperintense areas in the extended region and in the L4-5 intervertebral disc. ().



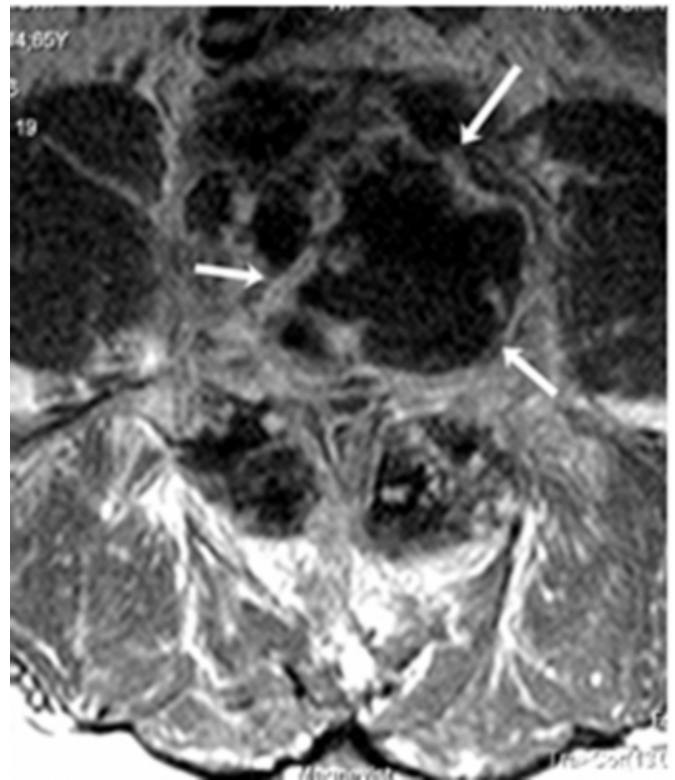
**Figure 3**

Figure 1c: 65-year-old man with vertebral osteomyelitis due to Mycobacterium avium-intracellulare. Sagittal T1-weighted image obtained after gadolinium injection at the same level as shows Rim-like enhancement in the lesion ().



**Figure 4**

Figure 1d: 65-year-old man with vertebral osteomyelitis due to Mycobacterium avium-intracellulare. Axial T1-weighted image obtained after gadolinium injection at the level of L4-5 shows Rim-like enhancement ().



Open drainage and surgical debridement of spinal lesions was performed under the initial diagnosis, vertebral osteomyelitis due to TB. After four weeks, cultures of samples from the necrotic tissue grew mycobacterium avium. None of the cultures grew TB. The antimicrobial regimen was changed from TB, to that for MAI. Treatment for MAI, Clarithromycin (800mg/day), rifampin (450mg/day), ethambutol (750mg/day) was started the day after we received the culture reports. Postoperative recovery was good, and the patient's complaints were improved.

## DISCUSSION

In non-immunocompromised individuals spinal osteomyelitis due to MAI is extremely rare. Non-AIDS patients with MAI infections tend to be elderly, have underlying pulmonary disease, and have been taking steroids on a long-term basis. Rarely, such patients may subsequently develop vertebral osteomyelitis [1].

Trauma, surgical procedure, old age, preexisting pulmonary disease, bone marrow transplant, and osteoporosis are risk factors for skeletal infection from MAI complex, as are HIV infection, chronic steroid therapy, and other

immunocompromised conditions [2]. The past surgical history, laminectomy of the fifth lumbar vertebra, in the present case may have been involved the spinal MAI infection.

Spinal involvement of non-tuberculous mycobacteria has mainly been described in case reports, and few reports have described the Magnetic Resonance appearance of vertebral osteomyelitis due to non-tuberculous mycobacteria precisely, even though MR imaging seems to provide the most useful information for diagnosis of spinal infection. MR findings of MAI seem to be similar to findings of tuberculous spinal infection [1, 3, 4, 5]. These findings accord with the present case. However, numerous atypical mycobacteria are known to cause musculoskeletal system infection in humans [6]. MR findings of spinal osteomyelitis due to atypical mycobacteria other than MAI do not always appear similar to those of tuberculosis, therefore at this time, MR findings of the atypical mycobacteria should not be discussed as a single subject.

Because the antimicrobial regimens of MAI vertebral

osteomyelitis are not same as these of tuberculosis, MAI infection must be considered in any patients showing MR findings mimicking tuberculous spinal osteomyelitis, even if the patient is not immunocompromized.

### References

1. Weiner BK, Love TW, Fraser RD. *Mycobacterium avium* intracellulare: vertebral osteomyelitis. *J Spinal Disord* 1998 Feb;11(1):89-91.
2. Mehta JB, Emery MW, Girish M, Byrd RP Jr, Roy TM. Atypical Pott's disease: localized infection of the thoracic spine due to *Mycobacterium avium-intracellulare* in a patient without human immunodeficiency virus infection. *South Med J* 2003 Jul;96(7):685-8.
3. Igram CM, Petrie SG, Harris MB. Atypical mycobacterial vertebral osteomyelitis in an immunocompetent patient. *Orthopedics* 1997 Feb;20(2):163-6.
4. Chan ED, Kong PM, Fennelly K, Dwyer AP, Iseman MD. Vertebral osteomyelitis due to infection with nontuberculous *Mycobacterium* species after blunt trauma to the back: 3 examples of the principle of locus minoris resistentiae. *Clin Infect Dis* 2001 May 15;32(10):1506-10. Epub 2001 Apr 17.
5. Niazi S, Batra V, Zangrilli JG. Atypical mycobacterial osteomyelitis in a non-AIDS patient. *Conn Med* 2002 Jul;66(7):387-9.
6. Theodorou DJ, Theodorou SJ, Kakitsubata Y, Sartoris DJ, Resnick D. Imaging characteristics and epidemiologic features of atypical mycobacterial infections involving the musculoskeletal system. *AJR* 2001 Feb;176(2):341-9.

**Author Information**

**Takeshi Higuchi, M.D.**

Department of Radiology, Niigata City General Hospital

**Naoya Takahashi, M.D.**

Department of Radiology, Niigata City General Hospital

**Hiroko Yoshikawa, M.D.**

Department of Infectious Diseases, Niigata City General Hospital

**Seiichi Ishikawa, M.D.**

Department of Orthopedic Surgery, Niigata City General Hospital

**Norio Imai, M.D.**

Department of Orthopedic Surgery, Niigata City General Hospital

**Motoi Shiotani, M.D.**

Department of Radiology, Niigata City General Hospital

**Haruo Maeda, M.D.**

Department of Radiology, Niigata City General Hospital

**Yoshihiro Takada, M.D.**

Department of Radiology, Niigata City General Hospital